



THE AGA KHAN UNIVERSITY

eCommons@AKU

---

Section of Neurosurgery

Department of Surgery

---

September 2018

# Role of palliative CSF diversion in patients with intracranial metastatic disease and symptomatic hydrocephalus

Farhan A. Mirza  
*University of Kentucky, UK.*

Muhammad Shahzad Shamim  
*Aga Khan University, shahzad.shamim@aku.edu*

Follow this and additional works at: [https://ecommons.aku.edu/pakistan\\_fhs\\_mc\\_surg\\_neurosurg](https://ecommons.aku.edu/pakistan_fhs_mc_surg_neurosurg)

---

## Recommended Citation

Mirza, F. A., Shamim, M. (2018). Role of palliative CSF diversion in patients with intracranial metastatic disease and symptomatic hydrocephalus. *Journal of Pakistan Medical Association*, 68(9), 1412-1414.

**Available at:** [https://ecommons.aku.edu/pakistan\\_fhs\\_mc\\_surg\\_neurosurg/158](https://ecommons.aku.edu/pakistan_fhs_mc_surg_neurosurg/158)

## Role of palliative CSF diversion in patients with intracranial metastatic disease and symptomatic hydrocephalus

Farhan A. Mirza,<sup>1</sup> Muhammad Shahzad Shamim<sup>2</sup>

### Abstract

Hydrocephalus, unless treated, is one of the terminal manifestations of intracranial metastatic disease. Single lesions causing obstructive hydrocephalus are amenable to surgical resection, but in the setting of multiple lesions and communicating hydrocephalus from leptomeningeal disease, the approach to treatment is much less defined. The use of endoscopic third ventriculostomy (ETV) and ventriculoperitoneal shunting (VPS) has been described, but data is limited. In this review, we summarize the sparse data available in literature describing the use of CSF diversion for patients with metastatic disease presenting with hydrocephalus and neurological decline.

**Keywords:** Metastatic tumours, hydrocephalus, endoscopic third ventriculostomy, ventriculoperitoneal shunt, CSF diversion

### Background

Treatment of cancers in the form of surgery, chemotherapy, and radiation therapy in general has been improving, resulting in improved survival of these patients. With longer survival, tumour recurrence and metastasis are being seen more often. It is estimated that 25-30% of cancer patients develop brain metastases. In intracranial metastatic disease, especially in the presence of multiple lesions or leptomeningeal spread, the prognosis is usually considered poor on the scale of few weeks to months.<sup>1</sup> In certain situations however, if there is a single lesion or a posterior fossa periventricular lesions resulting in obstructive hydrocephalus, primary surgical resection can be of benefit in relieving this obstruction and provide survival benefit.<sup>1</sup>

The role of palliative CSF diversionary procedures for this situation is less well defined. Limited data exists in literature describing the use of ventriculoperitoneal shunt or endoscopic third ventriculostomy as a CSF diversion

method for obstructive hydrocephalus.<sup>2-5</sup> Reports are also present on communicating hydrocephalus in the setting of leptomeningeal disease and high grade gliomas.<sup>4-7</sup> Lumboperitoneal shunting has also been described.<sup>8</sup>

### Review of Evidence

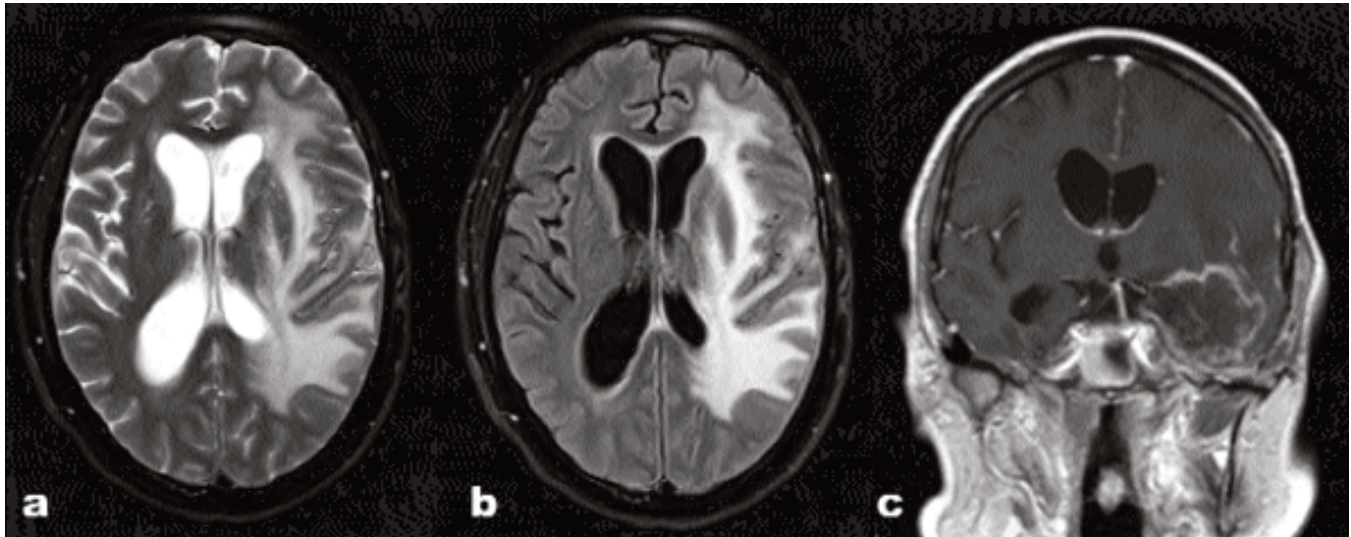
#### Ventriculoperitoneal Shunt (VPS)

In 2015, Nigim et al., published their series of 59 patients who underwent VPS placement for hydrocephalus in the background of brain tumours.<sup>4</sup> Forty patients with metastatic lesions and 19 with primary brain neoplasms were included. Nineteen patients had obstructive and 40 patients had communicating hydrocephalus. Eighty-three percent of patients in Nigim's series had progressive systemic disease. Ninety-three percent patients showed improvement in their symptoms and shunt related complications were noted in 11.9%. The authors did not comment on outcomes with respect to the type of hydrocephalus (obstructive vs. communicating), thus it is difficult to generalize their results to either scenario. Overall good outcomes with good shunt patency were noted at six months and one year.<sup>4</sup>

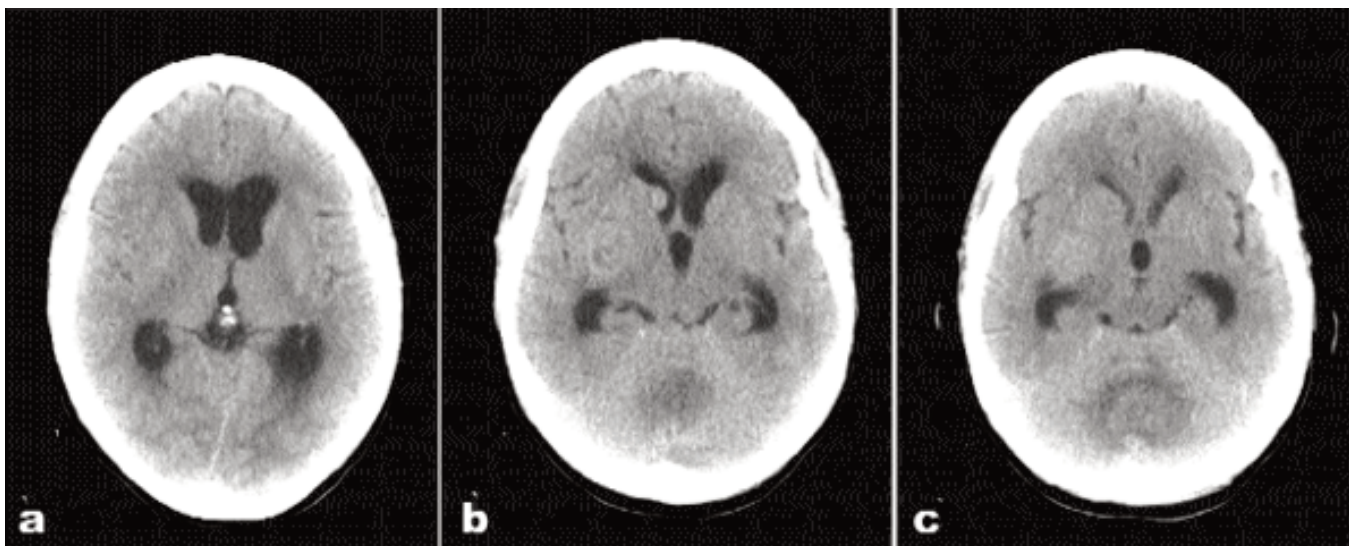
Prior to this series, Lee et al., described their experience with 50 patients in 2011.<sup>5</sup> Ten of these had parenchymal lesions and the rest presented with leptomeningeal disease with or without parenchymal lesions. Thirteen patients had obstructive and 37 had communicating hydrocephalus. Overall 80% patients noted improvement in headache, nausea, and cognitive status and 10% complication rate was noted, including one death from intracerebral haemorrhage. One of the interesting findings reported was the presence of opening pressure of >30 cm H<sub>2</sub>O as an independent risk factor for poorer outcomes. It was also reported that patients who underwent VPS followed by therapy for their systemic disease had better outcomes. This however was attributed to patient selection. It is also interesting to note that six patients in their series with primarily leptomeningeal spread had a survival period of over one year after VPS placement. Their data supports the utilization of CSF diversion even in cases of leptomeningeal disease which is usually considered as an end stage manifestation.

.....  
<sup>1</sup>Department of Neurosurgery, University of Kentucky, UK, <sup>2</sup>Department of Surgery, Section of Neurosurgery, Aga Khan University Hospital, Karachi, Pakistan.

**Correspondence:** Muhammad Shahzad Shamim.  
Email: shahzad.shamim@aku.edu



**Figure-1 (a,b,c):** MRI Brain T2 axial, Flair axial and T1 coronal with contrast images showing GBM with hydrocephalus.



**Figure-2 (a,b,c):** CT Brain axial plain showing multiple metastases from a primary lung cancer, and obstructive hydrocephalus due to obstruction of fourth ventricle.

### Endoscopic Third Ventriculostomy (ETV)

Third ventriculostomy serves as a physiologic shunt can be performed endoscopically using anatomic landmarks, or with stereotaxis using image guidance. ETV mitigates the complications that may accompany shunt placement such as hardware malfunction, wound breakdown over shunt hardware, over-drainage, and possible seeding of the peritoneal cavity. It also avoids the discomfort caused by subcutaneous tunneling of the shunt. However, it may not be applicable for all patients with hydrocephalus and the ETV Success Score may be used to predict which

patients are more likely to benefit from it, and which are best treated with a VPS.<sup>9</sup>

Only two reports are present in literature regarding the use of ETV for hydrocephalus in metastatic disease. Nguyen et al., in 1999 presented their case series of seven patients with metastatic lesions to the thalamus or posterior fossa resulting in CSF obstruction.<sup>2</sup> Five of these cases showed improvement after ETV. One patient proceeded to comfort care after no improvement. One patient had post-operative improvement but returned in a few days with worsening hydrocephalus, and required

VPS with resolution of symptoms.

To further this, Chen et al., published their results of 16 patients in 2011.<sup>3</sup> All patients in their series had failed chemotherapy, had active primary disease, and had low KPS scores. All patients had imaging findings consistent with obstructive hydrocephalus from metastatic lesions. Symptomatic improvement was observed after palliative ETV in 11 patients (69%). Four (25%) were deceased by the end of the first month. This improvement is comparable with that reported for the use of VP shunts.

Although the data on this topic is insufficient to draw conclusions, CSF diversion appears as a reasonable choice for certain patient subgroups with symptomatic hydrocephalus and intracranial metastatic disease. One cannot overemphasize the use of Karnofsky Performance Scale (KPS) when approaching patients as it appears to have direct impact on survival. Younger age, better neurocognitive status, more limited extent of systemic disease and responsiveness to treatment should also be factored into the equation. In choosing surgical modality, results from the ETV and VPS series are comparable, with a lower rate of complications with ETV. It would be reasonable to use ETV as the first line treatment, specifically in obstructive hydrocephalus cases, with predictive success scores in the realm of 70-90% as predicted by the ETV Success Score.

## Conclusion

Surgical CSF diversion for hydrocephalus in intracranial

metastatic disease is a viable option in symptomatic patients. It has been shown to improve symptoms and although the existing data is sparse, it does also support improved survival in select cases.

## References

1. Laghari AA, Ahmed SI, Shamim MS. Role of surgery in brain metastases. *J Pak Med Assoc* 2017; 67: 1299-300.
2. Nguyen TT, Smith MV, Rodziewicz GS, Lemke SM. Hydrocephalus caused by metastatic brain lesions: treatment by third ventriculostomy. *J Neurol Neurosurg Psychiatry*.1999; 67: 552-3.
3. Chen CC, Kasper E, Warnke P. Palliative stereotactic-endoscopic third ventriculostomy for the treatment of obstructive hydrocephalus from cerebral metastasis. *Surg Neurol Int*. 2011; 2: 76. doi: 10.4103/2152-7806.82083.
4. Nigim F, Critchlow JF, Kasper EM. Role of ventriculoperitoneal shunting in patients with neoplasms of the central nervous system: An analysis of 59 cases. *Mol Clin Oncol*. 2015; 3: 1381-6.
5. Lee SH, Kong DS, Seol HJ, Nam DH, Lee JI. Ventriculoperitoneal shunt for hydrocephalus caused by central nervous system metastasis. *J Neurooncol*. 2011; 104: 545-51.
6. Omuro AM, Lallana EC, Bilsky MH and DeAngelis LM: Ventriculoperitoneal shunt in patients with leptomeningeal metastasis. *Neurology* 2005; 64: 1625-7.
7. Inamasu J, Nakamura Y, Saito R, Kuroshima Y, Mayanagi K, Orii M, Ichikizaki K. Postoperative communicating hydrocephalus in patients with supratentorial malignant glioma. *Clin Neurol Neurosurg*. 2003; 106: 9-15.
8. Yamashiro S, Hitoshi Y, Tajiri S, Uchikawa H, Ito K, Yoshida A, Kuratsu JI. Palliative lumboperitoneal shunt for leptomeningeal metastasis-related hydrocephalus: A case series. *Palliat Med*. 2017; 31: 93-6.
9. Labidi M, Lavoie P, Lapointe G, Obaid S, Weil AG, Bojanowski MW, et al. Predicting success of endoscopic third ventriculostomy: validation of the ETV Success Score in a mixed population of adult and pediatric patients. *J Neurosurg*. 2015; 123: 1447-55.