



THE AGA KHAN UNIVERSITY

eCommons@AKU

Department of Biological & Biomedical Sciences

Medical College, Pakistan

January 2003

Renal cortical necrosis: A case series of nine patients & review of literature

Syed Sohail Ali
Aga Khan University

Syed Zulfiqar Rizvi
Aga Khan University

Suhail Muzaffar
Aga Khan University

Aasim Ahmad
Aga Khan University

Akhtar Ali
Lady Reading Hospital, Peshawar

See next page for additional authors

Follow this and additional works at: https://ecommons.aku.edu/pakistan_fhs_mc_bbs

 Part of the [Biochemistry Commons](#), and the [Pathology Commons](#)

Recommended Citation

Ali, S. S., Rizvi, S. Z., Muzaffar, S., Ahmad, A., Ali, A., Hassan, S. H. (2003). Renal cortical necrosis: A case series of nine patients & review of literature. *Journal of Ayub Medical College, 15*(2), 41-44.

Available at: https://ecommons.aku.edu/pakistan_fhs_mc_bbs/627

Authors

Syed Sohail Ali, Syed Zulfiqar Rizvi, Suhail Muzaffar, Aasim Ahmad, Akhtar Ali, and Sheema H. Hassan

RENAL CORTICAL NECROSIS: A CASE SERIES OF NINE PATIENTS & REVIEW OF LITERATURE

Syed Sohail Ali, Syed Zulfiqar Hyder Rizvi*, Suhail Muzaffar**, Aasim Ahmad***, Akhtar Ali[†], Sheema H. Hassan**

Departments of Biological and Biomedical Sciences, Pathology**, Medicine*** and Final Year Medical Student*, The Aga Khan University Hospital, Karachi, and [†]Lady Reading Hospital, Peshawar.

Background: The purpose of this study is to review cases of renal cortical necrosis (RCN) which we came across during a period of five years, confirmed on needle biopsy specimens, with literature available so far. **Methods:** All renal biopsy records between January 1996 to December 2001 at the Aga Khan University Hospital, Karachi, Pakistan were reviewed to identify patients with histologically proven renal cortical necrosis. Seven patients were also referred by the department of Nephrology, Lady Reading Hospital, Peshawar, Pakistan. Patients' medical records were reviewed for demographic, clinical, and follow up data. **Results:** There were total of nine patients identified with renal cortical necrosis. The mean age was 26.21 ± 13.01 year. Five cases (55.5%) were caused by obstetric complications. The most common histology type of RCN was patchy cortical necrosis in seven patients (77.8%). Three patients were alive at last follow up; remaining patients were lost to follow up. **Conclusion:** Obstetric complications remain the leading cause of renal cortical necrosis in our setting. The recognition of this entity and value of renal biopsy in cases of acute renal failure needs to be emphasized as this helps in establishing diagnosis, to assess prognosis and to aid in selection of a rational approach to therapy.

KEY WORDS: Renal cortical necrosis, renal biopsy, acute renal failure.

INTRODUCTION

Renal Cortical Necrosis (RCN) is usually unheard of in developed countries but still occurs in developing countries owing to poor health facilities. Acute bilateral necrosis is an uncommon disease at the extreme end of the spectrum¹ which is especially encountered in obstetric patients^{2,3}. Over the years owing to the improved and readily available health facilities this entity is rarely seen especially in developed countries⁴. In contrast to western countries RCN is still high in developing countries⁴. Obstetric complications are the commonest cause of RCN^{2,3}. These precipitating events act as trigger mechanisms that interact with the various physiologic parameters of vascular and coagulation components, thereby generating a cascade that eventuates into catastrophic renal parenchymal damage^{5,6}. There is global necrosis of all the elements in the involved area of the cortex, including blood vessels, glomeruli and tubules⁴. The damage is permanent and functional loss is irreversible. For definitive diagnosis a renal biopsy is essential.

The frequency of renal cortical necrosis has been reported variably in published literature ranging from 1.9% to 2% in western countries⁷. In one study from India, RCN was found to be in more than 7% of patients with acute renal failure⁸. In autopsy cases, the incidence of RCN was found to be 0.2% in a study of 11,800 autopsies⁹. In another autopsy study performed on infants and children, the RCN was reported as 0.5%¹⁰.

The existence of this complication tells the true story of a collapsed health care system. The purpose of this study is to review cases of RCN, which we came across during a period of five years, confirmed on needle biopsy specimens, with literature available so far.

MATERIAL AND METHODS

All renal biopsy records between January 1996 to December 2001 at the Aga Khan University Hospital, Karachi, Pakistan were reviewed. Patients were identified who had renal cortical necrosis on renal biopsy specimens. Seven patients were referred from the department of Nephrology, Lady Reading Hospital, Peshawar, Pakistan. These patients constituted our study group and medical charts of these patients were reviewed for demographic data, clinical presentation, laboratory tests, and renal biopsy. Final outcome was recorded if available.

The renal biopsy specimens were routinely processed and stained with Haematoxylin and Eosin stains. Depending on the extent of the lesions, RCN was graded according to the schema of Sheehan and Moore¹¹ and Tisher¹² into five pathologic forms as: Focal, minor, patchy, gross and confluent focal. The focal form was characterized by minor areas of necrosis, which may vary from involvement of individual glomeruli to small foci of necrosis not greater than 0.5mm in diameter. Minor lesions were larger and measure up to 2 or 3 mm in diameter. All elements were necrotic in the involved areas including afferent arterioles and interlobular arteries. Necrosis of

proximal convoluted tubules with sparing of distal convoluted tubules characterized patchy form. In the gross form of the disease, the entire cortex including the columns of Bertini was yellow and necrotic. Widespread glomerular and tubular lesions ranging from congestion and thrombosis of capillaries or necrosis characterized confluent focal form.

RESULTS

We identified total of nine cases of RCN on renal biopsy specimen during study period of January 1997 to December 2001. The medical records of these patients were reviewed. Of these nine patients, two were male and seven were female patients. The mean age of patients at which they were diagnosed with RCN was 26.21 ± 13.01 year (range 2-40 year). The demographic and clinical data is summarized in Table-1.

Five cases (55.5%) of RCN were attributable to the obstetric problems including post-partum haemorrhage and intrauterine foetal deaths. The most common histology type of RCN was patchy in seven patients (77.8%). Two patients had minor form, of which one was also associated with membranous glomerulopathy. Follow up data was only available for three patients (Table-1). Figure-1 shows patchy form of RCN from case No. 2.

DISCUSSION

Due to poor health facilities, RCN is still a cause of morbidity and mortality in developing countries⁴. The damage is permanent and functional loss is irreversible. During five year of study period, we found only nine cases. This finding was consistent with other studies in published literature with frequency ranging from 1.9% to 2%⁷. A similar study from India reported RCN frequency of 7% in patients with acute renal failure⁸. However, the frequency of RCN was found to be 0.2% to 0.5% in autopsy studies^{9,10}.

RCN did not afflict any particular age group. The age range in our study came out to be 2-40 years with mean of 26.2 year. Similar findings were observed in reports from India^{4,13}. This also means that a vast majority of causes can lead to RCN manifesting as acute renal failure.

The most common underlying cause of RCN was found to be due to obstetric complications, which accounted 55.5% of our cases. Obstetric complications are the commonest (50-70%) cause of RCN^{2,3}. Causes of RCN can be divided into two groups: Obstetric and non-obstetric. Obstetric complications are mostly responsible^{2,3} and include abruptio placentae, septic abortion, eclamptic toxemia, post-partum haemorrhage, intrauterine foetal demise, amniotic fluid embolism and puerperal sepsis^{1,14}. Non-obstetric conditions leading to acute cortical necrosis are:

extensive burns, pancreatitis, septicaemia, snake bites¹⁵, diabetic ketoacidosis^{5,16}, Haemolytic Uremic Syndrome (HUS)¹⁷, multiple fractures and haemorrhage¹⁸, gastroenteritis, Streptococcus pharyngitis¹⁹, dehydration in infancy or childhood^{20,21}, organophosphorus poisoning²² and intra-abdominal procedures^{13,23}. Of all causes abruptio placentae is the most common obstetric cause, responsible for 50-60% of all cases of this disease^{25,11,25} followed by overwhelming infections with septic shock which comprises 30-40%^{5,6,25}.

In our series various patterns of RCN were observed. The most common form was patchy cortical necrosis observed in seven cases. In two cases the lesions were minor in form. Five cases were attributable to the obstetric factors including intrauterine foetal deaths and postpartum haemorrhage. In the young child (Case No. 1), dehydration secondary to severe gastroenteritis was the cause of renal cortical necrosis, which remains the most common cause of this lesion in children^{20,21}. In three cases no obvious underlying cause of cortical necrosis could be discernable. These could be attributable to the various infections, which comprised the second commonest cause of RCN^{5,6,24}. In one case (Case No. 9) apart from minor form of cortical necrosis, the patient was also having membranous glomerulopathy.

Ultrasound findings revealed bilateral enlargement of kidneys in all nine patients in our series. Although, ultrasound is usually employed as the first step in diagnosing renal problems, findings are not specific. In recent literature magnetic resonance imaging²⁵ and computed tomography²⁶ have been reported as diagnostic tools but yield occurs latter in the illness with approximate latency of ten days. They may be useful in latter evaluation; however, renal biopsy remains the mainstay of diagnosis.

The follow up data was available only for three patients. Majority of our patients were lost to follow up and, therefore, it is difficult to comment on mortality associated with this disease. However, various causes of mortality are severe uraemia, pulmonary oedema, hyperkalemia, gastrointestinal haemorrhage and septicemia⁴. Prognosis and survival of patients with cortical necrosis has improved markedly in developed countries due to availability of haemodialysis and renal transplant therapy.

The recognition of this entity and value of renal biopsy in cases of acute renal failure needs to be emphasized as this helps in establishing diagnosis, to assess prognosis and to aid in selection of a rational approach to therapy. Many of the causes of RCN could be avoided by providing good health facilities, the failure of which ultimately lead to the tremendous cost as these patients need constant haemodialysis/renal transplantation.

Figure-1: Photomicrograph showing focus of renal cortical necrosis. Prominent tubular atrophy and fibrosis is also appreciable. H & E stain (×200)

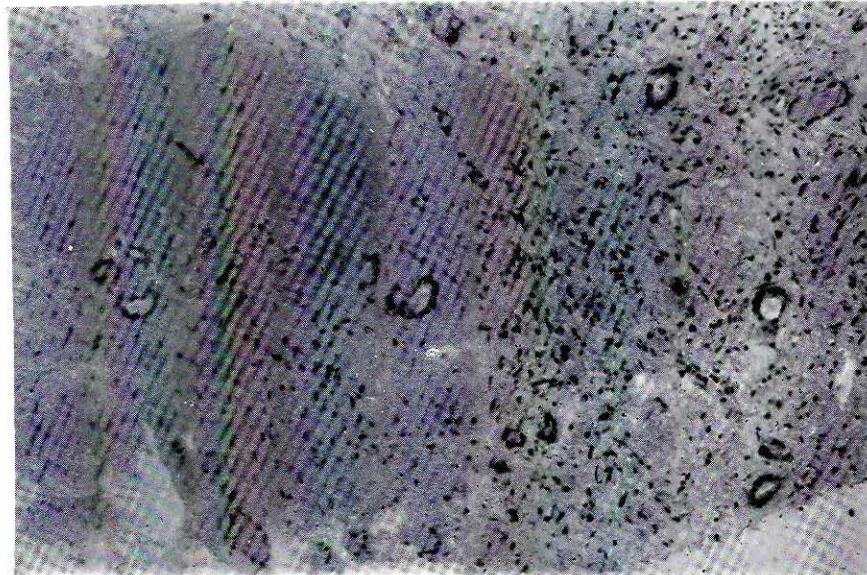


Table-1: Demographic and clinical characteristics of nine cases with RCN.

Case No.	Age (Year)	Sex	Underlying cause	Hb (g/dL)	BUN/Cr (mg/dL)	Ultrasound finding	Histology type	Follow up
1	2	M	Gastroenteritis	12.9	56/3.1	BEK**	Patchy	Alive
2	32	F	Still birth	9.8	220/7.5	BEK	Patchy	Unknown
3	12	F	Unknown	10.2	200/6.7	BEK	Patchy	Unknown
4	18	F	Still birth and Post-partum haemorrhage	11.4	80/2.3	BEK	Minor	Alive
5	32	F	Post-partum haemorrhage	7.0	220/9.4	BEK	Patchy	Unknown
6	25	F	Post-partum haemorrhage	10.0	70/3.1	BEK	Patchy	Unknown
7	39	F	Post-partum haemorrhage	11.2	64/2.9	BEK	Patchy	Alive
8	40	F	Unknown	9.8	86/3.3	BEK	Patchy	Unknown
9	35	M	Unknown	13.4	56/2.6	BEK	Minor*	Unknown

Hb = hemoglobin; BUN = blood urea nitrogen; Cr = Serum creatinine, *associated with membranous glomerulopathy
 ** bilateral enlarged kidneys.

REFERENCES

- Prakash J, Tripathi K, Pandey LK, Gadela SR. Renal cortical necrosis in pregnancy-related acute renal failure. J Indian Med Assoc 1996;94:227-9.
- Matlin RA, Gay NF. Acute cortical necrosis: Case report and review of literature. Am J Med 1974;56:110-8.
- Kleinknecht D, Grunfeld JP, Cia Gomez P, Moreau JF, Garcia-Torres R. Diagnostic procedures and long term progress in bilateral cortical necrosis. Kidney Int 1973;4:390.
- Prakash J, Tripathi K, Pandey LK, Sahai S, Usha, Srivastava. Spectrum of renal cortical necrosis in acute renal failure in Eastern India. Postgrad Med J 1995;71:208-10.
- Lauler DP, Schreiner GE. Bilateral renal cortical necrosis. Am J Med 1958;24:519.
- Deutsch V, Frankl O, Drony Y, Eliahou, Brafi ZF. Bilateral renal cortical necrosis with survival through the acute phase with a note on the value of selective nephroangiography. Am J Med 1971;50:828-34.
- Schreiner GE. Bilateral cortical necrosis. In: Hamburger J, Crosnier J, Grunfeld JP (Eds): Nephrology. New York, Wiley, 1979, pp 411-30.
- Sakhuja V, Chugh KS. Renal cortical necrosis. Int J Artif Organs 1986;9:145-6.
- Solez K. Pathology of kidney, 3rd ed. Boston, Little Brown and Co., 1983, pp 1121-33.
- Zuelzer WW, Charles S, Kurvetz R. Circulatory diseases of kidneys in infancy and childhood. Am J Dis Child 1951;81:1-46.
- Sheehan HL, Moore HC. Renal cortical necrosis and the Kidney of concealed Accidental Haemorrhage. Oxford: Blackwell, 1952.
- Tisher CC, Brenner BM (Eds). Renal pathology with clinical and functional correlations. Lippincott Company, Philadelphia 1989, Vol. 1: pp 700-27.
- Prakash J, Sen D, Kumar NS, Kumar H, Tripathi LK, Saxena RK. Acute renal failure due to intrinsic renal diseases: review of 1122 cases. Ren Fail 2003;25:225-33.
- Chugh KS, Singhal PC, Sharma BK, Pal Y, Mathew MT, Dhali K, et al. Acute renal failure of obstetric origin. Obstet Gynaecol 1976;48:642-6.
- Orom S, Ron G, Pell L, Winteler J. Renal cortical calcification after snake bite. Br Med J 1963;1:1647.
- Walls J, Schorr WJ, Kerr DNS. Prolonged oliguria with survival in acute bilateral cortical necrosis. Br Med J 1968;4:220-2.

17. Chris VG, Willem P, Jef A, Jos V, Paul JD. Activation of both coagulation and fibrinolysis in childhood hemolytic uremic syndrome. *Kidney Int* 1998;54:1324-30.
18. McFarlane D: Focal renal cortical necrosis in a fatal case of shock. *J Path & Bact* 1941;52:406-8.
19. Sandra WM, Nancy EG, Robert PE. Renal cortical necrosis following streptococcal infection. *Arch Intern Med* 1977;137:1196-7.
20. Campbell AC, Henderson JL. Symmetrical cortical necrosis of the kidneys in infancy and childhood. *Arch Dis Childhood* 1949;24:269-85.
21. Groshong TD, Taylor A A, Knoff DK, Esterly J, Maher JF. Renal function following cortical necrosis in childhood. *J Pediatr* 1971;79:267.
22. Perry JW. Phosphorus poisoning with cortical necrosis of the kidneys, a report of two fatal cases. *Aus Ann Med* 1953;2:94.
23. Palapattu GS, Barbaric Z, Rajfer J. Acute bilateral renal cortical necrosis as a cause of postoperative renal failure. *Urology* 2001;58:281.
24. Ober WE, Reid DE, Rommy SL, Merrill JP. Renal lesions and acute renal failure in pregnancy. *Am J Med* 1956;21:781.
25. Jeong JY, Kim SH, Sim JS, Lee HJ, Do KH, Moon MH, Lee DK, Seong CK. MR findings of renal cortical necrosis. *J Comput Assist Tomogr* 2002;26:232-6.
26. Rathod K, Garg A, Chavhan G, Rathod N. Computed tomography as a diagnostic tool in acute renal cortical necrosis. *J Assoc Physicians India* 2002;50:1451-2.

Address for Correspondence:

Dr. Suhail Muzaffar, Department of Pathology, The Aga Khan University Hospital, Stadium Road, PO Box 3500, Karachi 74800, Pakistan.

Email address: suhail.muzaffar@aku.edu