



THE AGA KHAN UNIVERSITY

eCommons@AKU

Section of Internal Medicine

Department of Medicine

January 2012

An incidentally discovered asymptomatic para-aortic paraganglioma with Peutz-Jeghers syndrome

Nazish Butt

Aga Khan University, nazish.butt@aku.edu

Mohammad Salih

Aga Khan University

Mohammad Rizwan Khan

Aga Khan University, khan.rizwan@aku.edu

Rashida Ahmed

Aga Khan University, rashida.ahmed@aku.edu

Zishan Haider

Aga Khan University

See next page for additional authors

Follow this and additional works at: https://ecommons.aku.edu/pakistan_fhs_mc_med_intern_med



Part of the [Internal Medicine Commons](#)

Recommended Citation

Butt, N., Salih, M., Khan, M. R., Ahmed, R., Haider, Z., Shah, S. H. (2012). An incidentally discovered asymptomatic para-aortic paraganglioma with Peutz-Jeghers syndrome. *Saudi Journal of Gastroenterology*, 18(6), 388-391.

Available at: https://ecommons.aku.edu/pakistan_fhs_mc_med_intern_med/42

Authors

Nazish Butt, Mohammad Salih, Mohammad Rizwan Khan, Rashida Ahmed, Zishan Haider, and Syed Hasnain Ali Shah

Case Report

An Incidentally Discovered Asymptomatic Para-Aortic Paraganglioma with Peutz-Jeghers Syndrome

Nazish Butt, Mohammad Salih¹, Mohammad Rizwan Khan², Rashida Ahmed³,
Zishan Haider⁴, Syed Hasnain Ali Shah

Departments of Medicine,
²Surgery, ³Pathology and
⁴Radiology, Aga Khan
University Hospital, Karachi,
¹Shifa International Hospital,
Islamabad, Pakistan

Address for correspondence:

Dr. Nazish Butt,
Resident Gastroenterology,
Aga Khan University Hospital,
Stadium Road, Karachi, Pakistan.
E-mail: nazish.butt@aku.edu

ABSTRACT

Peutz-Jeghers syndrome (PJS) is an autosomal dominant inherited disorder characterized by mucocutaneous melanin pigmentation and gastrointestinal (GI) tract hamartomatous polyps and an increased risk of malignancy. In addition to polyposis, previous studies have reported increased risk of GI and extraGI malignancies in PJS patients, compared with that of the general population. The most common extraintestinal malignancies reported in previous studies are pancreatic, breast, ovarian and testicular cancers. We report the case of a 17-year-old boy who presented with generalized weakness, recurrent sharp abdominal pain and melena, had exploratory laparotomy and ileal resection for ileo-ileal intussusception. Pigmentation of the buccal mucosa was noted. An abdominal computed tomography scan (CT) revealed multiple polyps in small bowel loops. Gastroscopy revealed multiple diminutive polyps in stomach and pedunculated polyp in duodenum. Colonoscopy revealed multiple colonic polyps. Pathological examination of the polyps confirmed hamartomas with smooth muscle arborization, compatible with Peutz-Jeghers polyps. CT scan guided left para-aortic lymph node biopsy revealed the characteristic features of extra-adrenal para-aortic paraganglioma. Although cases of various GI and extra GI malignancies in PJS patients has been reported, the present case appears to be the first in literature in which the PJS syndrome was associated with asymptomatic extraadrenal para-aortic paraganglioma. Patients with PJS should be treated by endoscopic or surgical resection and need whole-body screening.

Key Words: Asymptomatic para-aortic paraganglioma, intussusception, Peutz-Jeghers syndrome, screening

Received: 31.07.2012, Accepted: 10.09.2012

How to cite this article: Butt N, Salih M, Khan MR, Ahmed R, Haider Z, Shah SH. An incidentally discovered asymptomatic para-aortic paraganglioma with Peutz-Jeghers syndrome. Saudi J Gastroenterol 2012;18:388-91.

Peutz-Jeghers syndrome (PJS) is an autosomal dominant inherited disorder associated with mucocutaneous melanin pigmentation and gastrointestinal (GI) tract hamartomatous polyps, which occur most commonly in the jejunum and the ileum ($\geq 90\%$ of cases) and affects both genders equally.^[1,2] The pathogenic gene was localized to chromosome 19p34-p36 and is known as STK 11, found in approximately 70% of clinically affected patients.^[3] Most PJS patients have a characteristic clinical course of recurrent episodes of abdominal pain, small

bowel intussusception and bleeding.^[4,5]

In addition to polyposis, previous studies have reported increased risk of GI and extra-GI malignancies in PJS patients, compared with that of the general population.

We report the unique case of a patient with the PJS who incidentally discovered intra-abdominal extra-adrenal paraganglioma. As far as we know, no similar case has been reported to date.

CASE REPORT

A 17-year-old boy was presented to GI clinic with generalized weakness and episodic sharp abdominal pain. He had two exploratory laparotomies in 2006 and 2008 for ileo-ileal intussusception. He had no family history of GI disorders. Physical examination revealed pigmentation around the lips, face, and oral mucosa [Figure 1]. Laboratory data were

Access this article online	
Quick Response Code: 	Website: www.saudijgastro.com
	DOI: 10.4103/1319-3767.103432

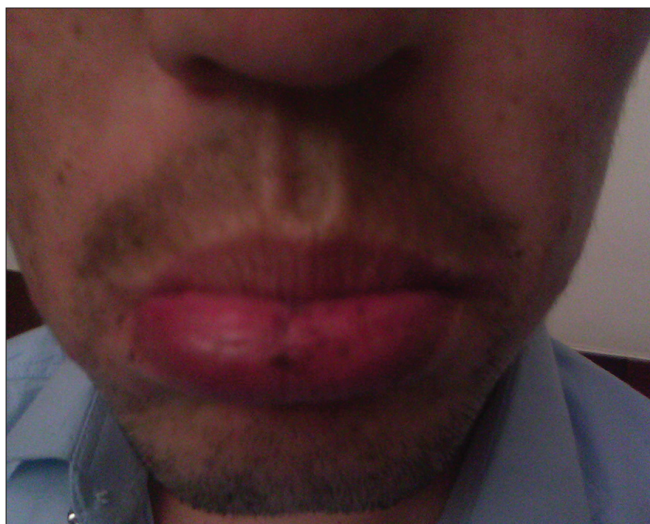


Figure 1: Melanin pigmentation on lips and face

unremarkable except for microcytic, hypochromic anemia with hemoglobin of 11.4 gm/dl. An abdominal computed tomography scan (CT) was performed revealing multiple intraluminal mass lesions, the largest one being 3.2 × 2.8 cm in small bowel loops and few of them were resulting in intussusception; however, there was no bowel obstruction noted. A large necrotic lymph node which measured 2.5 × 2.4 cm was identified in left para-aortic location [Figure 2]. CT scan-guided left para-aortic lymph node biopsy was performed and histological examination revealed a neoplastic mass composed of large polygonal cells arranged in compact aggregates with abundant finely granular eosinophilic to clear cytoplasm with distinct cell boundaries. Nuclei were round to oval and appearing mild to moderate pleomorphic and hyperchromatic. These cell nests were characteristic of paraganglioma [Figure 3]. Special glycogen stains (PAS with diastase) exhibited patchy glycogen. Immunohistochemically, tumor cells were positive for S-100 protein, chromogranin A, synaptophysin, vimentin and inhibin. Morphological and immunohistochemical features were consistent of extra-adrenal paraganglioma. His 24-hour urinary vanillyl mandelic acid (VMA) levels of 13.0 mg/24 hour (Normal: <13.6 mg/24 hour) was border line elevated. Whole body scintigraphy with ¹³¹I labeled meta-iodobenzylguanidine (MIBG) revealed focal uptake at the level of the D12/L1 on left to mid line corresponding to the neoplastic growth noted on CT.

Gastroscopy revealed multiple diminutive gastric polyps and pedunculated duodenal polyp 1.5 cm in size, removed with snare. Colonoscopy revealed multiple pedunculated polyps about 2-3 cm in size, 10 polyps were removed endoscopically with polypectomy snare [Figure 4]. Histopathological examination revealed the characteristic PJS polyp consisting of a branching framework of connective tissue and smooth

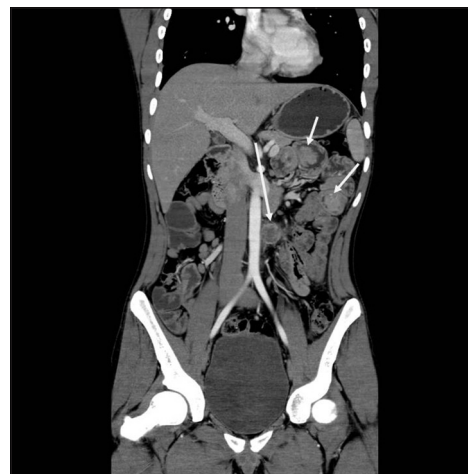

Figure 2: CT scan abdomen demonstrates intraluminal masses leading to intussusception (thick arrows) and a large necrotic lymph node in left para-aortic location (thin arrow)

muscle lined by normal intestinal epithelium, rich in goblet cells; elongated and convoluted glands and an arborizing pattern of growth [Figure 5].

Exploratory laparotomy and enteroscopy were performed and multiple, multilobulated, broad-based polyps were excised from proximal and distal jejunum. Para-aortic circumscribed, hard 4 × 3 cm mass with feeding vessel was excised.

As a result, a final pathological diagnosis of “extra-adrenal paraganglioma” with PJS was made. The patient’s postoperative period was uneventful, and the symptoms of recurrent abdominal pain resolved. He is presently under regular and close follow-up.

DISCUSSION

Patients with PJS have an increased risk of malignancies that are not confined to the GI tract. Giardiello *et al.*, first reported an increased risk of GI and non-GI cancers in patients with PJS.^[6] The most common extraintestinal malignancies reported in previous studies are pancreatic, breast, ovarian and testicular cancers. Previous studies showed 15-fold higher incidence of cancer than the general population and 93% lifetime risk of developing any cancer among the patients suffering with PJS.^[6-9]

Extra-adrenal paraganglioma is not part of the known spectrum of PJS, and thus the finding of paraganglioma and PJS may be coincidental and seems to be very rare.

Paragangliomas are rare extra-adrenal chromaffin tumors that arise from neuroectodermal cells of the autonomous nervous system and the mean age at diagnosis is reported to be about

Butt, *et al.*

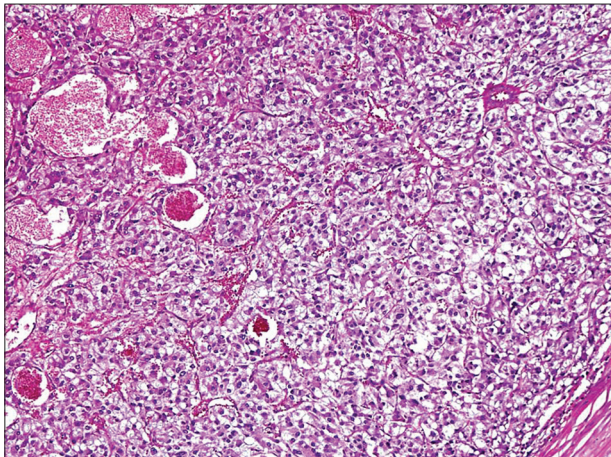


Figure 3: Histological examination showed findings suggestive of a paraganglioma. Large polygonal cells arranged in compact aggregates, exhibit abundant finely granular eosinophilic to clear cytoplasm with distinct cell boundaries, and round to oval pleomorphic and hyperchromatic nuclei

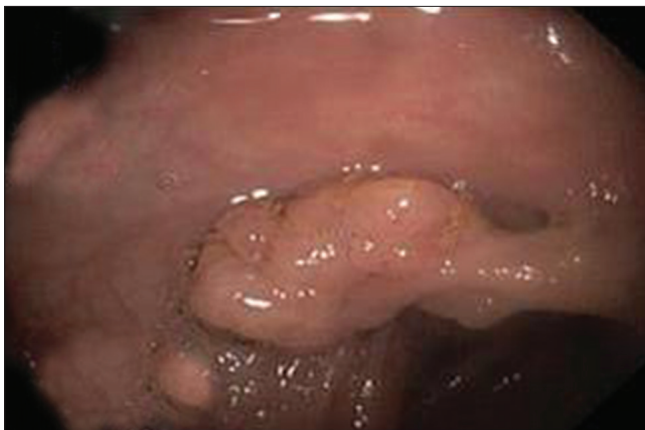


Figure 4: Endoscopic view of pedunculated colonic polyp

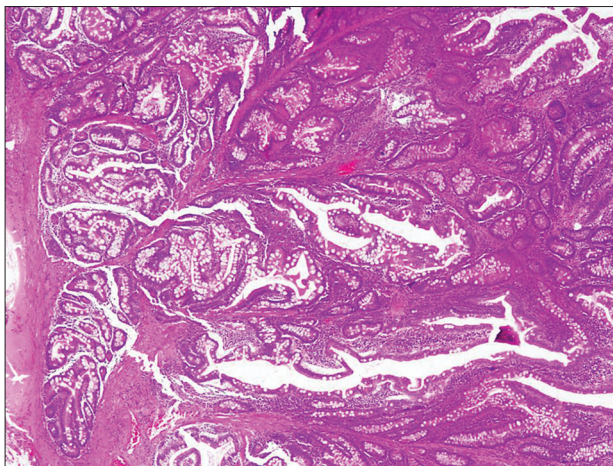


Figure 5: Histologically, PJ polyps consist of a branching framework of connective tissue and smooth muscle lined by normal intestinal epithelium, rich in goblet cells. The polyps have elongated and convoluted glands and an arborizing pattern of growth

47 years. Paragangliomas may occur in syndromic or sporadic forms.^[10,11] The former is associated with well-known syndromes of multiple endocrine neoplasia syndrome (MEN): Types 2A and 2B, Von Hippel-Lindau disease, neurofibromatosis type 1, familial paraganglioma-phaeochromocytoma syndromes.^[12] The recognized genes associated with paraganglioma are: The von-Hippel Lindau tumor suppressor gene, the RET protooncogene leading to multiple endocrine neoplasia type 2, the neurofibromatosis type 1 gene, and the three genes encoding subunits B, C, and D of mitochondrial succinate dehydrogenase. The association of paragangliomas with PJS could present a new line of investigation for the ongoing genetic studies in an effort to better understand the pathogenesis of this syndrome and its associations with non-GI malignancies.

Our patient differs from those previously reported with respect to the presence of a more rare nonfunctional extra-adrenal paraganglioma. The diagnosis and management of extra-adrenal paraganglioma in a patient with PJS does not differ from the standard methods. Once the diagnosis of paraganglioma is made, every attempt should be made to perform a complete surgical resection.^[13]

Screening and surveillance programs for PJS are mandatory both for prevention of GI complications related to the polyps and for early detection of relevant malignancies. Surveillance colonoscopy, video capsule endoscopy and upper GI endoscopy should be repeated every 3 years in patients with significant polyps detected on baseline examination. However, there is no evidence for screening of other malignancies in PJS.^[14]

CONCLUSION

In conclusion, the reported case of extra-adrenal paraganglioma in a PJS patient underlines the importance of surveillance and screening programs for GI and non-GI malignancies in these patients.

REFERENCES

1. Bartholomew LG, Moore CE, Dahlin DC, Waugh JM. Intestinal polyposis associated with mucocutaneous pigmentation. *Surg Gynecol Obstet* 1962;115:1-11.
2. Dormandy TL. Gastrointestinal polyposis with mucocutaneous pigmentation (Peutz-Jeghers syndrome). *N Engl J Med* 1957;256:1093-103.
3. Schreibman IR, Baker M, Amos C, McGarrity T. The hamartomatous polyposis syndromes: A clinical and molecular review. *Am J Gastroenterol* 2005;100:476-90.
4. Utsunomiya J, Gocho H, Miyanaga T, Hamaguchi E, Kashimura A. Peutz-Jeghers syndrome—its natural course and management. *Johns Hopkins Med J* 1975;136:71-82.
5. Westerman AM, Entius MM, de Baar E, Boor PP, Koole R, van Velthuisen ML, *et al.* Peutz-Jeghers syndrome: 78-year follow-up of

- the original family. *Lancet* 1999;353:1211-5.
- Papageorgiou T, Stratakis CA. Ovarian tumors associated with multiple endocrine neoplasias and related syndromes (Carney complex, Peutz-Jeghers Syndrome, von Hippel Lindau disease, Cowden's disease). *Int J Gynecol Cancer* 2002;12:337-47.
 - de Jong MM, Nolte IM, te Meerman GJ, van der Graaf WT, Oosterwijk JC, Kleibeuker JH, *et al.* Genes other than BRCA1 and BRCA2 involved in breast cancer susceptibility. *J Med Genet* 2002;39:225-42.
 - Giardiello FM, Welsh SB, Hamilton SR, Offerhaus GJ, Gittelsohn AM, Booker SV, *et al.* Increased risk of cancer in Peutz-Jeghers syndrome. *N Engl J Med* 1987;316:1511-4.
 - Giardiello FM, Brensinger JD, Tersmette AC, Goodman SN, Petersen GM, Booker SV, *et al.* Very high risk of cancer in familial Peutz-Jeghers syndrome. *Gastroenterology* 2000;119:1447-53.
 - Lamblin A, Pigny P, Tex G, Rouaix-Emery N, Porchet N, Leteurtre E, *et al.* Paragangliomas: Clinical and secretory profile. Result of 39 cases. *Ann Chir* 2005;130:157-61.
 - Aubertine CL, Flieder DB. Primary pulmonary paraganglioma of the lung. *Ann Diagn Pathol* 2004;8:237-41.
 - Chetty R. Familial paraganglioma syndromes. *J Clin Pathol* 2010;63:488-91.
 - Walz MK, Alesina PF, Wenger FA, Koch JA, Neumann HP, Petersenn S, *et al.* Laparoscopic and retroperitoneoscopic treatment of pheochromocytomas and retroperitoneal paragangliomas: Results of 161 tumors in 126 patients. *World J Surg* 2006;30:899-908.
 - Beggs AD, Latchford AR, Vasen HF, Moslein G, Alonso A, Aretz S, *et al.* Peutz-Jeghers syndrome: A systematic review and recommendations for management. *Gut* 2010;59:975-86.

Source of Support: Nil, **Conflict of Interest:** None declared.

Announcement

iPhone App



Download
iPhone, iPad
application

FREE

A free application to browse and search the journal's content is now available for iPhone/iPad. The application provides "Table of Contents" of the latest issues, which are stored on the device for future offline browsing. Internet connection is required to access the back issues and search facility. The application is Compatible with iPhone, iPod touch, and iPad and Requires iOS 3.1 or later. The application can be downloaded from <http://itunes.apple.com/us/app/medknow-journals/id458064375?ls=1&mt=8>. For suggestions and comments do write back to us.

New features on the journal's website

Optimized content for mobile and hand-held devices

HTML pages have been optimized of mobile and other hand-held devices (such as iPad, Kindle, iPod) for faster browsing speed.

Click on **[Mobile Full text]** from Table of Contents page.

This is simple HTML version for faster download on mobiles (if viewed on desktop, it will be automatically redirected to full HTML version)

E-Pub for hand-held devices

EPUB is an open e-book standard recommended by The International Digital Publishing Forum which is designed for reflowable content i.e. the text display can be optimized for a particular display device.

Click on **[EPub]** from Table of Contents page.

There are various e-Pub readers such as for Windows: Digital Editions, OS X: Calibre/Bookworm, iPhone/iPod Touch/iPad: Stanza, and Linux: Calibre/Bookworm.

E-Book for desktop

One can also see the entire issue as printed here in a 'flip book' version on desktops.

Links are available from Current Issue as well as Archives pages.

Click on  View as eBook