



THE AGA KHAN UNIVERSITY

eCommons@AKU

Department of Pathology and Laboratory Medicine

Medical College, Pakistan

September 2005

# Lymphoepithelioma-like carcinoma of urinary bladder: (LELCA)

Nausheen Yaqoob

Naila Kayani  
[naila.kayani@aku.edu](mailto:naila.kayani@aku.edu)

Jaipal Piryani

Mohammad Nasir Sulaiman  
*Aga Khan University*, [nasir.sulaiman@aku.edu](mailto:nasir.sulaiman@aku.edu)

Sheema H. Hasan

Follow this and additional works at: [https://ecommons.aku.edu/pakistan\\_fhs\\_mc\\_pathol\\_microbiol](https://ecommons.aku.edu/pakistan_fhs_mc_pathol_microbiol)

 Part of the [Microbiology Commons](#), and the [Pathology Commons](#)

## Recommended Citation

Yaqoob, N., Kayani, N., Piryani, J., Sulaiman, M. N., Hasan, S. H. (2005). Lymphoepithelioma-like carcinoma of urinary bladder: (LELCA). *Journal of Pakistan Medical Association*, 55(9), 402-403.

**Available at:** [https://ecommons.aku.edu/pakistan\\_fhs\\_mc\\_pathol\\_microbiol/900](https://ecommons.aku.edu/pakistan_fhs_mc_pathol_microbiol/900)

## Case Report

### Lymphoepithelioma-like carcinoma of urinary bladder: (LELCA)

Nausheen Yaqoob<sup>1</sup>, Naila Kayani<sup>1</sup>, Jaipal Piryani<sup>2</sup>, Mohammad Nasir Sulaiman<sup>2</sup>, Sheema H. Hasan<sup>1</sup>

Departments of Surgery<sup>1</sup> and Pathology and Microbiology<sup>2</sup>, The Aga Khan University Hospital, Karachi.

#### Abstract

Lymphoepithelioma-like carcinoma of the bladder (LELCA) is an uncommon neoplasm of the urinary bladder and up till now only 49 cases have been reported in the English literature. It is imperative to distinguish between lymphoepithelioma-like carcinoma and malignant lymphoma as primary bladder lymphoma is extremely rare. We report a case of a 55 year old lady who presented with the complaint of burning micturition and gross hematuria for the past 5 months. There were no other known co-morbid. Pelvic ultrasound was normal. Cystoscopy showed a 4x4 cm sessile mass in the bladder. Histopathological examination was consistent with the diagnosis of lymphoepithelioma like carcinoma of the urinary bladder.

#### Introduction

Lymphoepithelioma-like carcinoma of the bladder (LELCA) is an uncommon neoplasm of the urinary bladder and till now only 49 cases have been reported in the English literature.<sup>1</sup> It is a malignant epithelial neoplasm characterized by indistinct cytoplasmic boundaries and a syncytial growth pattern. The stroma is densely infiltrated by lymphocytes. About 90% of the malignant tumors of the bladder are urothelial carcinomas (UCs). The remaining 10% correspond to other types of carcinomas, sarcomas or other uncommon tumors.<sup>1</sup>

#### Case Report

A 55 year old lady presented with the complaint of burning micturition and gross hematuria for the past 5




Figure 1. H & E showing sheets of large epithelial cells having moderate amount of cytoplasm. The lymphoid background consisted of mature lymphocytes mixed with plasma cells (Mag 10x).

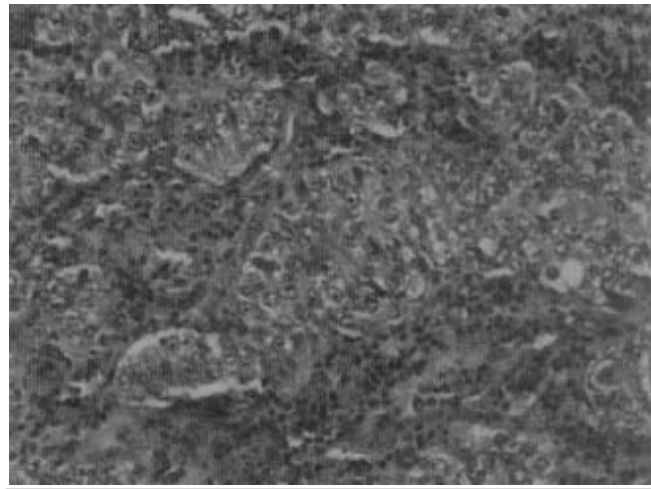


Figure 2. High power magnification showing round to oval vesicular nuclei with prominent nucleoli. Note mitotic figures.

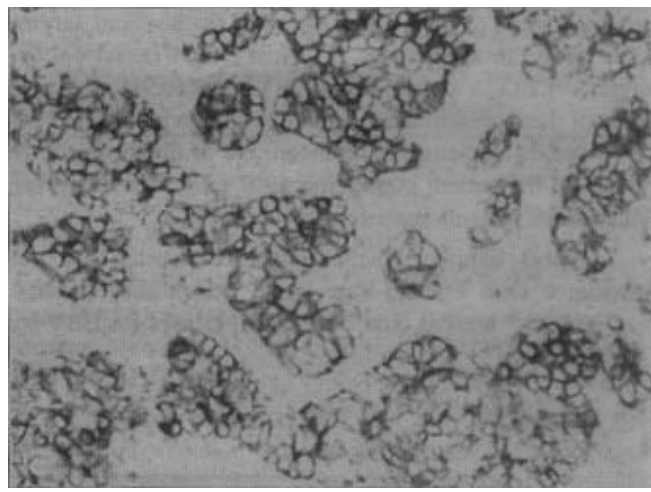


Figure 3. The tumour cells are strongly positive for epithelial marker CK MNFs.

months. She had past medical history of sphenoid wing meningioma for which she was operated two years back with an uneventful recovery. There were no other known co-morbid. There was no history of exposure to carcinogenic material or cigarette smoking. Pelvic ultrasound was normal. Cystoscopy showed a 4x4 cm sessile mass in the right superolateral wall of the bladder invading deep into the bladder muscle. The whole tumor was resected endoscopically. The specimen was sent for histopathology. Gross examination showed multiple irregular fragments of tissue measuring 5 cm in aggregate. Microscopically the tumor was composed of sheets and clusters of large epithelial cells having moderate amount of cytoplasm. The lymphoid background consist-

of mature lymphocytes mixed with plasma cells. (Figure 1) Abundant mitotic figures were present. The nuclei were round to oval and vesicular with prominent nucleoli. (Figure 2) Glycogen was identified in the epithelial cells. The tumor cells were strongly positive for epithelial markers (CK MNF (Figure 3), CK cam 5.2, CK AE1/AE3 and negative for lymphoid markers (LCA CD45;RO, Pan B;CD20 and CD79a, Pan T; UCHL1) and vimentin. Protein p53 was positive in 80-85% of the nuclei of epithelial cells and negative in the lymphoid cells. Overlying urothelium showed no dysplasia. The tumor was deeply infiltrating into the detrusor muscle. A diagnosis of lymphoepithelioma like carcinoma of the urinary bladder was made.

## Discussion

Lymphoepithelioma-like carcinoma of the bladder was described by Zuckerberg et al<sup>2</sup> in 1991 and till now 49 cases have been published. They represent 0.4% and 1.3% of the bladder carcinomas.<sup>3</sup> It is imperative to distinguish between lymphoepithelioma-like carcinoma and malignant lymphoma as primary bladder lymphoma is extremely rare.<sup>4</sup> LELC was originally described in nasopharynx, but it has also been found in other organs, such as salivary gland, thymus, uterine cervix, skin, lung, stomach, oral cavity, breast, vagina, trachea and larynx and, rarely, in other areas of urinary tract (renal pelvis, ureter).<sup>5</sup> LELCA are usually small tumors (0.9-5 cm)<sup>5</sup> and most of them present a clinical onset with hematuria, as we described in our cases. The mean age at diagnosis is 69 years. Of the patient population 69% were men<sup>3</sup> however both of our patients were females.

Most lymphoepithelioma-like carcinomas are not associated with Epstein-Barr virus, except those of the nasopharynx<sup>6</sup> Iezzoni et al examined 11 cases for EBV by RNA ISH EBER and none showed EBER transcripts.<sup>7</sup>

Expression of p53 is commonly seen in Ucs and this positive phenotype is more common in high grade and advanced Ucs. Izquierdo-Garcia et al has studied p53 protein expression in LELCA and has seen intense reaction of p53 in 90-95% of their nuclei, however despite this finding and despite that they have been treated with preservation of the bladder, they have followed a good clinical course.<sup>1</sup> In our cases p53 protein expression was seen in 80-85% of the nuclei. Lymphoepithelioma-like carcinoma is sensitive to cisplatin based chemotherapy<sup>8</sup> and radiotherapy, reviewing the literature and evaluating the present results, a combination of TURBT and adjuvant chemotherapy is probably effective against LELCA, avoiding radical cystectomy.

## References

1. Izquierdo-Garcia FM, Garcia-Diez F, Fernandez I, Perez-Rosado A, Saez A, Suarez-Vilela D, et al. Lymphoepithelioma-like carcinoma of the bladder: three cases with clinicopathological and p53 protein expression study. *Virchows Arch* 2004;444:420-5.
2. Zuckerberg LR, Harris NL, Young RH. Carcinomas of the urinary bladder simulating malignant lymphoma. A report of five cases. *Am J Surg Pathol* 1991;15:569-76.
3. Porcaro AB, Gilioli E, Migliorini F, Antonioli SZ, Iannucci A, Comunale L. Primary lymphoepithelioma-like carcinoma of the urinary bladder: report of one case with review and update of the literature after a pooled analysis of 43 patients. *Int Urol Nephrol* 2003;35:99-106.
4. Ward JN, Dong WF, Pitts WR Jr. Lymphoepithelioma-like carcinoma of the bladder. *J Urol* 2002;167:2523-4.
5. Lopez-Beltran A, Luque RJ, Vicioso L, Anglada F, Requena MJ, Quintero A, et al. Lymphoepithelioma-like carcinoma of the urinary bladder: a clinicopathologic study of 13 cases. *Virchows Arch* 2001;438:552-7.
6. Constantinides C, Giannopoulos A, Kyriakou G, Androulaki A, Ioannou M, Dimopoulos M, et al. Lymphoepithelioma-like carcinoma of the bladder. *BJU Int* 2001;87:121-2.
7. Iezzoni JC, Gaffey MJ, Weiss LM. The role of Epstein-Barr virus in lymphoepithelioma-like carcinomas. *Am J Clin Pathol* 1995;103:308-15.
8. Dinney CP, Ro JY, Babaian RJ, Johnson DE. Lymphoepithelioma of the bladder: a clinicopathological study of 3 cases. *J Urol* 1993;149:840-1.