



THE AGA KHAN UNIVERSITY

eCommons@AKU

Department of Pathology and Laboratory Medicine

Medical College, Pakistan

December 2000

Granular cell tumor of the breast: an uncommon lesion that mimics carcinoma

S Muzafar

Aga Khan University

M S. Siddiqui

Aga Khan University

Naila Kayani

Aga Khan University, naila.kayani@aku.edu

I K. Lodhi

Aga Khan University

Sheema H. Hasan

Aga Khan University, sheema.hasan@aku.edu

Follow this and additional works at: https://ecommons.aku.edu/pakistan_fhs_mc_pathol_microbiol

 Part of the [Microbiology Commons](#), and the [Pathology Commons](#)

Recommended Citation

Muzafar, S., Siddiqui, M. S., Kayani, N., Lodhi, I. K., Hasan, S. H. (2000). Granular cell tumor of the breast: an uncommon lesion that mimics carcinoma. *Journal of Pakistan Medical Association*, 50(12), 426-428.

Available at: https://ecommons.aku.edu/pakistan_fhs_mc_pathol_microbiol/859

Granular Cell Tumor of the Breast: an Uncommon Lesion that mimics Carcinoma

Suhail Muzafar, Mohammad Shahid Siddiqui, Naila Kayani, Sheema H. Hasan (Department of Pathology, The Aga Khan University Hospital, Karachi.)

Iqbal Khan Lodhi (Department of Consultant Surgeon, M. Rah Medical Centre, Karachi.)

Introduction

Granular cell tumors (granular cell rnyoblastoma) are neoplasms Which pursue a benign clinical course in large majority of cases. Tongue is the classic location for this tumor, however, rarely it is seen ill many other sites. Cases of granular cell tumor have been described in both male and female breasts¹⁻⁶ The recognition of this entity in breast is important because it mimics breast carcinoma clinically, radiologically and on macroscopic examination. We present a case of granular cell tumor presenting as breast mass in a young female. The aim of presenting this case is to emphasize the importance of identifying this rare neoplasm in the breast which closely simulates breast carcinoma and may result in inappropriate radical surgery. Moreover, especially in the present era in which fine needle aspiration cytology and intraoperative frozen section are the frequently used diagnostic modalities, a preoperative or intraoperative diagnosis of the lesion will help to plan limited surgery.

Case Report

A-35 years old married woman presented with a lump in lower inner quadrant of her right breast which she noticed two and a half years back while she was pregnant. Initially the lump was small but slowly increased to the present size. There was no history of nipple discharge. On examination a hard, oval, mobile lump was identified extending from below the right areola to the lower inner quadrant and measured 7x6x3 cms. The overlying skin was freely movable and the nipple was not retracted. The axillary lymph nodes were not palpable. Excision of the lump was carried out with an intraoperative feeling of antibioma. Macroscopic examination revealed a grey white, firm to hard tumor with a homogenous grey white cut surface. The margins were ill defined and the tumor was focally extending into the adjacent fibroadipose tissue (Figure 1).

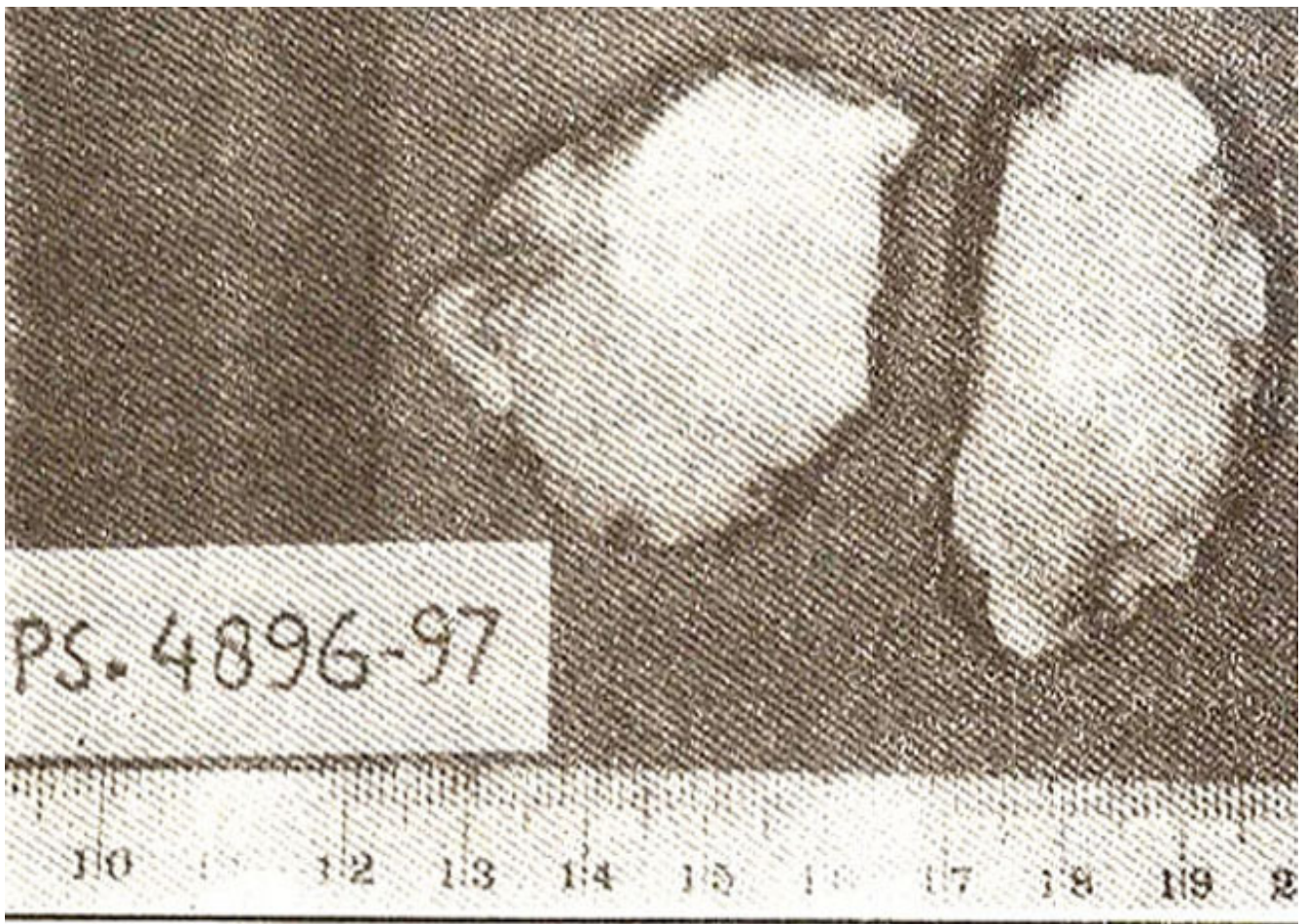


Figure 1. Gross photograph of granular cell tumor of the breast. Note large tumor with homogenous grey white cut surface and ill defined margins.

Microscopically, the tumor was composed of nests of large, polygonal cells separated by bands of fibrovascular tissue. The tumor cells revealed abundant granular, eosinophilic cytoplasm and a centrally placed dense, oval nucleus with no significant mitotic activity. Atypia, hyperchromasia or abnormal mitosis were not seen. Breast ducts and lobules were seen trapped in the lesion (Figure 2).

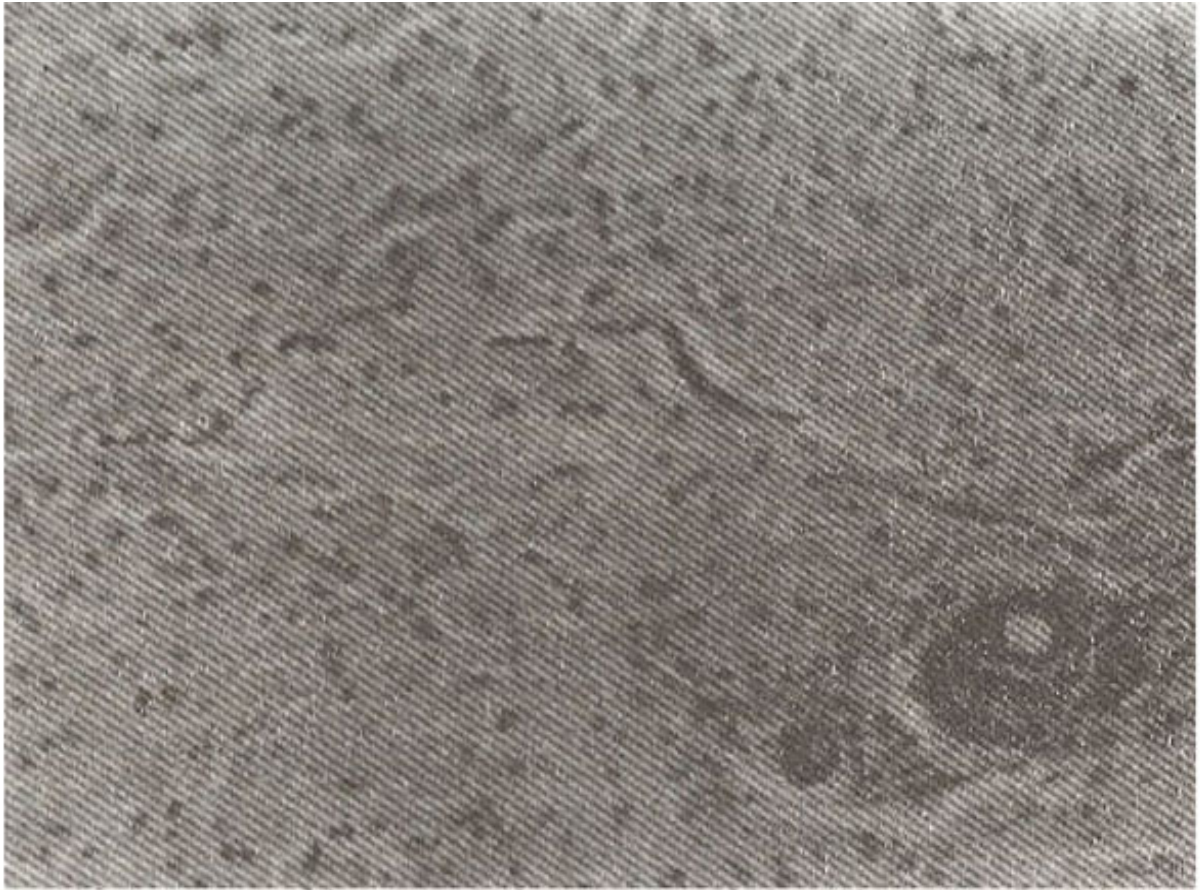


Figure 2. Photomicrograph of granular cell tumor consisting of large polygonal cells with coarsely granular cytoplasm and small pyknotic nuclei. Note entrapped breast duct lobule in right lower quadrant (H and E Stain; Mag. X 100).

The tumor cells showed PAS (periodic acid Schiff) positive and diastase resistance material in the cytoplasm. Immunohistochemical studies were carried out on tumor tissue using a panel of antibodies which revealed positive reactivity for 5-100 and neurone specific enolase (NSE). Desmin, alpha smooth muscle actin and cytokeratins stains were negative in tumor cells.

Discussion

Granular cell tumor was first recognized as a distinct clinical entity in 1926 after the work of Abrikosof who proposed this tumor to be of muscle iii origin, hence designed as myoblastoma⁷. However, based on histochemical, immunohistochemical and ultrastructural findings the lesion is favoured by most investigations as Schwann cell in origin⁸. These tumors are usually small and in most cases measured less than 3cms in diameter. They have hard consistency and ill defined margins; two features which strongly raise the suspicion of malignancy. Granular cell tumors are most commonly found in head and neck region particularly the tongue⁹. It has been seen in many other locations such as skin, vulva, larynx, bronchus, esophagus, stomach, appendix, rectum, anus, bile ducts, pancreas, urinary bladder, uterus, brain, pituitary gland and soft tissue¹⁰. Granular cell tumor in breast is a rare occurrence and mimics breast carcinoma clinically and radiologically. About 6% of the granular cell tumors have been reported in the breast¹¹, They are far less common than breast carcinoma and there are about 1000 cases of breast carcinoma for every case of mammary granular cell tumor¹². Mammographically some granular cell tumors manifest as discrete rounded nodules, while others tend to present as stellate lesion supporting the clinical impression of carcinoma¹³. Boulat et al¹⁴ reviewed

159 cases of granular cell tumors of breast reported in the literature out of which 121 cases were well documented. Age range was 15 to 74 years and 9.8% cases were reported in male breasts. Immunohistochemical studies revealed positivity for S-100 protein, NSE, vimentin and myelin basic protein. Cytokeratins, desmin and muscle specific actin were negative. Ultrastructural studies showed granular cells packed with lysosomal vacuoles containing organelles as well as myelin figures and other debris. These cells frequently show Schwann cell features such as continuous basal lamina and long spacing collagen. Most granular cell tumors behave in a benign fashion and surgical excision with safe margins is usually curative. As the lesion has infiltrative margins, so incomplete excision may result in local recurrence. This emphasises the need of recognising this lesion on fine needle aspiration cytology or on frozen section, so that an adequate curative resection may be planned in the first instance. Malignant granular cell tumors of the breast have been reported in the literature¹⁵. Benign and malignant granular cell tumors are remarkably similar in histological appearance. However, malignant tumors are usually larger in size and the tumor cells are often smaller, elongated and more pleomorphic. In addition, the nuclei are generally hyperchromatic and irregular with an increased nucleus to cytoplasm ratio. An increased mitotic activity with an average of 2 or more mitoses per ten high power field is seen in malignant lesions. Although the histology of granular cell tumor is quite characteristic and usually do not produce diagnostic problems, the other entities which can mimic in the differential diagnosis of this lesion include rhabdomyoma, alveolar soft part sarcoma, hibernoma and fibroxanthoma.

References

1. Komee F, Ivlercer I., Schmidt RA et al. Granular cell tumor of the breast mimicking carcinoma in pregnancy. *Obstet Gynecol.*, 1989;73:898-900.
2. Morrison JG, Gray OF, Dao AH et al. Granular cell tumors, *Am. J. Surg* 1987;53:156- 160.
3. Lelle RJ, Park H and Brow CA Benign granular cell tumor mimicking carcinoma of the breast. Report of a case. *Eur. J. Gynecol. Oncol.*, 1992;13:390-393.
4. Strobel SL, Shah NT, Lucas JG, et al. Granular cell tumor of the breast. A cytologic, immunohistochemical and ultrastructural study of two cases. *Acta Cytol.* 1985;29:598-601.
5. Mariscal A, Perea RI, Castella E. et al Granular cell tumor of the breast in a male patient. *Am. J. Roentgenol.* 1995;165:63-64.
6. Kragel PI, Fiorella RM, and Kremer H Tumoral fibrosis and lack of circumscription of granular cell tumor of the breast. *South Med. J.*, 1995;88: 1146-1148.
7. Abrikossov A. Ueber Myome ausgehend von der quergestreiften willkürlichen Muskulatur. *Virchows Arch (A)*., 1926;260:21 -.
8. Raju GC and Reilly AP. Immunohistochemical study of granular cell tumor. *Pathology.* 1987;19:402-406.
9. Mathews JB and Mason OI. Oral granular cell myoblastoma. An immunohistochemical study. *J. Oral Pathol*, 1987;9:341-345.
10. Rosai J. Granular cell tumor- Soft tissue. In Rosai J. ED. *Ackerman's Surgical Pathology*. 8th Edition (Volume 2). St. Louis, Missouri Mosby. 1996, pp.2096-2098.
11. Basset LW and Cove U. Myoblastoma of the breast *Am. J. Roentgenol*, 1979;132:122-123.
12. Gordon AB, Fisher C, Palmer J et al. Granular cell tumor of the breast. *Br. J. Surg. Oncol.*, 1985;11:266-273.
13. Tavassoli FA. Mesenchymal lesions In: Tavassoli FAM, ED *Pathology of the breast*. Connecticut, Appleton and Lange, 1992, p.536.
14. Boulat J, Mathoulin MP, Vachuret H et al, Granular cell tumor of the breast. *Ann. Pathol.*, 1994;14:93-100.
15. Chetty and Kalan MR Malignant granular cell tumor of the breast. *J. Surg. Oncol.*, 1992;49:135-137.