



THE AGA KHAN UNIVERSITY

eCommons@AKU

Department of Pathology and Laboratory Medicine

Medical College, Pakistan

June 2004

Mucormycosis complicating interstitial nephritis-- two cases and brief literature review

A Malik

Aga Khan University

A Soofi

Aga Khan University

A Ahmad

Aga Khan University

N Kayani

Aga Khan University, naila.kayani@aku.edu

Follow this and additional works at: [https://ecommons.aku.edu/
pakistan_fhs_mc_pathol_microbiol](https://ecommons.aku.edu/pakistan_fhs_mc_pathol_microbiol)



Part of the [Microbiology Commons](#), and the [Pathology Commons](#)

Recommended Citation

Malik, A., Soofi, A., Ahmad, A., Kayani, N. (2004). Mucormycosis complicating interstitial nephritis--two cases and brief literature review. *Journal of Pakistan Medical Association*, 54(6), 332-334.

Available at: https://ecommons.aku.edu/pakistan_fhs_mc_pathol_microbiol/925

Anti-Rh17 (Anti-Hr0): a rare Diagnostic and Management Problem

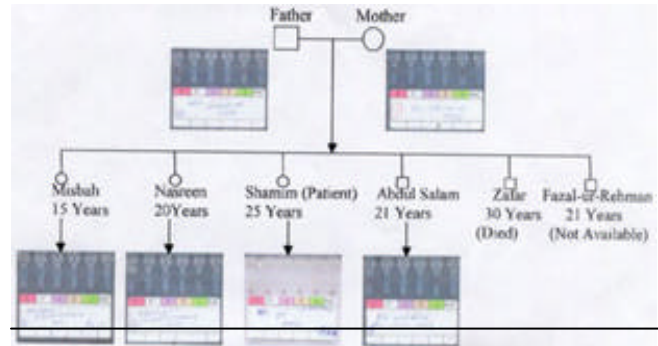
N. Salamat, F. A. Bhatti, A. Hussain, Ziaullah
Armed Forces Institute of Transfusion, Rawalpindi.

Introduction

Of all blood group systems, anti Rh antibodies are the commonest cause of haemolytic disease of the newborn (HDN) and its diagnosis and management plan is well established. Also immunization with 'D' antigen can be effectively prevented by prophylactic use of anti-D Immunoglobulin. Therefore its prevalence has declined but now less common alloantibodies are frequently encountered posing different management problems. Anti Rh17 is also a rare alloantibody¹ produced after immune stimulus, by individuals who lack C/c and E/e antigens of Rh blood group on their red cells. This rare blood group is designated as D- - and was first described by Race and Sanger² in 1950. We report diagnosis and management of a pregnant lady with anaemia, mitral valve disease and anti Rh17 alloantibody who required blood for operation and her baby suffered from hydrops foetalis.

Case Report

A 35 years old lady, (gravida 4, term 2, premature 0, abortion 0, live birth 1) diagnosed case of moderately severe mitral valve stenosis was admitted in Armed Forces Institute of Cardiology (AFIC) with amenorrhoea of 7 months duration, shortness of breath NYHA III/IV and palpitations for 5 months. Her first pregnancy ended in intrapartum death in 1998 at full term. Next year a full term healthy boy was delivered by Caesarean-section and patient was transfused one unit of whole blood in post partum period. The child did not have a history of neonatal jaundice or anaemia. In 2001 her next pregnancy ended with intrauterine death at 34th week of gestation and dead hydropic fetus was delivered by Caesarean-section. Fourth pregnancy started in Oct 2002 and she became progressively dyspnoeic, had palpitations and was



hospitalized. Her physical examination revealed tachycardia with regular rhythm, BP of 110/70 mmHg, respiratory rate 24/min and pitting edema of both feet. Grade II diastolic murmur was audible on precordium. Abdominal fundal height was 38 weeks while gestational age by dates was 34 weeks. Her haemoglobin level was 4.3 g/dl, with red cells showing microcytosis and hypochromia. Echocardiography showed moderately severe mitral stenosis and ejection fraction of 65%. Rest all of the investigations were within normal limits. Ultrasound of abdomen revealed single alive foetus with ascites and pleural effusion, suggesting hydrops foetalis, whereas placenta was large and fundal and she had developed polyhydramnios. She was prescribed 1/V injection of Iron sucrose (Venofer) 20 mg/day for 6 days and also received oral iron/folic acid 200 mg, Spironolactone 40 mg, and Digoxin 0.25 mg every day. Clotted blood sample of the patient was sent to our centre for grouping and cross matching. The serological test³ and results following this request are summarized in Table 1. Interpretation of these results was that patient is having IgG type, alloantibody, directed against some high frequency (public) red cell antigen. To determine the specificity of antibody and to find compatible blood, rare red cells panels and antisera were

Table 1. Initial serological tests.

S. No	Test	Reagent	Method	Result
1.	ABO Grouping	(Monoclonal Bio Tech Labs Ltd,UK)	Tube, IS	BEE
2.	Rh 'D' Grouping	Monoclonal IgM + IgG Blended, Biotech Labs Ltd, UK)	Tube, IS	D Positive
3.	Cross match with random donors	Lorne UK, LISS, AHG	Tube LISS IAT	Incompatible with all donors
4.	Antibody screening with 3 Cell panel	Maxi screen cells Lorne, UK	LISS-Additive IAT in Tube	1+ at 37°C with all cells and 4+ agglutination with all three cells with IAT
5.	Auto control	-	RT, 37°C, IAT	Negative
6.	Direct antiglobulin test	AHG, Lorne UK	Tube	Negative
7.	Antibody identification, 11 cell panel	Lorne, UK	RT, 37°C, LISS Additive	1+ at 37°C with all cells and 4+ agglutination with all cells in both IAT's
8.	Kell phenotype	DiaMed-ID antigen profile Dia-Med AG, Switzerland	Micro column gel technique with appropriate controls	K-, k+

Table 2. Confirmatory serologic tests.

S. No	Test	Reagent	Result	Result
1.	Reaction with Rh Null cells	-	-	No agglutination
2.	Rh phenotype of red cells	DIA Med ID II	No agglutination with anti C, c, E, e	D-- phenotype
3.	Chemiluminescence test (CLT)	-	-	-
a.	Prediction of transfusion outcome: Red Cell		Opsonic index without AB serum	Opsonic index With AB serum
		R ₁ ^w R ₁	17.6	29.4
		Rh Null	1.2	1.2
b.	Prediction of HDFN Red cell	-	-	CLT %
		R ₁ ^w R ₁		176
		Rh Null	-	2

HDFN: Haemolytic disease of fetus and newborn

needed which were not available with us therefore the patient's blood samples were sent to International Blood Group Reference Laboratories (IBGRL), Bristol, UK. Meanwhile search for compatible blood among first-degree relatives was made and yielded no success.

Erythropoietin at a dose of 40 µg/kg/day was started in addition to other antianaemics and haemoglobin was successfully raised to 10.5 g/dl. One autologous unit of 300 ml was collected preoperatively. Because of scar tenderness

and distressing dyspnoea due to hydramnios caesarean section was performed, three days after autologous donation on 25 May 2003, delivering dead hydropic foetus. Tubal ligation was not performed. Autologous unit was transfused in postoperative period and the patient made uneventful recovery.

Results from IBGRL were received 10 days after her operation, which are shown in Table 2. The rare alloantibody in propoita was antiRh17, which was further

confirmed by phenotyping patient's red cells at our center. There were no C/c and E/e antigens on her cells (Table 3, Figure). The opsonic index in chemiluminescence test show significant transfusion and haemolytic disease causing potential of the antibody. Later Rh phenotyping of patient's family was done, whose results are shown in Table 3 and Figure 1. Both parent's RBC phenotype was B, D+,C+,e+ and their most likely genotypes were DCE/D-- . The proposita and her sister were D--/D--. None of the family members was Rh Null. The patient and her husband were counselled in detail. Patient and her sister having regular follow-up at our institution.

S. No	Name	ABO	D	C	C*	c	E	e
1.	Bashir F/o Shamim	B	+	+	0	0	0	+
2.	Aman Bibi M/o Shamim	B	+	+	0	0	0	+
3.	Ab Salam Bro/o Shamim	B	+	+	0	0	0	+
4.	Naroon Sisto Shamim	B	+	+	0	0	0	+
5.	Mirbab Sisto Shamim	B	+	0	0	0	0	0
6.	Paternal Cousin S/o Sharif	A	+	+	0	0	0	+
7.	Paternal Cousin Shaked S/o Sharif	A	+	+	0	+	+	+
8.	Paternal Cousin S/o Nazir	B	+	+	0	0	0	+
9.	Paternal Cousin Tahira D/o Nazir	B	+	+	0	0	0	+
10.	Paternal Cousin Khalida D/o Nazir	B	+	+	0	0	0	+
11.	Paternal Cousin Rahat D/o Zubaida	A	+	+	0	+	0	+
12.	Paternal Cousin Qamar D/o Zubaida	B	+	+	0	+	0	+
13.	Shamim (Patient)	B	+	0	0	0	0	0

Discussion

The proposita developed an unusual alloantibody, anti Rh 17, as a result of a transfusion in her second post partum period. This antibody has reactivity against Rh17 (Hro) antigen of Rh blood group system and is formed by individuals who lack all Rh antigens (C/c and E/e antigen therefore have no Hro antigen) except D¹. Genetically Rh antigens are coded by 2 genes on chromosome 1. RHD coding for D antigen and RHCE is responsible for C/c and E/e antigens.⁴ Molecular basis for D-- phenotype is not clear but recombination of RHD and RHCE genes have been documented.⁵ This antibody is formed by immune stimulus⁶ like transfusion or pregnancy and usually show single specificity but sometimes separate specificities like anti 'e' may be seen.⁷ Our patient escaped immunization due to fetomaternal haemorrhage during her first two pregnancies hence she was able to have an alive and normal baby after the second pregnancy. Immune causes of hydrops foetalis were not excluded after birth of first hydropic baby (third pregnancy) although it required a simple test like antibody screening with standard reagents. Anti Rh 'D' is the most common alloantibody causing morbidity and mortality due to HDN⁸ followed by anti c, Kell, C, E, e, Duffy and Kidd.⁹ These must be excluded especially with a history of hydropic baby, irrespective of the Rh blood group.

Determining specificity of antibody is important for future obstetrical management. Therefore all efforts should be made to achieve this.

Initial red cell serological tests and their results are shown in Table 1. These indicated that either patient has clinically significant, pan reactive, IgG alloantibody, against some public antigen or an autoantibody, which is capable of crossing the placenta and causing foetal complications. Negative direct antiglobulin and auto control test excluded the possibility of auto antibodies and also these are rarely associated with hydrops. Other alloantibodies likely to yield similar results with the red cell identification panel used were anti Tja, anti U, and anti 'k' (chelano) antibody. Anti chelano was excluded indirectly by phenotyping patient's cells for 'k' antigen, on the basis that if the cells were 'k' antigen positive then antibody could not be 'anti k'. In the absence of appropriate reagents we could not exclude other suspected antibodies and did not consider Rh system antibodies, as the red cell panel in use was adequate to exclude common anti Rh antibodies. Diagnosis of specificity of antibodies against high frequency, public antigens is important for future counseling, obstetrical outcome, neonatal management and arranging transfusion support. Help from a reference center abroad (International Blood Group Reference Laboratories (IBGRL), Bristol UK) was sought and patient's serum samples were sent to them. In the absence of inventory or database for rare donors in any local blood bank it was almost impossible to find compatible blood. We resorted to time old method of checking first-degree relatives of patient for compatible phenotype. None of those brought to us had compatible blood although later family studies did reveal that one sister (fifteen years old) had exactly the same phenotype as proposita (Table 3). There is no national frozen blood bank of rare donors either which could have provided rare phenotype red cells as is usually possible in many developed countries.

Phenotyping of red cells was done at our center as the cells were haemolyzed during transportation, which revealed absence of C/c and E/e antigens on patient's red cells (Table 2). IBGRL, Bristol UK communicated to us that this phenotype is most prevalent in Japanese population and the frozen blood banks there can provide such blood on request. Also we were provided important contacts in Japan. The results of Chemiluminescence test (CLT) done at IBGRL yielded expected results because the past or present history of hydrops is the most sensitive indicator of clinical significance of any alloantibody (Table 2).

Elective Caesarian section had to be done without delay to avoid complications of the dead baby and also worsening polyhydramnios was causing tenderness in previous surgical scar and respiratory distress to the patient.

This precluded liaison with Japanese blood banks, which we were contemplating. Meanwhile small volume autologous donation was collected as patient's haemoglobin had risen adequately within one week with antianaemics and erythropoietin. Autologous donation in the form of predeposit, preoperative haemodilution or cell salvage are very important means of providing blood for cases with rare alloantibodies and limited resources.¹⁰ It can prove to be a safe option even with co-morbid conditions provided haemoglobin is adequate and blood is collected carefully. This can be done as small volume frequent donations. Tubal ligation was not performed at the time of caesarian section and we are unaware of any contraceptive counselling of the couple, therefore we assume that they may be at risk for future foetal complications.

People have tried to lower the alloantibody levels in post conception period with plasma exchange¹¹ without much success therefore such efforts may not help our patient in future. Very few similar cases due to anti Rh17 antibodies have been reported.¹²⁻¹⁵ Usually this antibody causes moderate to severe haemolytic disease of the newborn. The foetal management includes intrauterine transfusions with frozen rare donor blood or maternal blood if diagnosed early during pregnancy.¹³ In other cases exchange transfusions with maternal blood (frozen previously or freshly donated) has been used with successful outcome.¹⁶ Some authors have reported good neonatal outcome even with repeated incompatible Rh D negative exchange transfusions.^{17,18} Use of intravenous immunoglobulins to inhibit haemolysis before and following the exchange transfusion has been reported to be successful.^{15,19}

The extensive family studies of proposita were undertaken (Table 3 and Figure) with an aim of finding more compatible donors for future as well as for sending blood of those affected to New York blood center, USA, for identification of mutation in the family which may be a new one, not previously reported. Also these individuals can help us to prepare rare red cell reagent panels that are expensive if imported and has short shelf life. These individuals can also become part of rare donors programme in future. Our center is now better prepared to arrange blood for the patient or her foetus in case of intrauterine transfusion, in future. The options are to get blood donation from her sister, autologous donation and/or frozen blood requested from abroad.

We gained useful insight that excluding antibodies in Rh blood group systems before considering any other specificity is the most useful practical approach in case of anti IgG alloantibodies in pregnant ladies. In absence of rare red cell panels, phenotyping for Rh blood group system using basic sera or micro column gel system could help to exclude a significant group of alloantibodies, although this

is a deviation from traditional teaching and can not be applied to recently transfused patients. Antibody screening of all pregnant ladies, irrespective of Rh group should be carried out as per standard guidelines for serological screening tests in pregnancy.²⁰ This is particularly indicated after birth of a hydropic baby. Maintaining rare red cells reagents may not be possible for every transfusion center, however liaison with international reference centers can have fruitful results.

Acknowledgements

We are very thankful to Dr. Joyce Poole and Mr. Anthony M. Wilkes of International Blood Group Reference Laboratories, UK for their technical support in determining the specificity and pathogenic potential of the antibody.

References

1. Mario. E, Oyen RR, Morsh WL. Summary of the clinical significance of blood group alloantibodies. seminars in hematology. 2000;37:197-216.
2. Race RR, Sanger R. Blood groups in man. 6th ed. London: Blackwell; 1975, p. 215.
3. American Association of Blood Banks. Technical manual 13th edition. Bethesda: AABB, 1999.
4. Tippett P. A speculative model for Rh blood group. Ann Hum Genet 1986;50:241-7.
5. Kemp T J, Poulter M, Carritt B. A recombination hot spot in the Rh genes revealed by analysis of unrelated donors with the rare D--phenotype. Am J Hum Genet 1997;60:749.
6. Daniels G. Human blood group. Oxford: Blackwell;1995, pp. 313-5.
7. Reid ME, Lomas FC. The blood group antigen fact book. London: Academic Press, 1997.
8. Clarke CA, Hussey RM. Decline in deaths from Rhesus haemolytic disease of the newborn. J R Coll Physicians 1994;28:310-11.
9. Bowman JM. Hemolytic disease of the new-born. Vox Sang 1996;70(suppl 3):62-7.
10. Renner SW, Howanitz PJ, Bachner P. Preoperative autologous blood donation in 612 hospitals. Arch Pathol Lab Med 1992;116:613-9.
11. Robinson AE. Principles and practice of plasma exchange in the management of Rh hemolytic disease of the newborn. Plasma Therapy 1984;5:7-14.
12. Lenkiewicz B. Moderate hemolytic disease of newborn due to anti-Hr0 in a mother with the D--/D--phenotype. Immunohematology 2000;16:109-111.
13. Whang DH, Kim HC, Hur M, et al. A successful delivery of a baby from a D--/D-- mother with strong anti-Hr0. Immunohematology 2000;16:112-14.
14. Hanks KS, Kim HC, Han KS, et al. A case of fetal hemolytic disease of the newborn associated with D--/D--phenotype. Am J Perinatol 1997;14:495-7.
15. Aref K, Boctor FN, Pande S, et al. Successful perinatal management of hydrops fetalis due to hemolytic disease associated with D-maternal phenotype. J Perinatol 2002;22:667-8.
16. Deitenbeck R, Tutschek B, Crombach G, et al. Successful management of pregnancy and hemolytic disease of the newborn due to anti - Hr0 in a woman of D-phenotype. Transfusion 1999;39:1151-2.
17. Diao Y, Song N, Guan Z, et al. A case of hemolytic disease of the newborn caused by anti-Hr0 and anti-e. Proc Chin Acad Med Sci Peking Union Med Coll 1990;5:58-60.
18. Lubenko A, Contreras M, Portugal CL, et al. Severe haemolytic Disease in an infant born to an Rh(null) proposita. Vox Sang 1992;63:43-7.
19. Tanyer G, Siklar Z, Dallar Y, et al. Multiple dose IVIG treatment in neonatal immune hemolytic jaundice. J Trop Pediatr 2001;47:50-3.
20. British Committee for Standards in Haematology, Blood Transfusion Task Force. Guidelines for blood grouping and red cell antibody testing during pregnancy. Transfusion Med 1996;6:71-4.