



THE AGA KHAN UNIVERSITY

eCommons@AKU

Department of Pathology and Laboratory Medicine

Medical College, Pakistan

July 2006

Mixed epithelial and stromal tumour of kidney

Fozia Rauf

Aga Khan University

Nausheen Yaqoob

Aga Khan University

Akhtar Husain

Aga Khan University

Follow this and additional works at: https://ecommons.aku.edu/pakistan_fhs_mc_pathol_microbiol

 Part of the [Microbiology Commons](#), and the [Pathology Commons](#)

Recommended Citation

Rauf, F., Yaqoob, N., Husain, A. (2006). Mixed epithelial and stromal tumour of kidney. *Journal of Pakistan Medical Association*, 56(7), 340-341.

Available at: https://ecommons.aku.edu/pakistan_fhs_mc_pathol_microbiol/919

Mixed Epithelial and Stromal Tumour of Kidney

Fozia Rauf, Nausheen Yaqoob, Akhtar Husain

Department of Pathology and Microbiology, Aga Khan University Hospital, Karachi.

Abstract

Mixed epithelial and stromal tumour of kidney is a recently described, rare entity and includes cases previously termed as cystic hamartoma of renal pelvis and adult mesoblastic nephroma. We report a case of 36 years old female who presented with a history of recurrent loose stools for 5 years. During ultrasound abdomen, a solid right renal mass was incidentally found in upper pole of right kidney. On gross examination it was a 3.5 cm diameter mass which was microscopically composed of both epithelial and stromal components in the form of cystically dilated tubules and fascicles of spindle shaped cells. These cells stained positive for alpha smooth muscle actin, desmin, progesterone receptors and negative for estrogen receptors.

Introduction

Mixed epithelial and stromal tumour of kidney is a recently described, rare entity and includes cases previously termed as cystic hamartoma of renal pelvis and adult mesoblastic nephroma.¹⁻³ It occurs predominantly in perimenopausal women and men treated with lupron or Diethyl stilbestrol.¹⁻⁴

We hereby report a case of mixed epithelial and stromal tumour of kidney.

Case Report

A 36 years old married woman, presented with a history of recurrent loose stools for 5 years. There was no history of urinary complaints, abdominal pain or low back pain. Obstetric history was unremarkable, but the patient had history of severe dysmenorrhoea and menorrhagia for last ten years. She took oral contraceptive pills occasionally which relieved her symptoms. Drug history and family history were unremarkable. Ultrasound abdomen showed an incidental, solid right renal mass. CT scan abdomen

revealed the mass arising from upper pole of right kidney and compressing second part of duodenum and hepatic flexure. Renal vein and inferior vena cava could not be visualized. Color Doppler for renal vein and inferior vena

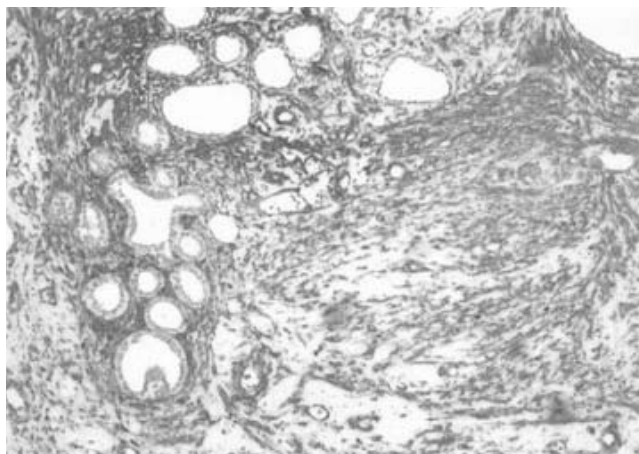


Figure 1. Photomicrograph showing fascicles of benign spindle cell component. H&E stain, Mag 20x

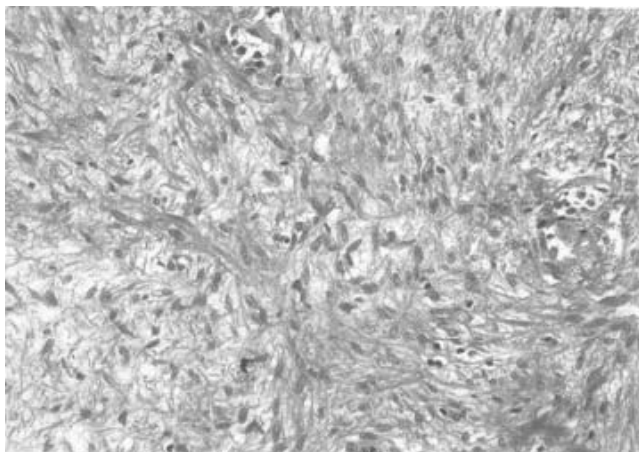


Figure 2. Photomicrograph showing spindle cell component stained with Alpha smooth muscle actin (ASMA) and epithelial component composed of tubules lined by low cuboidal epithelium with cells showing hobnailing. (Mag 20x).

cava showed solid right renal mass measuring 5.5x3x4cm with neovascularization extending outside the renal capsule. No lymph node involvement was seen. She was clinically staged as Stage II a.

Surgery was planned and a right radical nephrectomy was done. Grossly, it was a radical nephrectomy specimen, with kidney measuring 10x6x7 cm and containing a tumour in the upper pole measuring 3.5x3.5x2.8cm. Cut surface was grayish white in color and tumour was almost reaching the capsule. Microscopically it was a biphasic neoplasm composed of both epithelial and stromal components. The stromal component consisted of intersecting fascicles of spindle shaped cells lacking any nuclear atypia. Scanty collagen fibers and numerous dilated thin walled vascular spaces were interspersed in between. Mitotic figures were not identified (Figure 2). Epithelial component was composed of tubular structures lined by cuboidal to low columnar lining epithelium (Figure 1). Few tubules were cystically dilated with eosinophilic secretions in their lumina. No haemorrhage or necrosis was present. Mild lymphoplasmacytic infiltrate was seen interspersed throughout. Tumour was irregularly radiating into adjacent renal parenchyma, and within 1mm from renal capsule. No blastematos elements or any immature epithelial elements were seen.

Immunohistochemical studies showed Desmin and Alpha smooth muscle actin (ASMA) (muscle markers) positive diffusely and strongly in the spindle cells of tumour (Figure 1), while HMB-45 was negative. Tumour cells were positive for progesterone receptors and negative for estrogen receptors. Epithelial component was positive for

Cytokeratin AE1/AE3, EMA and negative for CEA.

Discussion

Mixed epithelial and stromal tumour of kidney is a relatively new entity. Cases previously termed as adult mesoblastic nephroma or cystic hamartoma of the renal pelvis are now referred to as mixed epithelial and stromal tumour of kidney. It has two variants, classic and cellular. It appears unrelated to congenital mesoblastic nephroma, as it lacks genetic alterations i.e. ETV6-NTRK3 gene fusion.⁴ Its predominance in females with a history of long-term estrogen replacement (as is seen in our case) or the history of long-term sex-steroid use in a male patient, combined with the expression of estrogen and progesterone receptors in the spindle cells, suggest that hormonal influence is relevant for the development of these tumours.^{1,5} Follow up of our patient and previous reports suggest that this entity has a benign behavior and recurrence is rare after surgery.^{2,6}

References

1. Adsay NV, Eble JN, Srigley JR, Jones EC, Grignon DJ. Mixed epithelial and stromal tumor of the kidney. *Am J Surg Pathol* 2000;24:958-70.
 2. Mensch LS, Trainer TD, Plante MK. Cystic hamartoma of the renal pelvis: a rare pathologic entity. *Mod Pathol* 1999;12:417-21.
 3. Trillo AA. Adult variant of congenital mesoblastic nephroma. *Arch Pathol Lab Med* 1990;114:533-5.
 4. Pierson CR, Schober MS, Wallis T, Sarkar FH, Sorensen PH, Eble JN, et al. Mixed epithelial and stromal tumor of the kidney lacks the genetic alterations of cellular congenital mesoblastic nephroma. *Hum Pathol* 2001;32:513-20.
 5. Moch H, Schurch LV, Terracciano L. Mixed epithelial and stromal tumor of kidney. *Pathologie* 2004;25:356-61.
 6. Tejido SA, de la Morena G JM, Garcia de la Torre JP, Villacampa AF, Martin MMP, Pamplona CM, et al. Mesoblastic nephroma in the adult: report of a new case. *Arch Esp Urol* 2001;54:265-8.
-