



THE AGA KHAN UNIVERSITY

eCommons@AKU

Department of Pathology and Laboratory Medicine

Medical College, Pakistan

March 1994

Malakoplakia of the uterus

H Shaikh

Aga Khan University, hizbullah.shaikh@aku.edu

P E. Khan

Aga Khan University

N Faridi

Aga Khan University

Follow this and additional works at: https://ecommons.aku.edu/pakistan_fhs_mc_pathol_microbiol

 Part of the [Obstetrics and Gynecology Commons](#), and the [Pathology Commons](#)

Recommended Citation

Shaikh, H., Khan, P. E., Faridi, N. (1994). Malakoplakia of the uterus. *Journal of Pakistan Medical Association*, 44(3), 76-77.

Available at: https://ecommons.aku.edu/pakistan_fhs_mc_pathol_microbiol/1075

Malakoplakia of the Uterus

Pages with reference to book, From 76 To 77

Hizbullah Shaikh, Naveen Faridi (Departments of Pathology, The Aga Khan University Hospital, Karachi.)
Parveen Eva Khan (Departments of Obstetrics and Gynaecology, The Aga Khan University Hospital, Karachi.)

Introduction

Malakoplakia is a rare granulomatous inflammatory disease with a female to male ratio of 2:1¹. A total of 200 cases have been reported in the literature². This entity is currently believed to represent an acquired defect in the lysosomal activity of monocytes³, most commonly occurring in the urinary tract and is associated with a variety of infectious agents, notably gram negative bacilli⁴. E. coli was identified in 7 of 8 available urine cultures out of the 9 cases of genito-urinary malakoplakia in a 25 years experience. Out of the 9 patients in the study, 2 were immune compromised¹. Malakoplakia has been found in almost all parts of the body and cases have been described in association with rectal and prostatic adenocarcinomas, renal transplants, systemic lupus erythematosus, adrenogenital syndrome, a case of pemphigus vulgaris on immunosuppressive therapy and with renal polycystosis.

Radiographically, malakoplakia may simulate other inflammatory processes or even a neoplasm⁵. A variety of therapeutic approaches can be chosen, medical, surgical or a combination. The type of surgical intervention depends mainly on the extent and location of the disease.

Case Report

A 28 year old patient gravida 4, para 2 + 2 gave a history of severe lower abdominal pain and low grade fever on and off since 3 months. She gave no history of menstrual abnormality. Abdominal examination revealed a mass which was firm, non-tender, mobile and appeared to arise from the pelvis measuring approximately a 14 weeks size uterus. On vaginal examination this mass was felt to the left of the uterus and the uterus measured 12 weeks size. A white cell count was raised to $16.2 \times 10^9/L$ of which 73% were neutrophils. Urine culture grew no organisms, serum creatinine was normal. A plain x-ray abdomen and intravenous pyelogram were unremarkable. An ultrasound pelvis revealed a uterus to be $12 \times 9 \times 10$ cm and was pushed to the right side by a mass in the left fornix measuring 7.6×5.5 cm which was centrally solid and peripherally cystic. The patient underwent a laparotomy which revealed what appeared to be a "fibroid" arising from the posterior wall of the uterus and extending up to the uterine cavity. The bowel was adherent to the uterine wall. A specimen from the lesion was sent for frozen section in order to rule out any malignancy. This specimen consisted of a firm red-brown piece of tissue measuring $6.5 \times 5.5 \times 5$ cms. Sections through the tissue revealed a cavity showing soft yellow necrotic material. Frozen sections were reported as benign. Paraffin sections from the tissue revealed mainly myometrial tissue showing moderate chronic inflammation consisting of lymphocytes and plasma cells and large collections of histiocytic cells with granular acidophilic cytoplasm (Figure 1).

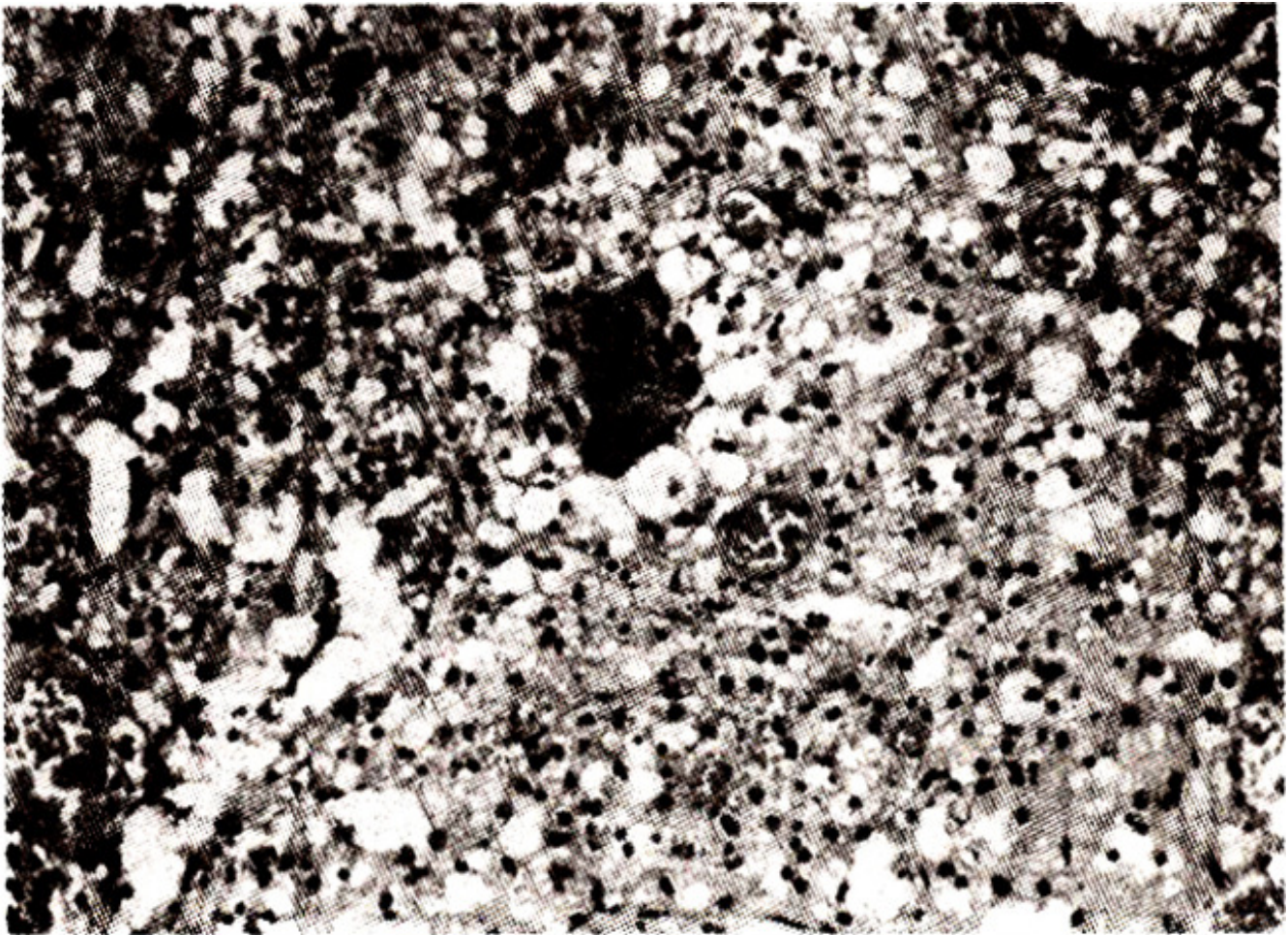


Figure 1. Malakoplakia of the uterus showing foreign body giant cell histiocytic reaction (H & E x 100)

Rounded concentrically layered intra and extra cytoplasmic inclusions (Michaelis Guttman Bodies) were seen that stained positive with periodic acid schiff as well with stains for iron and calcium (Figure 2).

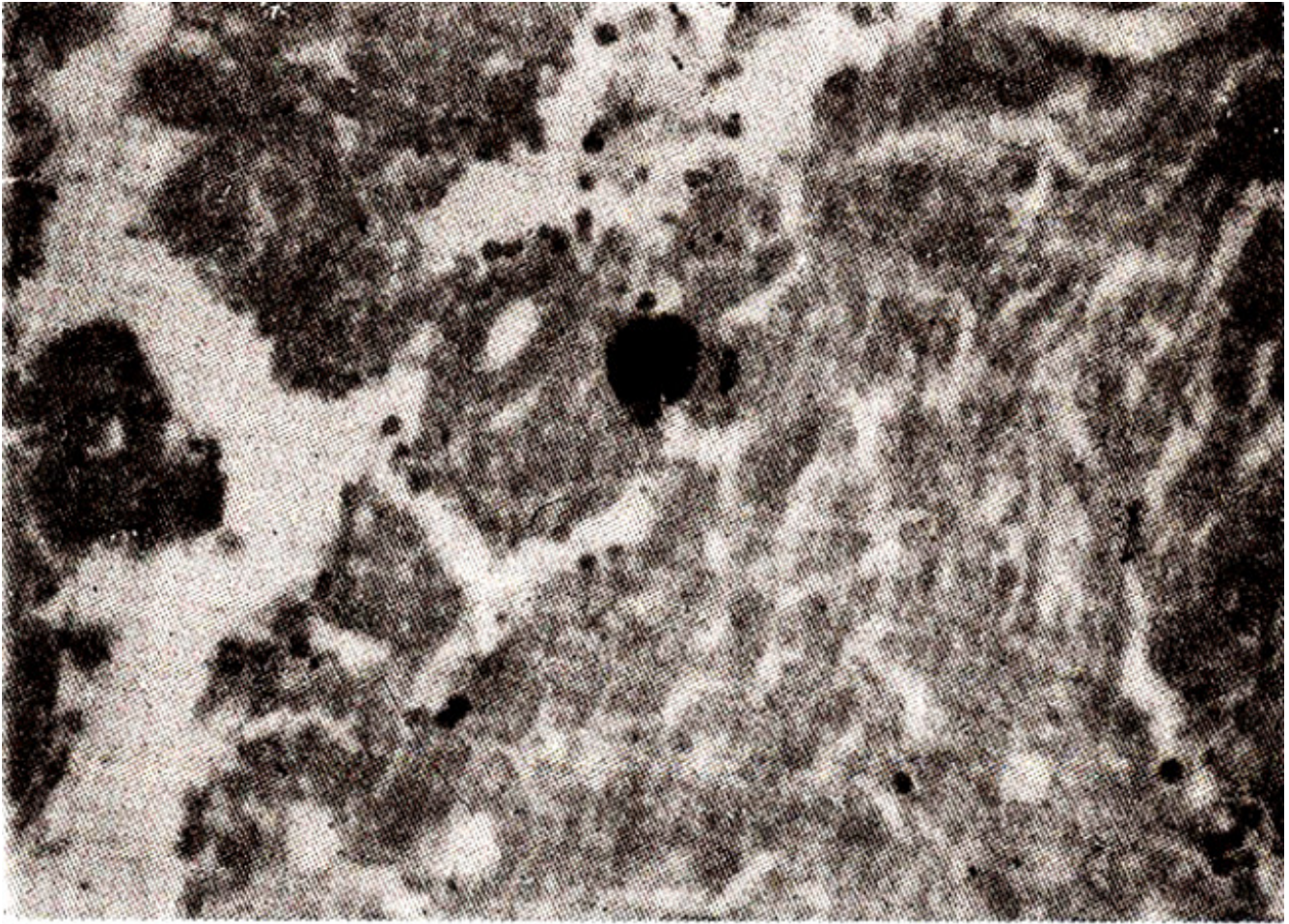


Figure 2. Malakoplakia of the uterus showing Michaelis Guttmann bodies (von Kossa x 200).

There was no evidence of leiomyoma or malignancy. A diagnosis of malakoplakia of the uterus was made. The patient was treated with ciprofloxacin to which she responded well.

Discussion

Malakoplakia per se is a rare entity and with involvement of the uterus being even rarer. The signs and symptoms commonly consist of pain and fever with a mass felt on examination. Microscopically, this disease is characterized by accumulation of macrophages or von I-anseman's cells containing PAS positive and von Kossa positive intra cytoplasmic and extra cytoplasmic inclusions known as Michaelis-Guttmann bodies. These bodies are thought to arise through phagocytosis of bacterial degradation products by the cytosomes⁶ providing a matrix for disposition of needle like crystals resembling hydroxyapatite. The sequence of biologic events leading to malakoplakia have been well summarized by Stanton and Maxted⁷. The treatment of this condition can be with antibiotics, like aminoglycosides, ciprofloxacin, cephalosporins and cotrimoxazole. Recommended treatment for cutaneous malakoplakia is with cotrimoxazole, bethanicol chloride and ascorbic acid⁷.

Acknowledgements

We acknowledge Ms Shazleen Sadruddin for her secretarial assistance.

References

1. Long, J.P. and Alihausen, A.F. Malakoplakia: a 25 year experience with a review of the literature. *J.Urol.*, 1989;141:1328-31.
2. Rach, J.F. and Kandzari, Si. Unusual site for an usual disease, malakoplakia of the prostate. *W.V.Mcdi.*, 1989;85:90-91.
3. Abdon, N.I., Napombejara, C., Sagawa, A. et al. Malakoplakia: evidence for monocyte lysosomal abnormality correctable by cholinergic agonist in vitro and in vivo. *N.Engl.J.Med.*, 1977;297:1413-19.
4. Schwartz, D.A., Ogden, P.O., Blumberg, H.M. and Honig, E., Pulmonary malakoplakia in a patient with acquired immuno- deficiency syndrome, differential diagnostic consideration. *Arch. Pathol. Lab. Med.*, 1990;114:1267-72.
5. Baumgartner, BR. and Alagappian, R. Malakoplakia of the ureter and bladder. *Urol. Radiol.*, 1990;12:157-59.
6. Kerr, .L.F.R., Gaffncy, T.J., McGeary, H.M. et aL Malakoplakia: an electron-microscope and chemical study. *J.Pathol.*, 1972;107:289-94.
7. Stanton, Mi. and Maxted, W. Malakoplakia: a study of the literature anc current concepts of pathogenesis, diagnosis and treatment. *J.Urol.*, 1981;125:139-46.