



THE AGA KHAN UNIVERSITY

eCommons@AKU

---

Department of Radiology

Medical College, Pakistan

---

September 2002

## View box case--9 Bronchiectasis

I Masroor

*Aga Khan University*, [imrana.masroor@aku.edu](mailto:imrana.masroor@aku.edu)

R Hashmi

Follow this and additional works at: [https://ecommons.aku.edu/pakistan\\_fhs\\_mc\\_radiol](https://ecommons.aku.edu/pakistan_fhs_mc_radiol)



Part of the [Radiology Commons](#)

---

### Recommended Citation

Masroor, I., Hashmi, R. (2002). View box case--9 Bronchiectasis. *Journal of Pakistan Medical Association*, 52(9), 435-436.

**Available at:** [https://ecommons.aku.edu/pakistan\\_fhs\\_mc\\_radiol/296](https://ecommons.aku.edu/pakistan_fhs_mc_radiol/296)

## View Box Case - 9

I. Masroor, R. Hashmi ( Radiology Department, Aga Khan University Hospital, Karachi. )

A 65 year old male presented with complaints of high grade fever and cough associated with expectoration of foul smelling sputum off and on for 3 years. He was a heavy smoker. Laboratory investigation showed a raised WBC count and ESR. Chest x-ray showed loss of volume in left hemithorax with multiple ring like lucencies, the right lung was unremarkable (Figure).

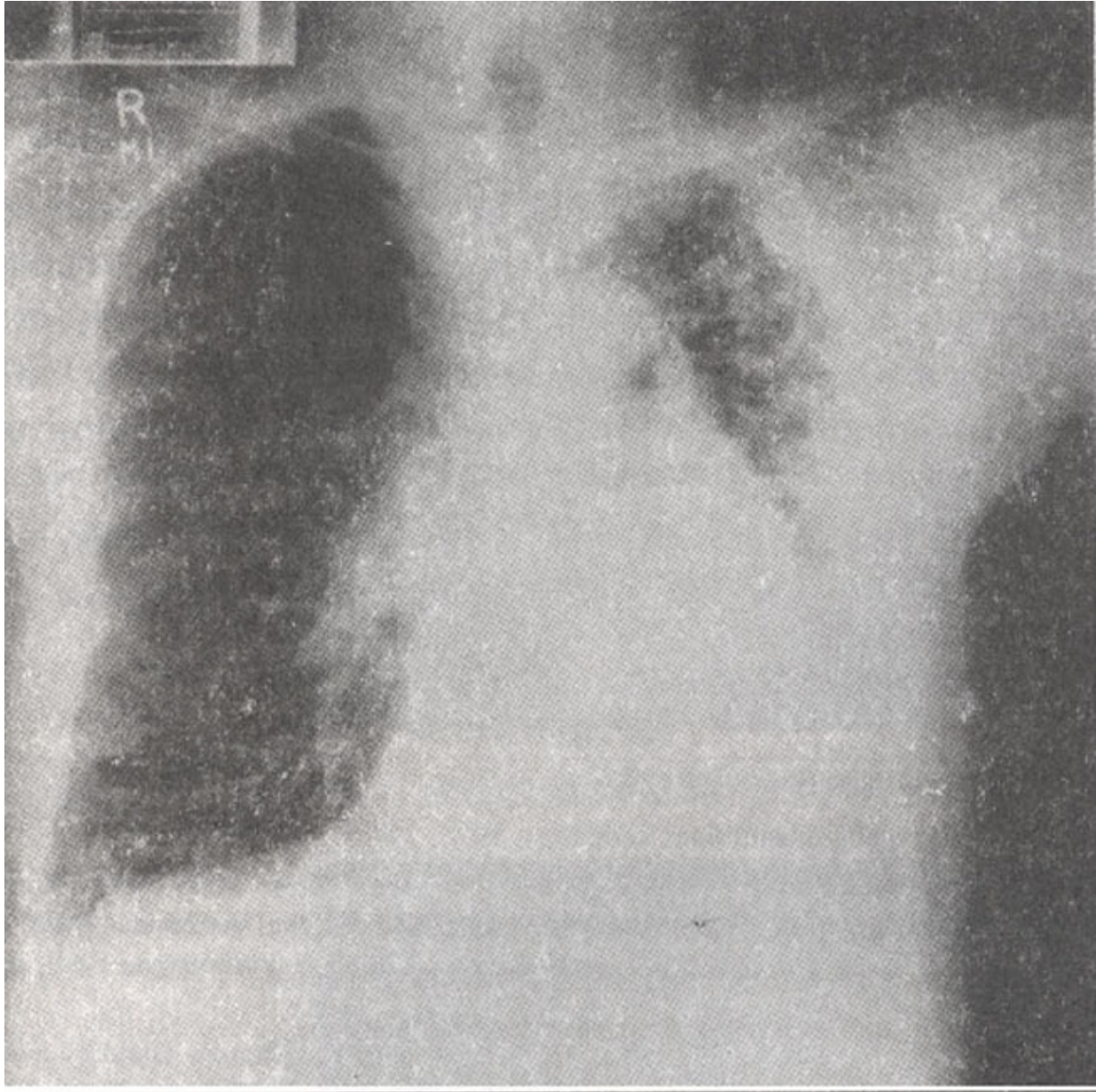


Figure. PA view of chest.

**Diagnosis:** Bronchiectasis left lung.

## Discussion

Bronchiectasis is defined as abnormal and permanent dilatation and distortion of medium sized bronchi, usually accompanied by destruction of the airway wall<sup>1</sup>. Symptoms primarily are chronic cough and expectoration of foul smelling<sup>1</sup>. Bronchiectasis is not a single disease entity but the result of infection and associated atelectasis, which are responsible for the destruction and dilatation of bronchial walls. There are several etiologies of bronchiectasis, including the following: post-infectious etiologies, of which the majority are a complication of measles, whooping cough, or some other contagious disease of childhood; congenital defects of a structural nature in which there is a defect in the structure that support the bronchi, abnormal mucociliary transport responsible for repeated infection; congenital or acquired deficiencies in host defense that have led to repeated pneumonias, bronchial obstruction by neoplasm's, inflammatory nodes or foreign bodies with resultant postobstructive pneumonia and chronic granulomatous infection, especially tuberculosis. It has also been reported in patients with AIDS<sup>2</sup> and as late complication of inhaled fumes and gases or following aspiration of gastric contents. Bronchiectasis is classified in to three groups depending on the severity of bronchial dilatation. This classification was derived from the analysis of bronchograms and corresponding pathological specimens of bronchiectasis. In cylindrical bronchiectasis, the bronchi show a regular out line, with no great increase in diameter, and end squarely and abruptly. Smaller bronchi and bronchioles are plugged with mucus. As a result, cylindrical bronchiectasis has a "striped" appearance on bronchography. The bronchi are straight, and the finer bronchi and bronchioles do not fill with Lipiodol.

In the varicose form, the degree of bronchial dilatation is somewhat greater than in the cylindrical form. There are local constrictions in the bronchi resulting in an irregular out line that resembles that of varicose veins. An irregular outline and a bulbous termination are the cardinal feature on bronchography. Saccular or cystic bronchiectasis, in which the bronchi have a ballooned outline and in which the bronchial dilatation increases progressively toward the periphery of the lung, is the most severe form.

It is unusual for a patient with bronchiectasis to have a strictly normal chest radiograph. Serial radiographs allow identification of patients with progressive disease and indicate the need to review management strategy<sup>3</sup>. The typical radiographic changes include an increase in the size and loss of definition of the lung markings in certain segments of the lungs, which correspond to peribronchial fibrosis and retained secretions. Crowded lung markings are seen as a result of associated atelectasis. In more severe cases, cystic spaces up to 2 cm in diameter, corresponding to dilated bronchi, can be seen with or with out air-fluid levels. In most severe cases, a "honeycomb" pattern is seen, which consists of lucent areas representing emphysematous spaces surrounded by fibrosis. In advanced disease, atelectasis may be complete, with total airlessness of a lobe. Pleural thickening may be present radiographically but is seen much more commonly at thoracotomy. Bronchography was, until recently, the investigation of choice for the diagnosis of bronchiectasis. However currently HRCT (high resolution computed tomography) has completely replaced bronchography.

Treatment is aimed at the non-progression of disease and complete cure if possible. The role of surgical therapy has evolved from early curative resection for all patients to a more palliative approach. Patients with advanced generalized bronchiectasis should be considered for lung transplantation<sup>1</sup>.

## References

- 1.Sethi GR, Batre V. Bronchiactasis: causes and management. Indian J. Pediatr., 2000;67: 133-39.
- 2.King MA, Neal DE, St. John R. Bronchial dilatation in patients with HIV infection. CT assessment and correlation with pulmonary function test at bronchoalveolar lavage. AiR., 1997;1 68:1535-40.
- 3.Munro NC, Han LY, Currie, Respir. Med., 1992;86:397-401.