



THE AGA KHAN UNIVERSITY

eCommons@AKU

Department of Radiology

Medical College, Pakistan

February 2002

## View box case--2 Mid-colic intussusception

I Masroor

*Aga Khan University*, [imrana.masroor@aku.edu](mailto:imrana.masroor@aku.edu)

R Hashmi

Follow this and additional works at: [https://ecommons.aku.edu/pakistan\\_fhs\\_mc\\_radiol](https://ecommons.aku.edu/pakistan_fhs_mc_radiol)



Part of the [Radiology Commons](#)

### Recommended Citation

Masroor, I., Hashmi, R. (2002). View box case--2 Mid-colic intussusception. *Journal of Pakistan Medical Association*, 52(2), 85-87.

**Available at:** [https://ecommons.aku.edu/pakistan\\_fhs\\_mc\\_radiol/290](https://ecommons.aku.edu/pakistan_fhs_mc_radiol/290)

## **View Box Case - 2**

I. Masroor, R. Hashmi ( Department of Radiology, Aga Khan University Hospital, Karachi. )

A one year and seven month old child presented with complaints of abdominal pain, vomiting and bloody stools (current jelly) for 15 hours. On examination he was irritable and screaming intermittently and pulling his legs up followed by being pale and limp. A firm, mobile mass was palpable in mid abdomen. On rectal examination there was blood and mucous on the glove. The laboratory investigations were normal. Plain x-ray of the abdomen showed multiple dilated loops of bowel with air fluids levels on erect film suggesting an obstructive pattern; however no mass was seen. A single contrast barium enema was performed which showed a typical “claw hand” filling defect in the middle of transverse colon suggesting intussusception (Figure).

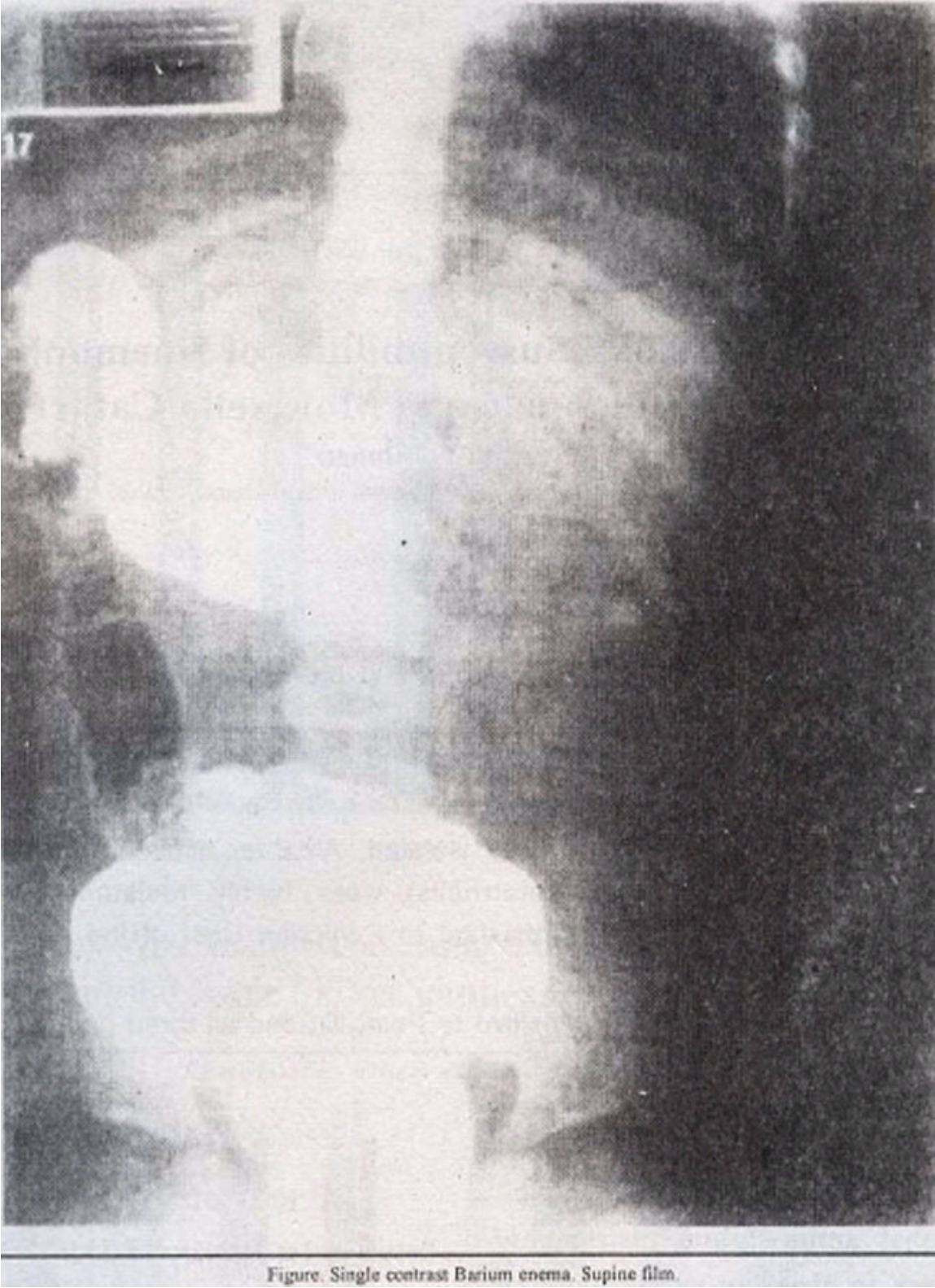


Figure. Single contrast Barium enema. Supine film.

This was successfully reduced by applying pressure with barium column with free flow of contrast into the terminal ileum.

**Diagnosis:** Mid-colic Intussusception

## Discussion

Intussusception is defined as the invagination of one bowel segment into another (telescoping into a distal segment)<sup>1</sup>. This leads to obstruction of venous and lymphatic flow. If the obstruction is not reduced, there will be mesenteric artery obstruction. Intussusception commonly presents between 5-9 months of age. It is twice as frequent in males than females; 90% cases are idiopathic, 10% involve a discrete lead point. Common lead points include Meckels diverticulum, intestinal polyps, appendicitis, neoplastic lesions and foreign bodies. Lymphoid hyperplasia is found in idiopathic cases. Eighty percent of intussusceptions are iliocolic. Commonest mode of presentation is intermittent abdominal pain manifested in an infant by drawing knees to chest with crying followed by pain free periods. Vomiting, stools mixed with blood and mucous (current jelly stool), shock and fever are associated features. Plain film, of abdomen may show a mass anywhere in the abdomen with an obstructive pattern, or it may be normal. Ultrasound of the abdomen is often the first test of choice<sup>2</sup>. Sensitivity is almost 100%<sup>1</sup>. A positive test will demonstrate a doughnut or onionskin pattern. Barium enema has both diagnostic as well as therapeutic potentials<sup>2</sup>. Diagnosis is made on finding typical claw hand or spring coiled appearance in the head of barium column. Reduction of Intussusception is performed by applying pressure with barium column, which is effective in 80% of cases in hands of experienced radiologists<sup>3</sup>. There is 10% recurrence rate. Parents are explained of symptoms to watch for and if there is recurrence, barium enema may be tried again. After multiple recurrences, surgery may be done to find a specific lead point or resect some portion of bowel. Operative reduction is needed if barium reduction fails or there is contraindication to barium enema. Contraindications include perforation of bowel, peritonitis and prolonged obstruction. Complications include perforation with infection.

## References

1. Winslow BT, Westfall JM, Nicholas RA. Intussusception, American Family Physician, 1996; 54: 213-217.
2. Lam AH, Firman K. Value of sonography including color Doppler in the diagnosis and management of long standing intussusception. *Pediatr. Radiology*, 1992; 22: 112-114.
3. Poznanski AK. Why I still use barium for intussusception. *Pediatr. Radiology*, 1995; 25: 92-93.