



THE AGA KHAN UNIVERSITY

eCommons@AKU

Department of Radiology

Medical College, Pakistan

September 1993

# Phyllocontin (theophylline) induced esophagitis

Y M. Shaikh

*Aga Khan University*

A H. Khan

*Aga Khan University*

N Rao

*Aga Khan University*

I H. Rizvi

*Aga Khan University*

T A. Hameed

*Aga Khan University*

*See next page for additional authors*

Follow this and additional works at: [https://ecommons.aku.edu/pakistan\\_fhs\\_mc\\_radiol](https://ecommons.aku.edu/pakistan_fhs_mc_radiol)

 Part of the [Radiology Commons](#)

## Recommended Citation

Shaikh, Y. M., Khan, A. H., Rao, N., Rizvi, I. H., Hameed, T. A., Rana, T. A. (1993). Phyllocontin (theophylline) induced esophagitis. *Journal of Pakistan Medical Association*, 43(9), 183.

**Available at:** [https://ecommons.aku.edu/pakistan\\_fhs\\_mc\\_radiol/242](https://ecommons.aku.edu/pakistan_fhs_mc_radiol/242)

---

**Authors**

Y M. Shaikh, A H. Khan, N Rao, I H. Rizvi, T A. Hameed, and T A. Rana

# Phylloconfin (Theophylline) induced Esophagitis

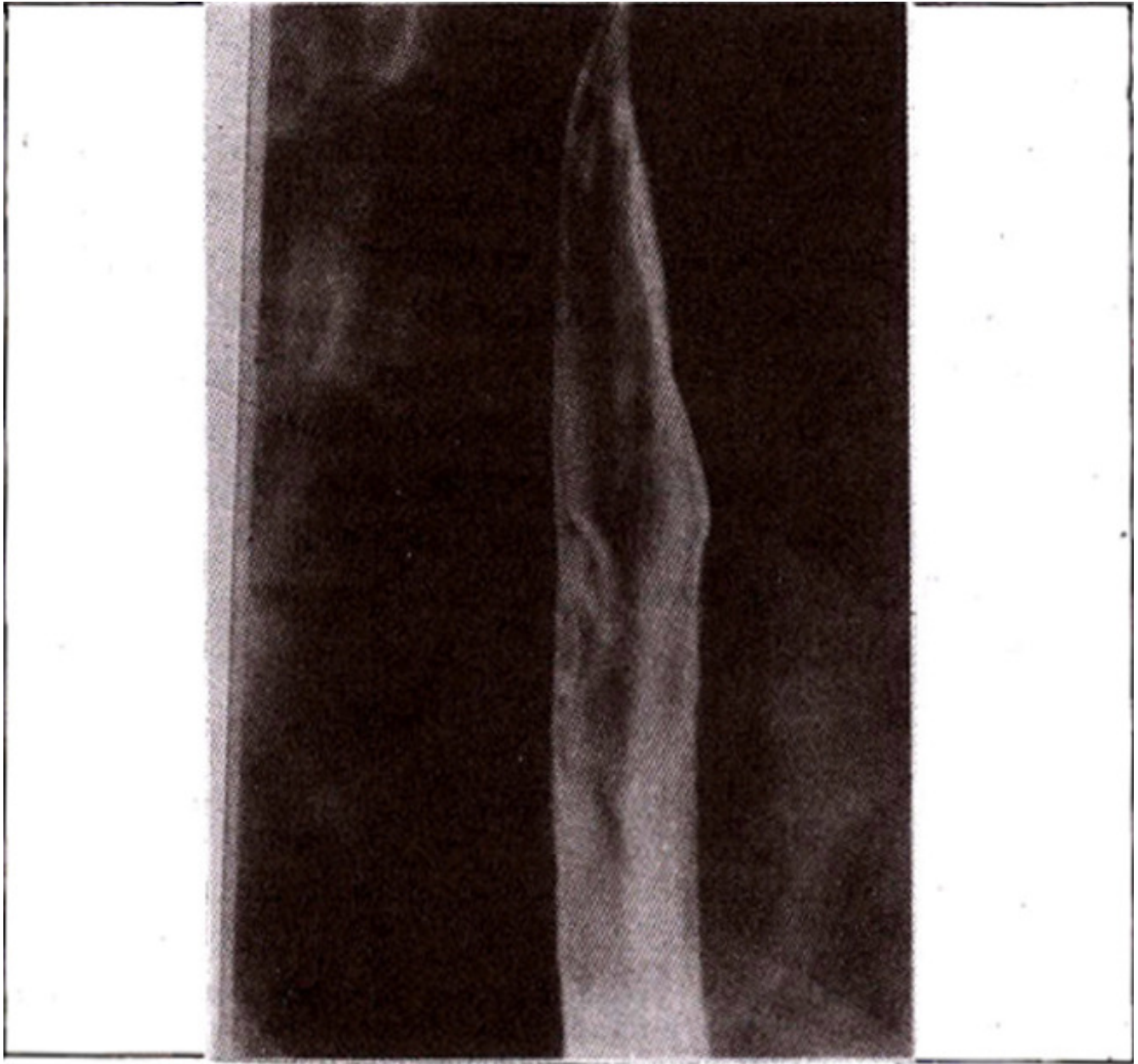
Pages with reference to book, From 183 To 183

Younus M. Shaikh, A. Haleem Khan, I. Hussain Rizvi, Tariq A. Hameed, Tauqir A. Rana ( Department of Radiology, The Aga Khan University Hospital, Stadium Road, Karachi. )  
Najmussaqqib Rao ( Department of Medicine, The Aga Khan University Hospital, Stadium Road, Karachi. )

Drug ingestion esophagitis has been a well documented phenomenon<sup>1-4</sup>. A large number of drugs have been implicated, both in solid and liquid forms. The inflammatory process ranges from shallow ulceration to fibrosis and stricture formation<sup>3</sup>. A case of phyllocontin-induced acute esophagitis is presented with radiologic/endoscopic correlation. The only other case on record occurred due to ingestion of theophylline without water<sup>5</sup>.

## Case Report

A 28 years old male presented with pain and difficulty in swallowing solids for the past ten days. He was a known asthmatic taking phyllocontin and ventide inhaler. He stopped taking phyllocontin after the onset of present symptoms. He was a non-smoker and non-alcoholic and denied aspirin ingestion. He also denied ever taking tablets without water. Double contrast examination showed irregular and slightly serrated ulcerative lesions on opposing surfaces of the right and left walls of the esophagus at the subcarinal level. The right sided lesion measured 2 cm in length. The other measured 1 cm (Figure).



**Figure. Double contrast view of the esophagus showing ulcer along the right lateral wall.**

Endoscopy showed, at 32 cm. from the incisor teeth, two ulcerated areas, one 1.5 and the other 0.5 cm in length on opposite walls of the esophagus. Rest of the esophageal mucosa looked normal. Stomach and duodenum were nonnal. The ulcers healed on their own in 4 weeks as confirmed on subsequent endoscopy.

### **Discussion**

Various mechanisms have been described for ulcer formation in the esophagus due to ingested drugs<sup>2,3</sup>. A variety of drugs like tetracycline, ferrous sulphate, ascorbic acid, quinidine, potassium chloride and emerpronium have been implicated. Theophylline is known to cause increased gastric acid output and increased incidence of gastroesophageal reflux<sup>5</sup>. However, in our case the ulcers were higher up than would be expected due to reflux esophagitis alone. These were discrete lesions at about mid esophagus

with a totally normal mucosa distally and proximally, both by barium swallow and endoscopic evaluation. Ulcers on the opposite walls and at the same level can be termed "Kissing Ulcers" and must alert the radiologist to the possibility of drug induced esophagitis. Hence it is postulated that theophylline may cause ulceration by direct chemolysis of the mucosal covering of the esophagus.

## References

1. Enzenauer, R. W., Baa,, J.W., McDonnel, J.T. Esopohageal ulceration associated with oral theophylline (letter to editor). N. Engl.J. Med., 1984;310:261.
2. Teplick, 3.0., Teplick, S.K., Ominaky, 5.H., Haskin, ME. Eaophagitis caused by oral medication. Radiology 1980;134:23-25.
3. Creteur, V., Laufer, I., Kressel, H.Y. et al. Drug-induced eaophagitis detected by double-contrast radiography. Radiology, 1983; 147: 365-68.
4. Bova, 3.0., Dutton, N.E., Goldstein, H.M. and l-loberman, Li. MedicatIon induced esophagitis; diagnoais by doublecontrast esophography. A.J.R., 1987;148:731-32.
5. Bengtason, U., Sandberg, N., Bake, B. et al Gaatro-oeaophageal reflux and night-time aathma. Lancet, 1985;1:1501-02.