



THE AGA KHAN UNIVERSITY

eCommons@AKU

Department of Radiology

Medical College, Pakistan

March 1997

# Percutaneous removal of biliary stone from anomalous right hepatic duct

T ul Haq

*Aga Khan University*, [tanveer.haq@aku.edu](mailto:tanveer.haq@aku.edu)

M Y. Sheikh

C K. Jadun

M N. Ahmad

*Aga Khan University*, [nadeem.ahmed@aku.edu](mailto:nadeem.ahmed@aku.edu)

Y H. Husen

Follow this and additional works at: [https://ecommons.aku.edu/pakistan\\_fhs\\_mc\\_radiol](https://ecommons.aku.edu/pakistan_fhs_mc_radiol)



Part of the [Radiology Commons](#)

## Recommended Citation

ul Haq, T., Sheikh, M. Y., Jadun, C. K., Ahmad, M. N., Husen, Y. H. (1997). Percutaneous removal of biliary stone from anomalous right hepatic duct. *Journal of Pakistan Medical Association*, 47(3), 94-96.

**Available at:** [https://ecommons.aku.edu/pakistan\\_fhs\\_mc\\_radiol/235](https://ecommons.aku.edu/pakistan_fhs_mc_radiol/235)

# Percutaneous Removal of Biliary Stone from Anomalous Right Hepatic Duct

Pages with reference to book, From 94 To 96

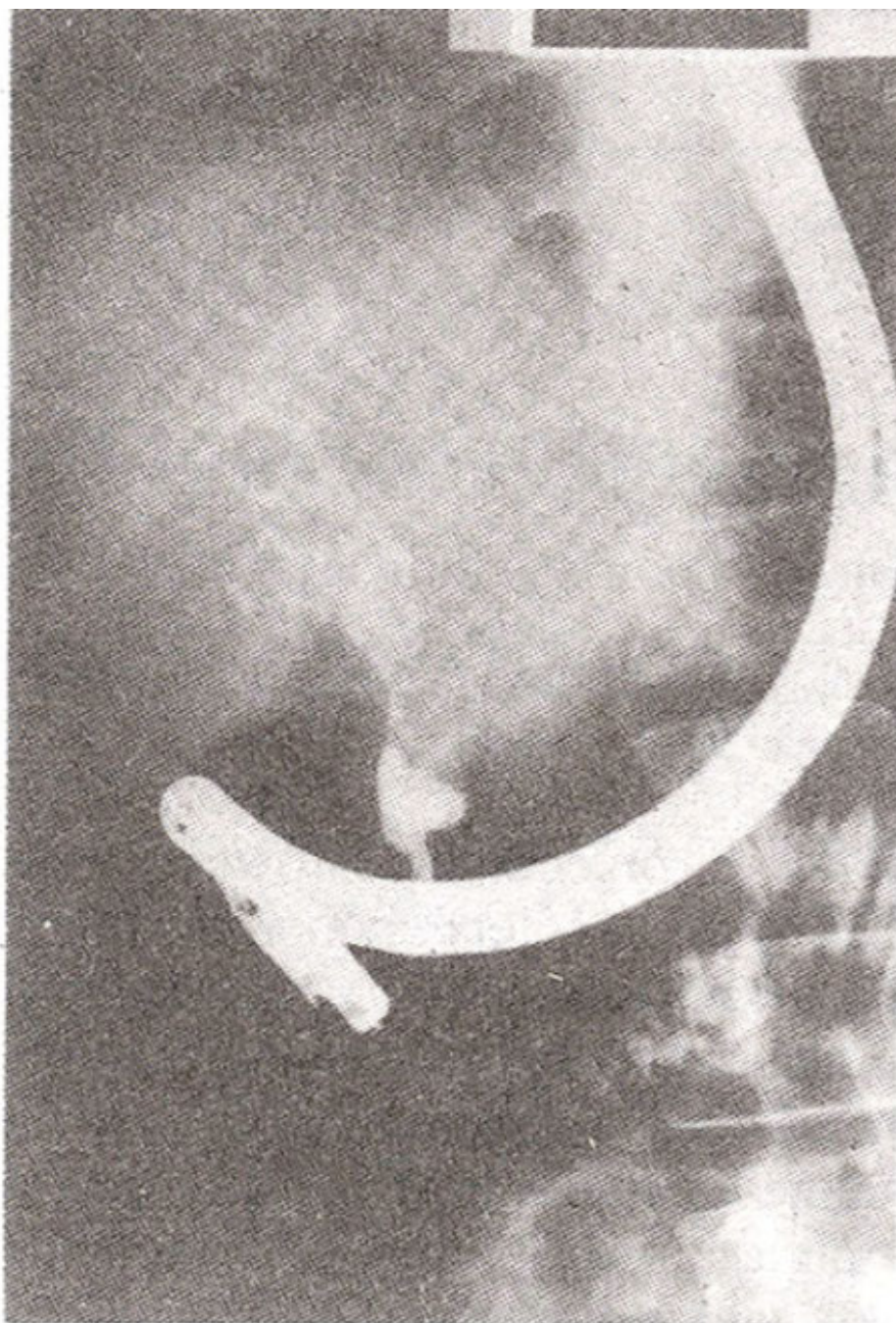
Tanveer ul Haq, Mohammed Younus Sheikh, Changes Khan Jadun, M.N. Ahmad, Yousuf H. Husen ( Department of Radiology, Aga Khan University Hospital, Stadium Road, Karachi. )

## Introduction

Intrahepatic biliary stone formation is prevalent in East Asia and there is a high frequency of retained intrahepatic stones after surgical treatment. The etiological factors include oriental cholangiohepatitis<sup>1,2</sup>, parasitic infections and bile stasis<sup>3</sup>. If the disease is isolated to one lobe or hepatic segment, surgical resection may be curative but when the disease is extensive, operative management includes a variety of complex drainage procedures. However, even after the biliary-enteric bypass surgery, symptoms often persist from residual stones and infection. Transcatheter interventional radiological techniques have been increasingly used in the management of a wide spectrum of biliary tract disorders. While percutaneous removal of common bile duct stones is relatively straightforward, removal of intrahepatic stones is more complex and requires variable techniques. A case is presented here with anomalous insertion of right posterior intrahepatic duct into the cystic duct and having retained calculus. Percutaneous retrieval of stone was made possible by special technique described below.

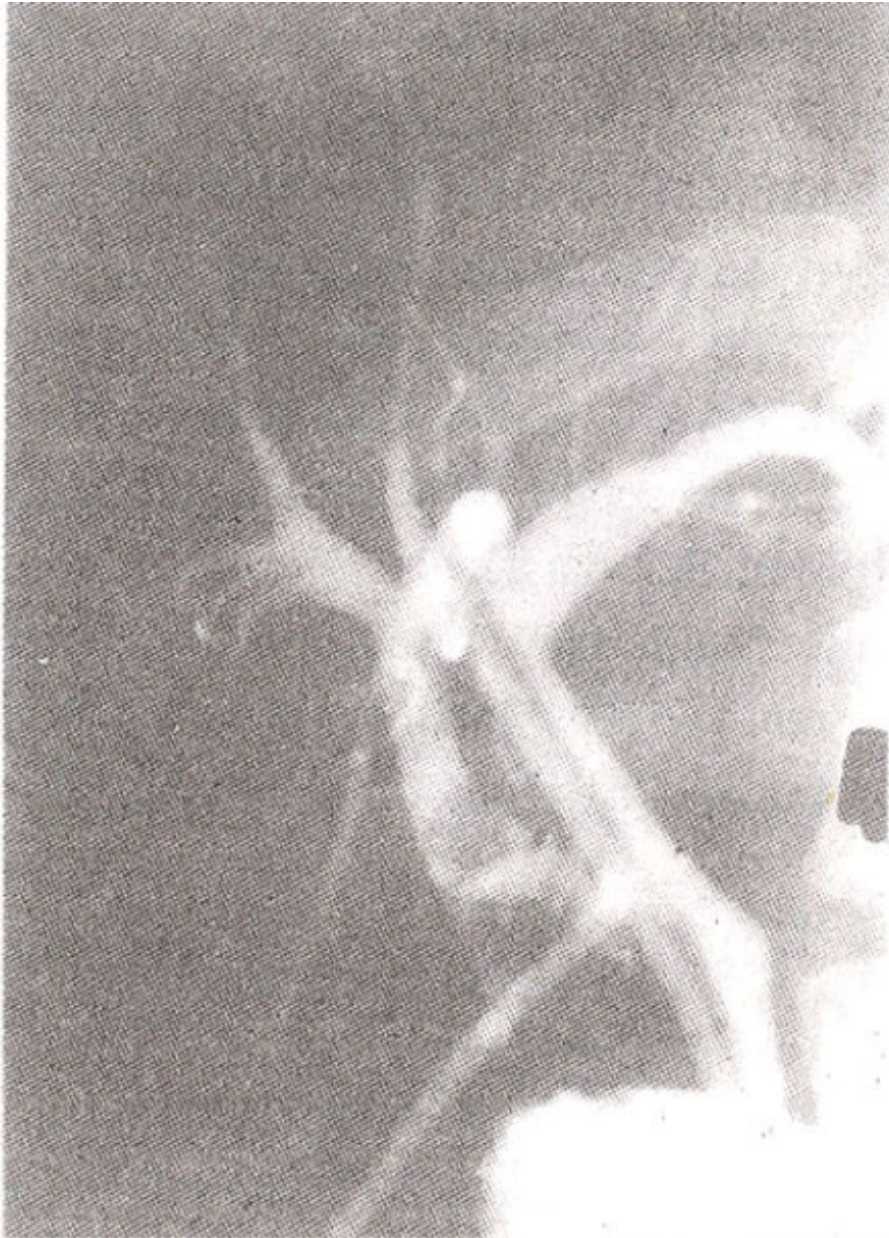
## Case Report

A 44 years old female was admitted with right upper quadrant discomfort and fluctuating jaundice since her cholecystectomy about a year back. Ultrasound showed common bile duct (CBD) stones, confirmed by endoscopic retrograde cholangiopancreatogram (ERCP) one month earlier. Most CBD stones were removed at ERCP, but some stones were also found in the main intrahepatic ducts (Figure 1).



**Figure 1. Multiple calculi filling up extra and main intrahepatic biliary ducts.**

This time the patient was admitted for planned surgery which was performed with exploration of CBD and choledochoscopy to remove intra and extra hepatic biliary stones. Peroperative cholangiogram revealed clearance of CBD but there was inadequate filling of intrahepatic ducts. Tube cholangiogram done two weeks later showed retained stone of about 1 cm size in anomalous right hepatic duct opening into the cystic duct (Figure 2).



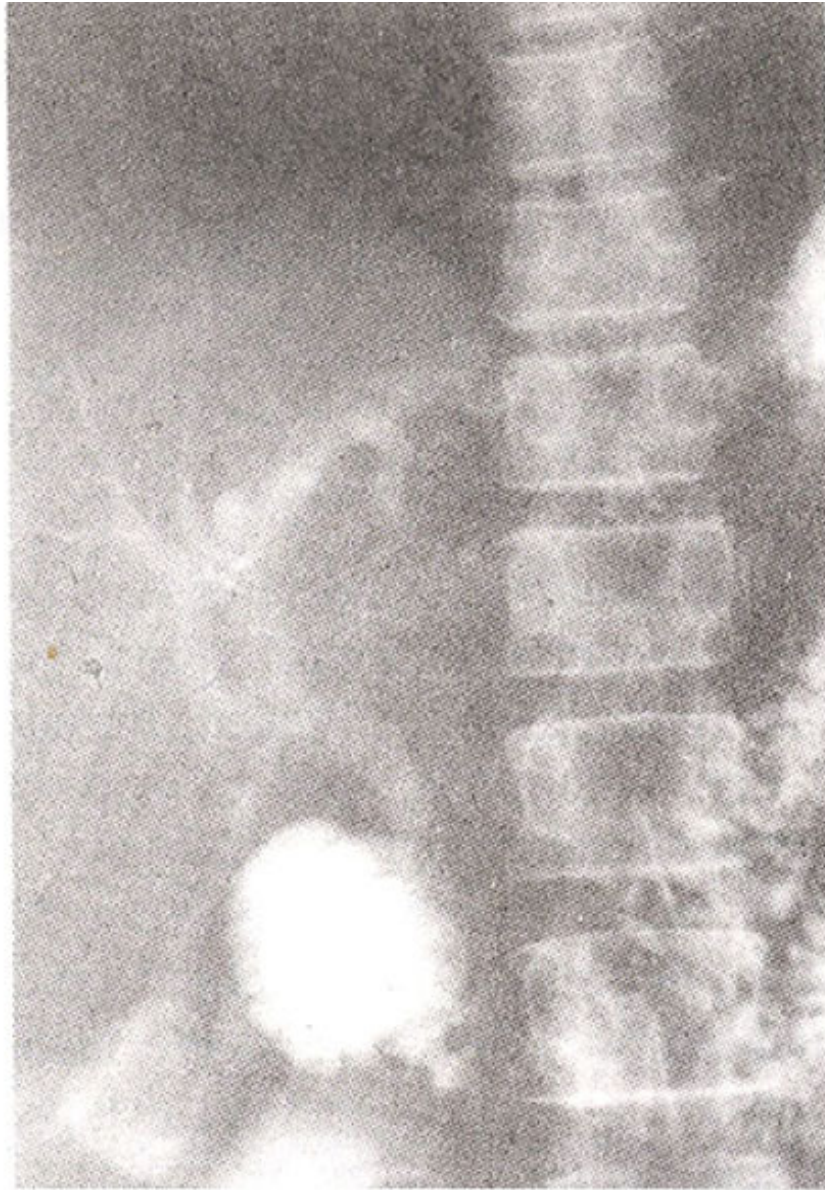
**Figure 2. Anomalous right posterior hepatic duct opening into the cystic duct and containing a calculus.**

Rest of the intra and extra hepatic ducts were clear. Patient was recalled after a month for stone extraction through the T-tube track. Procedure was done under fluoroscopy with all aseptic precautions and antibiotic coverage. Patient was given anxiolytic and analgesic before and during the procedure. T-tube was removed and Dormia basket was taken into the anomalous duct through the cystic duct. The anomalous communication was narrow and failed to give way to the stone. Dormia basket was removed and specially curved 5.5F angiographic catheter was then taken into the anomalous duct with the help of a guide wire. Patient was placed in left lateral position and the stone flushed with normal saline. Stone moved into the left hepatic duct with this maneuver. The catheter was then taken into the left hepatic duct beyond the stone through the common hepatic duct. Patient was made to sit upright. Flushing through catheter moved the stone into the common hepatic duct (Figure 3)

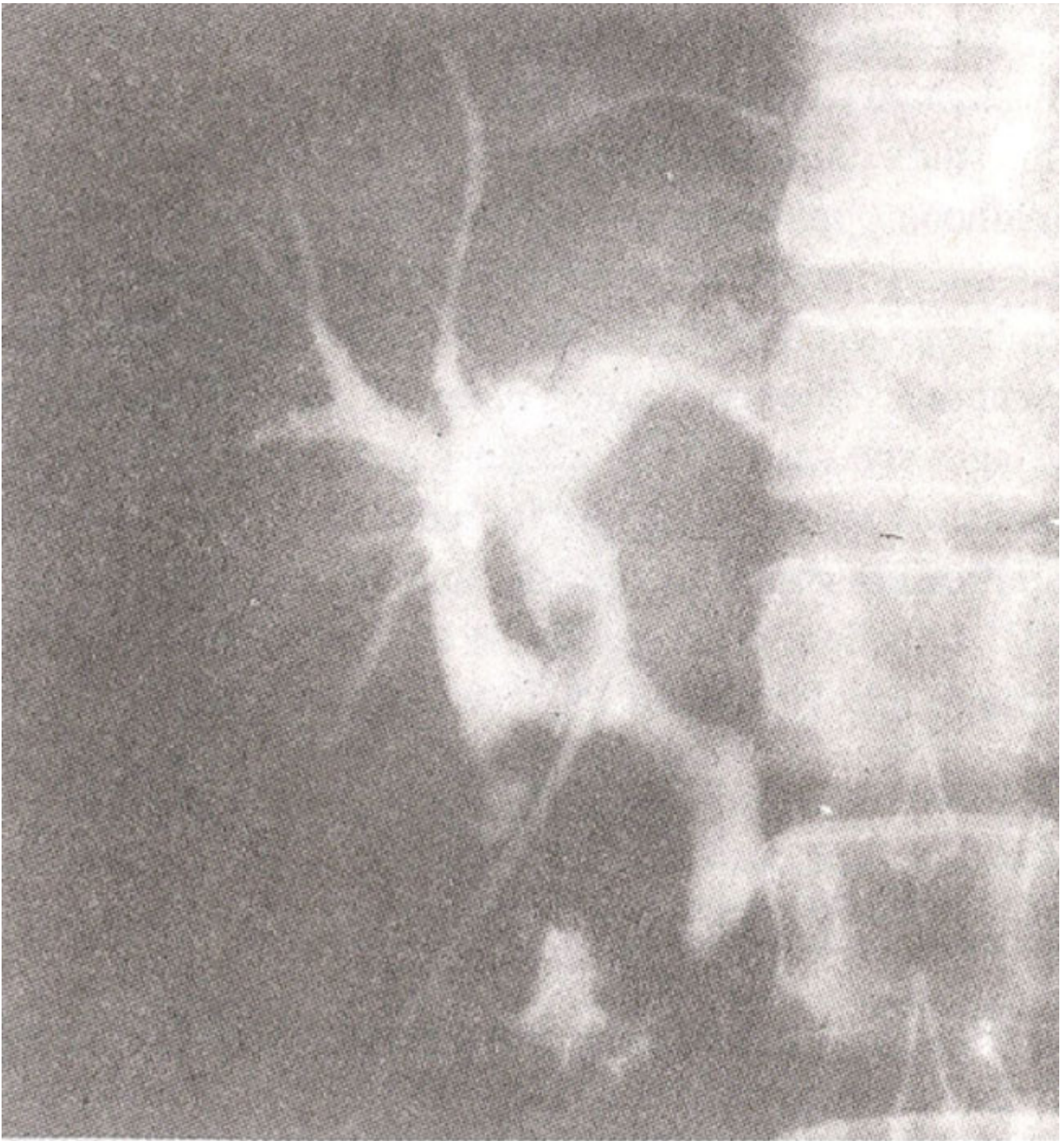

Figure 3. Calculus has moved into the common hepatic duct.

from where it was easily retrieved with the dormia basket with the patient in supine position. Cholangiogram following procedure did not reveal any retained stone in the intra and extra hepatic ducts (Figure 4).



**Figure 4. Calculus has removed and cholangiogram did not reveal any residual filling reflect.**

Follow up till one month was uneventful.

### **Discussion**

The pathogenesis of the intrahepatic stones could be attributed to gallbladder stones that have migrated upwards. The condition being rare in western countries with some incidence in Asian immigrants, has been found with increasing frequency in east Asia<sup>4-6</sup>. Oriental cholangiohepatitis being the commonest cause in these countries. Frequently no gallstone found at surgery suggests the intrahepatic origin of the stones. In our case the cause was not obvious, however gallstones were present at the time of surgery. The case was peculiar, since the stone had to be removed from anomalous right hepatic duct. Modifications in usual technique and use of angiographic catheters had made the stone extraction possible. Reported incidence of bile duct variations is 10-31%<sup>7,8</sup>. Most common biliary ductal anomaly is an anomalous right hepatic duct emptying into the common hepatic duct or cystic duct. Puente and

Bannura<sup>7</sup> reported a prevalence of 4-5% of anomalous right hepatic duct. Koga et al<sup>9</sup>, have shown no association of hepatolithiasis with anatomic variations of main intrahepatic biliary ducts. Presence of multiple stones in gallbladder and extra hepatic ducts in our case indicates other cause of stone formation like recurrent pyogenic cholangitis and anomalous duct is just a co-incidence. Cholecystectomy and choledochostomy with intrahepatic stone extraction are usually performed but are not successful in removing all the intrahepatic stones. Several other surgical procedures are also not successful and the ultimate cure rate by surgery is relatively low, except after segmentectomy or lobectomy for the localized disease. Thus, there is still a high likelihood of residual intrahepatic stones post-operatively. Non-surgical techniques are considered to be most appropriate for removal of residual intrahepatic stones. The various options are: extraction through T-tube track, ERCP with sphincterotomy, flexible choledochoscopy and lithotripsy. Percutaneous removal through a T-tube track with a stone basket shows excellent results mostly for CBD stones<sup>9</sup>, with intrahepatic stones, however, there have been few reports of experience<sup>10</sup>. Park et al had a 67% success of removing intrahepatic stones via T-tube track<sup>11</sup>. In conclusion hepatolithiasis is a rare disease and percutaneous access in removing these stones is simple with high success rate and less morbidity and mortality. Removal of stones from anomalous intrahepatic ducts can also be possible when special maneuver and curved or steerable tips catheters are used.

## References

1. Wastie, M.L. and Cunningham L.G.E. Roentgenological findings in recurrent pyogenic cholangitis. *AIR.*, 1973;119:71-77.
2. Federle, M.P., Cello, J.R., Laing, F.C. et al Recurrent pyogenic cholangitis in Asian Immigrants. *Radiology*, 1982; 143:151-156.
3. Nakayama, F. Intrahepatic calculi. A special problem in East Asia. *World J. Surg.*, 1982;6:802-805.
4. Nakayama, F., Furusawa, T. and Nakama, T. Hepatolithiasis in Japan: Present status. *Am.J. Surg.*, 1980;139:216-220.
5. Kwon, O.J., Park, Y.H. and Kim, J.R. A clinical study of cholelithiasis. *J. Korean Surg. Soc.*, 1982;24:1052-1058.
6. Ker, C.G., Lee, K.J., Huang, T.J. et al. Intrahepatic gallstones in Taiwan. *Southeast Asian J. Surg.*, 1986;9:42-46.
7. Puente, S.G. and Bannura, C.C. Radiological anatomy of biliary tract: Variations and congenital abnormalities. *World J. Surg.*, 1983;7:271-276.
8. Hamlin, J.A. Biliary ductal anomalies, in *operative biliary radiology* Ed Berci, G. Baltimore, Williams and Wilkins, 1981, pp. 110-116.
9. Koga, A., Watanabe, S., Takiguchi, S. et al. Etiological significance of anatomic variations in the main intrahepatic bile ducts in hepatolithiasis. *Acts Radiol.*, 1987;28:285-288.
10. Van-Sonnenberg, E., Casola, C., Cubberley, D.A. et al Oriental cholangiohepatitis. Diagnostic imaging and interventional management. *AIR.*, 1986;146:327-331
11. Park, J.H., Choi, H.I., Han, M.C. et al Percutaneous removal of residual intrahepatic stones. *Radiology*, 1987; 163:619-623.