



THE AGA KHAN UNIVERSITY

eCommons@AKU

Department of Radiology

Medical College, Pakistan

January 2004

Oral contrast-enhanced CT cholangiography--an initial experience

I Naseem

J Rees

Follow this and additional works at: https://ecommons.aku.edu/pakistan_fhs_mc_radiol



Part of the [Radiology Commons](#)

Recommended Citation

Naseem, I., Rees, J. (2004). Oral contrast-enhanced CT cholangiography--an initial experience. *Journal of Pakistan Medical Association*, 54(1), 623-624.

Available at: https://ecommons.aku.edu/pakistan_fhs_mc_radiol/228

CASE REPORT

OMENTAL INFARCTION IN A CHILD

Saad Siddiqui, Anwar Ahmed, Naila Nadeem

Department of Radiology, Aga Khan University, Karachi-Pakistan

Omental infarction is a rare cause of acute abdomen in children. Typical findings on imaging establish the diagnosis. We present case of a 7 years old boy who presented with acute right iliac fossa pain with diagnosis of omental infarction on imaging and findings confirmed on laparotomy. Sound knowledge regarding this infrequent cause of acute abdomen in children is necessary for timely diagnosis.

Keywords: Tuberculosis; Computed Tomography; Stomach.

J Ayub Med Coll Abbottabad 2016;28(3):623-4

INTRODUCTION

Omental Infarction is a rare cause of acute abdomen in children with about 50 reported cases so far.¹ It mostly involves the right iliac fossa and is often indistinguishable from acute appendicitis on clinical examination.^{2,3} We present a case of a 7 year old child with acute right iliac fossa pain, found to have omental infarction on imaging and findings confirmed on laparotomy.

CASE

A 7 years old boy presented to emergency room with complaints of severe right iliac fossa pain for past one day. On examination he was active, alert vitally stable and afebrile. He had a height of 120 cm and weight of 25 kg (BMI: 17.5). General physical examination was unremarkable; however he was severely tender to palpation in right iliac fossa on systemic examination. Lab workup revealed complete blood count, serum amylase and electrolytes to be within normal limits.

On clinical suspicion of appendicitis an ultrasound examination was ordered which revealed; a highly echogenic localized fat measuring 37×22×61 mm with no internal vascularity in the right iliac fossa. Sluggish peristaltic activity was seen in surrounding bowel loops. Appendix was not separately visualized and there was no free fluid. The patient however was significantly tender to probing during examination. Considering the overall appearances a suspicion of omental infarction was raised and further imaging advised.

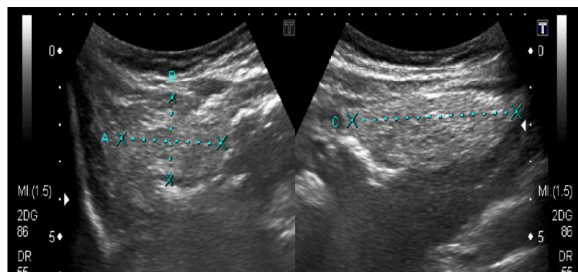


Figure 1: Longitudinal & transverse ultrasound images from right iliac fossa showing echogenic localized fat in right iliac fossa.

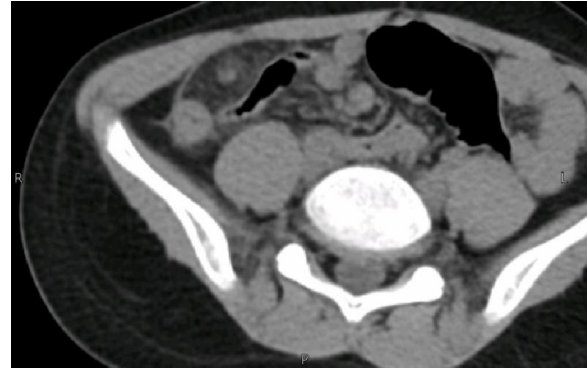

Figure-2: Axial section from right iliac fossa showing focal fat stranding in right iliac fossa with surrounding peritoneal enhancement and central hyper dense focus.

Non contrast CT scan of abdomen was then performed which showed a well-defined area of focal fat stranding between anterior abdominal wall and colon in right iliac fossa. There was surrounding peritoneal thickening and a high attenuation focus in the center of this area; likely representing a thrombosed vessel. It was correlating with findings of ultrasound examination in terms of size and location. Hence, a provisional diagnosis of omental infarction was made. (Figure-2) Since the inflammatory changes around this region were also encompassing appendix on CT examination, the surgical team opted for exploration. Findings of omental infarction were confirmed on laparotomy. Post operatively, patient had an uneventful recovery and was discharged from hospital on third post-operative day.

DISCUSSION

Omental infarction is reported as a rare cause of acute abdomen in children; especially obese. Acute onset pain of right iliac fossa is most common presentation as seen in our case as well.¹⁻³ Associated symptoms include nausea, vomiting and occasionally fever. Clinical examination is almost always positive for abdominal tenderness which is mostly localized to right lower quadrant. In addition peritoneal signs like rebound tenderness may be encountered in certain

cases.¹⁻³ Ultrasound is usually the first modality for imaging due to its lack of ionizing radiation & though less sensitive, it usually demonstrates hyper echoic cake like soft tissue mass in right iliac fossa with positive probe tenderness. Most common findings of omental infarction on plain CT include ill-defined mass of focal fat located between anterior abdominal wall & colon. Whirled hyper dense vessel is also usually seen in the center of the focal fat stranding.^{4,5} All of these features were seen on both modalities in our case. In some centers Magnetic resonance imaging (MRI) is followed by ultrasound using abdominal protocol for appendicitis which usually demonstrates a focal region of heterogeneous fat with surrounding inflammation and fluid in the right side of the abdomen between the ascending colon and the abdominal wall, representative of omental infarction.^{4,5}

CONCLUSION

Sound knowledge regarding omental infarction in children is necessary for prompt diagnosis and appropriately guiding management.

REFERENCES

1. Tsunoda T, Sogo T, Komatsu H, Inui A, Fujisawa T. A case report of idiopathic omental infarction in an obese child. *Case Rep Pediatr* 2012;2012:513634.
2. Van Kerkhove F, Coenegrachts K, Steyaert L, Ghekiere J, Gabriel C, Casselman JW. Omental infarction in childhood. *JBR-BTR* 2006;89(4):198-200.
3. Varjavandi V, Lessin M, Kooros K, Fusunyan R, McCauley R, Gilchrist B. Omental infarction: risk factors in children. *J Pediatr Surg* 2003;38(2):233-5.
4. Grattan-Smith JD, Blews DE, Brand T. Omental infarction in pediatric patients: sonographic and CT findings. *AJR Am J Roentgenol* 2002;178(6):1537-9.
5. Rimon A, Daneman A, Gerstle JT, Ratnapalan S. Omental infarction in children. *J Pediatr* 2009;155(3):427-31.

Address for Correspondence:

Saad Siddiqui, House No.159, Street-10, Sector: H-1, Phase-2, Hayatabad, Peshawar-Pakistan

Cell: +92 321 906 3099

Email: saadsiddiqui.5@gmail.com