



THE AGA KHAN UNIVERSITY

eCommons@AKU

---

Department of Radiology

Medical College, Pakistan

---

June 1992

# Oesophageal carcinoma caused by betel nut

M Y. Sheikh

I H. Rizvi

I Ahmed

Follow this and additional works at: [https://ecommons.aku.edu/pakistan\\_fhs\\_mc\\_radiol](https://ecommons.aku.edu/pakistan_fhs_mc_radiol)



Part of the [Radiology Commons](#)

---

## Recommended Citation

Sheikh, M. Y., Rizvi, I. H., Ahmed, I. (1992). Oesophageal carcinoma caused by betel nut. *Journal of Pakistan Medical Association*, 42(6), 145-146.

**Available at:** [https://ecommons.aku.edu/pakistan\\_fhs\\_mc\\_radiol/226](https://ecommons.aku.edu/pakistan_fhs_mc_radiol/226)

# **OESOPHAGAL CARCINOMA CAUSED BY BETEL NUT**

Pages with reference to book, From 145 To 146

Mohammad Younus Sheikh ( Department of Radiology, The Aga Khan University Medical Centre, Karachi. )

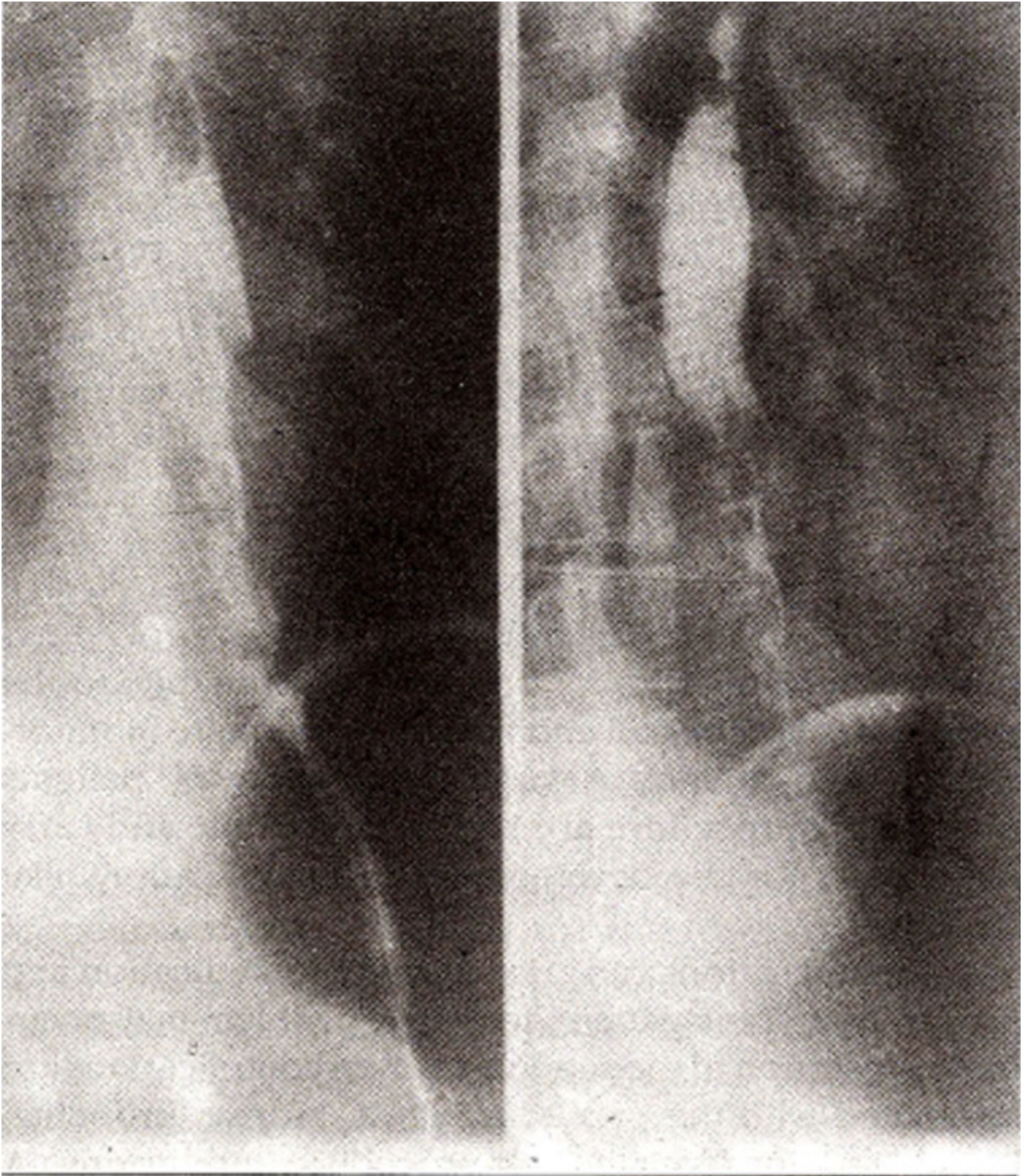
Imtiaz Hussain Rizvi, Iftikhar Ahmed ( Departments of Radiology, The Aga Khan University Medical Centre, Karachi. )

## **INTRODUCTION**

Number of food stuffs and other oesophageal pathologies have been implicated to carcinoma of the oesophagus but to the best of our knowledge, no relation to Commercially available betel nuts has been described. We present a case of a young female developing carcinoma of the oesophagus which may be due to excessive use of commercially available sweetened betel nuts (raseeli supari).

## **CASE REPORT**

A 30 year old lady presented with history of dysphagia. She gave history of taking 8-10 packets of commercially available betel nuts (raseeli supari) every day for last 10-12 years. Oesophagogram was performed which demonstrated an area of irregular narrowing and shouldering involving lower third of the oesophagus (Figure).



**Oesophagogram showing an area of irregular narrowing and shouldering involving lower third of the oesophagus.**

Biopsy of the lesion proved it to be poorly differentiated squamous cell carcinoma. Lesion was thought to be inoperable and after palliative surgery patient was referred for radiotherapy. She expired 9 months after the diagnosis.

## DISCUSSION

The evidence on the aetiology of the carcinoma of the oesophagus is largely indirect, based on epidemiological studies and circumstantial inference derived from other coexisting oesophageal pathologies. Carcinoma of the oesophagus is largely a disease of middle aged males; incidence being four times higher in males. Blacks are affected more commonly by the disease<sup>1</sup>. Different etiological factors have been implicated in different parts of the world, for example in Iran and China carcinoma of the oesophagus is probably due to deficiency of different nutrients like vitamin A, riboflavin, thiamine and pyridoxine and minerals like zinc and molybdenum<sup>1-3</sup>. Ingestion of hot beverages, coarse food stuffs and presence of nitrates in the food have also been implicated in the causation of chronic oesophagitis which is thought to be precancerous<sup>2</sup>. In Saudi Arabia water contamination by petroleum, containing benzene and polycyclic hydrocarbons have been postulated to be the causative factor<sup>4</sup>. German workers exposed to ethylene oxide showed increased incidence of oesophageal carcinoma<sup>5</sup> while in Sweden chimney sweeps exposed to polycyclic aromatic hydrocarbons had an increased incidence of oesophageal carcinoma<sup>6</sup>. Dietary habits like consumption of alcohol and smoking<sup>1,7,8</sup> are also associated with this disease. Burnt and unburnt tobacco contains nitrosornicotine which is thought to be the offender carcinogen. Fungal contamination of the food is also carcinogenic<sup>7,8</sup>. Different oesophageal pathologies have been associated with cancer. These include achalasia<sup>1,7,8</sup> oesophageal webs in Plummer Vinson Syndrome<sup>7</sup>, Zenkér's diverticulum<sup>1,8</sup> strictures caused by Lye ingestion<sup>7,8</sup> and hiatus hernia leading to Barrett's oesophagus<sup>8,9</sup>. An interesting association between some skin disorders: and oesophageal carcinoma has been noted. These include epidermal dysplasia like tylosis and epidermolysis bullosa<sup>1,7</sup>. Long standing celiac disease is also associated with the disease. In our case there appears to be a very strong association between oesophageal cancer and ingestion of large amount of commercially available sweetened betel nut (raseeli supari). As the patient did not belong to the susceptible age group and sex, betel nut is the most likely etiologic agent. The question whether the carcinogen is betel nut itself or artificial sweeteners and colouring agents, needs to be evaluated.

## REFERENCES

1. Dayal, Y and DeLellis, R.A. The gastrointestinal tract, in pathological basis of diseases. By Rarnzi S. Cotran, Vinay Kumar and Stanley L Robbins. 4th ed. Philadelphia. Saunders, 1989. pp. 835-36
2. Munoz, N., Crespi, M., Grassi, A., Qing, W.G., Qiong. S. and Cai, L.Z. Precursor lesions of oesophageal cancer in high-risk populations in Iran and China. *Lancet*, 1982;1:816-79.
3. Noetzel, C., Mobarhan, S., Negal, P., Layden, T. and Junigk, A. Vitamin A and riboflavin nutrition in patients with oesophageal cancer, oesophageal disorders, pathophysiology and therapy. Edited by T.R. DeMeester and O.S. Skinner. New York, Raven Press, 1985, pp.319-26.
4. Amer, M.M., el-Yazigi, A., Hannan, M.A. and Mohammed, M.E. Contamination and oesophageal cancer of Qasim region. Saudi Arabia. *Gastroenterology*, 1990;98:1141-47.
5. Klesselbach, N., Him, K., Lange, H.J. and Korallus, U. A multicentre mortality study of workers exposed to ethylene oxide. *Br.J. Industrial Med.*, 1990;47:182-88.
6. Gustavsson, P., Gustavsson, A. and Hogstedt, C. Excess of cancer in Swedish chimney sweeps. *Br.J. Industrial Med.*, 1988;45:777-81.
7. Moertel, C.C. Alimentary tract, in cancer medicine. Edited by James F. Holland, Emil Frel. Philadelphia, Lea and Febiger, 1982, pp.1753-54.
8. Enterline, H.T. and Thompson, J.J. The oesophagus, in principles and practice of surgical pathology. Edited by Seven C. Silverberg. New York, Wiley, 1983, pp. 805-6.

9. Cooper, B.T. and Barbezat CO. Barrette's oeaophagus: a clinical study of 52 patients. *Q.J. Med.*, 1987;62:97-108.