



THE AGA KHAN UNIVERSITY

eCommons@AKU

Department of Pathology and Laboratory Medicine

Medical College, Pakistan

August 1995

A 55 year old diabetic presenting with a rash and polyneuropathy

S Hyder

Aga Khan University

H Rasool

Aga Khan University

H Naqvi

Aga Khan University

Naila Kayani

Aga Khan University, naila.kayani@aku.edu

Follow this and additional works at: https://ecommons.aku.edu/pakistan_fhs_mc_pathol_microbiol



Part of the [Microbiology Commons](#), and the [Pathology Commons](#)

Recommended Citation

Hyder, S., Rasool, H., Naqvi, H., Kayani, N. (1995). A 55 year old diabetic presenting with a rash and polyneuropathy. *Journal of Pakistan Medical Association*, 45(8), 228-230.

Available at: https://ecommons.aku.edu/pakistan_fhs_mc_pathol_microbiol/747

A 55 Year Old Diabetic Presenting With A Rash And Polyneuropathy

Pages with reference to book, From 228 To 230

S. Hyder (Departments of Medicine, The Aga Khan University Hospital, Karachi.)

H. Rasool, H. Naqvi (Departments of Medicine, The Aga Khan University Hospital, Karachi.)

N. Kavani (Departments of Pathology, Aga Khan University Hospital, Karachi.)

Presentation of Case

A 55-year old man from Hazara was admitted to the Aga Khan University Hospital because of fever, generalized weakness and pain and swelling in his legs. The patient had been well until 14 months ago when he was diagnosed to have diabetes mellitus. He was treated with Gliclazide but his blood sugars remained high and he later went to a Hakeem. The Hakeem gave him some powder, which he took every day in a glass of water. Six months prior to presentation he developed progressive weakness and pain in his legs. At the same time he noticed swelling in his feet, which gradually extended to involve his legs and later his hands and arms as well. Eventually his face became puffy. He had difficulty in getting up from a squatting position and as his weakness worsened he became bed bound. The pain in his legs was described as a sharp burning sensation particularly in the soles, with tenderness in both legs. He had fever intermittent but 15 days prior to presentation this had become constant at 102°F. The patient's past medical history was unremarkable. He had a left hemiorrhaphy in the remote past. Review of systems was also non-contributory: there was no history of chronic cough, weight loss, bowel or bladder dysfunction. He came from Haripur Hazara, and was married with children. He did not smoke nor drink (alcohol) and reported no other addictions. He had never travelled outside Pakistan. Medication history was significant for having taken various forms of herbal medicines from Hakeems. He had no known allergies. On examination; he was a middle aged man, in mild distress due to pain and generalized edema. The temperature was 37.5°C, pulse 100/min respiratory rate 24/min and blood pressure 150/90. There was a diffuse maculo-papular, erythematous rash over entire body; worse on the face and trunk. There were some dry shiny scales on legs. No lymphadenopathy, cyanosis or clubbing was noted. Peripheral arterial pulsations were present. There was mild tenderness in muscles, particularly calves, to palpation. Cardiovascular, respiratory and abdominal examination was unremarkable. On neurological examination, the patient was alert and oriented with intact speech and intellectual function. Cranial nerves showed no deficits.

Admitting diagnosis

Polymyositis/Dermatomyositis

Peripheral neuropathy secondary to diabetes mellitus

Initial investigations

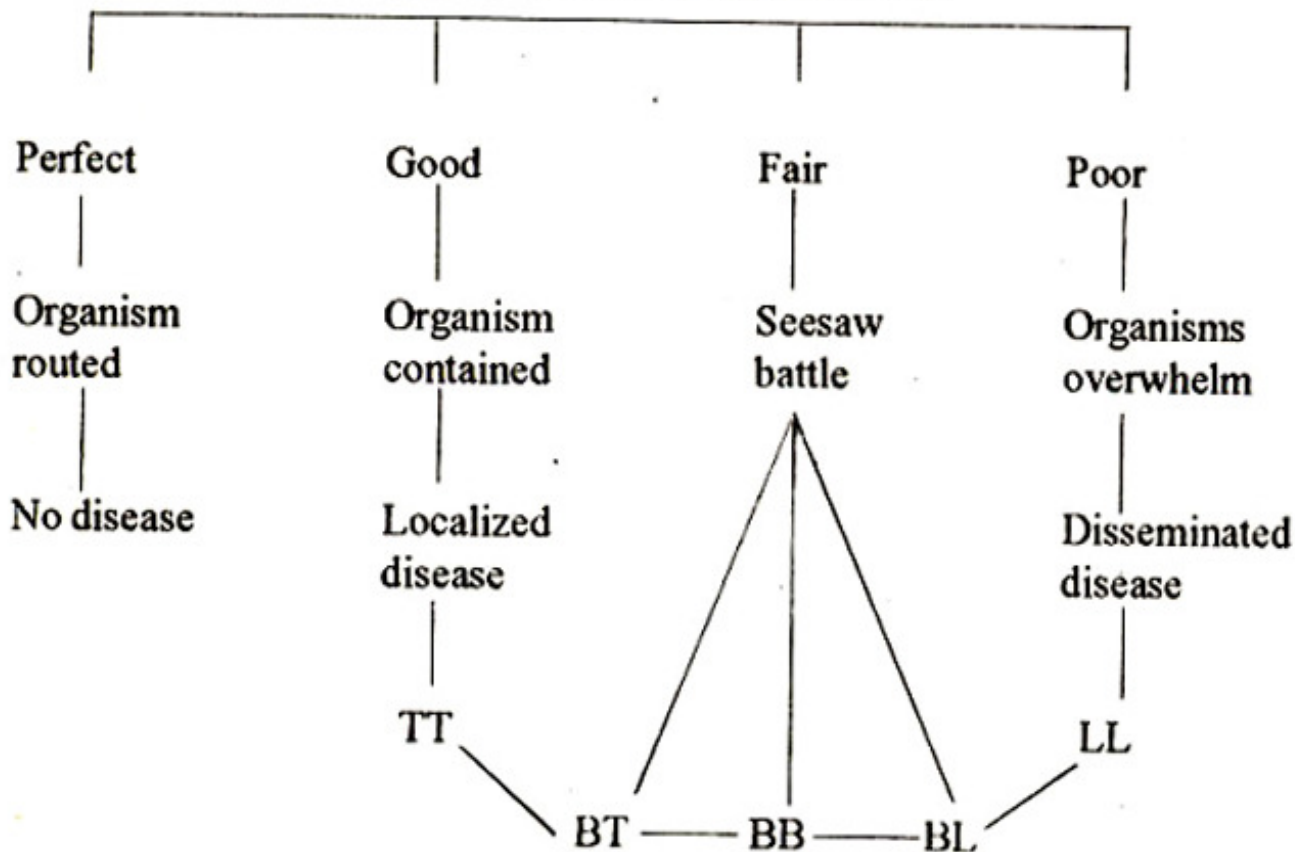
CBC	Hemoglobin	13 gm/dl
WBC		7.6 X 10E ⁹ /L (N 79% L: 18% E 2% M: 1%)
ESR		25mm/Hr
M.P:		Not seen
SerumGlucose		54 mg/dL
BUN		9 mg/dL
Creatinine		0.9 mg/dL
Sodium		135 mmol/L
Potassium		4.3 mmol/L
Chloride		100 mmol/L
Bicarbonate		22.3 mmol/L
Bilirubin		0.9
SGPT		161.U/L
Alk. Phos		881.U/L
Total Protein		7.29/dL
Albumin		3.0/dl
Globulin		4.2/dL
A/G Ratio		0.7
Urine DR		Normal
CXR		Normal
ECG		Normal

Further investigations

CPK	33 IU/L (17-176)
Aldolase	5.0 U/L (0.1-7.6)
T4	4.5 mg/dL (4.5-12.0)
TSH	1.31 u/u/ml (0.32-5.0)
Calcium	10.0 mg/dL (8.6-10.5)
Phosphorus	3.8 mg/dL (2.7-4.8)
ANA	Negative
Anti-DNA	2.6 (Normal)
Serum B ₁₂	1818.6 pg/ml (200-950)
Serum Folate	9.0 mg/ml (3.0-17.0)

Facial sensations were intact. Motor system showed a mild weakness of 4/5 in his legs worse proximally; power in the arms seemed to be 5/5, but full assessment of strength was difficult because of pain. Deep tendon reflexes were brisk all over, except the ankle jerks. Plantar responses were withdrawal due to intense dysesthesia. On sensory examination vibration and position sense were diminished at the periphery. Light touch was intact, but perceived as pain Temperature sensation also seemed diminished in the periphery.

Host Immune Status



There was no ataxia on finger-nose-finger testing; he could not do the heel to shin maneuver because of pain and edema. He required assistance from 2 people to get him out of bed and help him walk, which was limited due to dysesthetic soles.

Differential Diagnosis:

In summary, this middle aged man with a questionable history of diabetes (his blood sugar on admission was normal and he was on no oral hypoglycemic agents) has developed, over the last 6 months, progressive weakness, edema, rash and dysesthesia, mainly in his legs. His neurological examination was significant for decreased vibration and altered temperature sensation at the periphery. The deep tendon reflexes were intact and there was mild proximal weakness, particularly evidenced by difficulty in getting up from the squatting position. Because of the rash and proximal weakness, the admitting team's initial impression of dermatomyositis seems quite reasonable and the sensory dysfunction may be explained by the history of diabetes mellitus with possible secondary peripheral neuropathy.

However, the finding of normal to brisk deep tendon reflexes argues against a peripheral neuropathy. An upper motor neuron lesion (for example high in the cervical cord) is also a possibility. The normal CPK, Aldolase and ESR also point against the diagnosis of Dermatomyositis/Polymyositis. Other possibilities include a hypothyroid state, with weakness, edema and neuropathy: The CPK may be normal in dysthyroid myopathies.

Nerve Conduction Studies showed:

		Latency (m/sec)	Amplitude (mv)	NCV m/s
Nerve (Motor)				
Right	post-tibial	12.2	148 uv	24.05
Right	Peroneal	11.4	48.8 uv	13.97
Left	Post tibial	10.6	98 uv	25.69
Right	Median	4.16	3.5 mv	44.64
Right	Ulnar	4.72	1.93 mv	43.20
Nerve (Sensory)				
Right	Sural	No response		
Right	Median	4.16	11.30	
Right	Ulnar	4.40	4.88	
Left	Sural	No response		

Electromyography

Muscle	Spontaneous Activity	Motor units	Interference Pattern
Right Tibialis Anterior	Fibrillation Potentials and Positive Waves	High amplitude poly-phasic	Reduced
Right Quad- riceps	Nil	High amplitude poly-phasic	Reduced
Right Abductor Pollicis Brevis	Fibrillative, +ve waves	High amplitude poly-phasic	Reduced
Right Biceps	Nil	High amplitude poly-phasic	Reduced

However the thyroid profile is quite normal. In addition, the deep tendon reflexes in hypothyroidism have a typical slowed relaxation phase and presence of a rash also does not go along with the suggested diagnosis. Vitamin B12 or folate deficiency states (significant loss of vibration sense at the periphery) have also been excluded by the normal serum levels. Secondary syphilis needs to be considered at this stage. Other possibilities include i) a paraneoplastic process with resultant myopathy and neuropathy; ii) Amyloidosis; iii) Leprosy (iv) Toxic neuropathy (Arsenic, Thallium) since he has been taking an unknown white powder from a hakeem for some time. (v) Vasculitis. None of these diagnoses based on the history and physical examination, as well as available investigation, seems very likely. The next

step would be to confirm the presence of myopathy and/or neuropathy. This is best done by a Nerve conduction study/electromyogram (NC/EMG).

Interpretation

Bilateral posterior tibial, right peroneal and right ulnar motor nerves have a very low amplitude, prolonged distal latency and a slow conduction velocity. The Right Median motor nerve has a low amplitude, a normal distal latency and a slow conduction velocity. F-wave latencies were absent in the lower limbs. Sural nerves have no responses bilaterally. (R) Median and ulnar sensory nerves are normal. Needle examination shows evidence of denervation in the muscles tested.

Conclusion

Severe generalized sensori-motor polyneuropathy, predominantly demyelinating, with axonal features as well. Subsequent to this NC/EMG finding, a serum protein electrophoresis was done that showed mild hypo-albuminemia, with a polyclonal increase in the gamma globulin fraction. CSF analysis showed a normal CSF protein of 42 mg/dl, Glucose 51 mg/dl, TLC 04/cu mm and RBC 42/cu mm. A skin biopsy showed evidence of a granulomatous process consistent with sarcoidosis, which led to checking for angiotensin converting enzyme in the blood. This was 237 units (normal 8.0-52), again suggestive of sarcoidosis. The patient was subsequently placed on steroids; the rash slowly improved. However weakness, edema and sensory symptoms persisted. A sural nerve biopsy was eventually performed because there was no other evidence to support a diagnosis of sarcoidosis. The biopsy showed: "Nerve fibres infiltrated by granulomatous inflammatory cells consisting of epithelioid cells, multi-nucleated giant cells, plasma cells and lymphocytes. The inflammation is extending into adjacent fibro-adipose tissue. The myelin is vacuolated. Special stains for leprosy bacillus is positive. Final diagnosis sural nerve: features are consistent with tuberculoid type of leprosy". As a hind-sight the skin biopsy had not been stained for leprosy for technical reason. The angiotensin converting enzyme is non-specific and may be high in tuberculosis, vasculitis and leprosy besides sarcoidosis.

Final diagnosis: Tuberculoid Leprosy.

Discussion

Leprosy is a mycobacterial infection of the peripheral nerves. The clinical manifestations of infection with *Mycobacterium leprae* may be quite diverse, depending on host immune status. There are 3 main clinical varieties:

1. Tuberculoid (TT)
2. Borderline (BB)
3. Lepromatous (LL)

The clinical features of leprosy include hypo-pigmentation accompanied by a loss of sensation. The sequence of sensory loss is often though not always: temperature pain touch, pressure and position. The intra cutaneous nerve involvement causes a pattern of sensory loss totally unlike that following peripheral nerve affection². For purposes of treatment, patients with Leprosy are classified as having the paucibacillary (bacteriologically negative) or multibacillary (bacteriologically positive) forms. For the paucibacillary form, combination therapy with Dapsone (0.9-11.4 mg/kg per day; standard adult dose 100 mg/day) self-administered, and Rifampicin (10 mg/kg once a month standard adult dose 450-600 mg) taken on an empty stomach, under supervision. For multibacillary leprosy, clofazimine is added at a dose of 50 mg/day self administered and 300 mg once a month, supervised.

Treatment is given for 6 months in the paucibacillary type and 2 years in the multibacillary type¹.

Treatment of reactions includes salicylates, chloroquine and non steroidal anti-inflammatory agents.

Corticosteroids are indicated in severe nerve involvement, but are otherwise preferably avoided⁷. Care

of the hands and feet is very important. They should be inspected daily. Damage to the larger nerves can cause glove and stocking type anaesthesia, with ulcers, due to trauma in parts that lack sensation. This may even lead to falling off of the fingers and resorption of terminal digits^{5,6}. The single definitive diagnostic feature of Leprosy is microscopic evidence of dermal nerve damage and, infiltration with macrophages containing acid fast bacilli. Patients with leprosy develop episodic reactions that can lead to severe morbidity. Type 1 or reversal reactions occur in borderline leprosy, with or without systemic effects, but show exaggerated local immune responses in the lesions alone. When these reactions occur in the peripheral nerves, painful abscesses and nerve damage are much feared sequelae. Type II reactions, also called Erythema Nodosum leprosum, occur in multi bacillary forms of BL leprosy⁴. Patients have severe morbidity, with fever and joint and kidney involvement. These systemic manifestations are thought to be caused by immune complexes, formed by antigen released from fragmentation of bacilli, together with circulating coagulating antibodies in the serum. These events usually follow institution of specific drug therapy³.

References

1. Grand Round: Leprosy: Lancet, 1995; 345:697-703.
2. Brown, S.G. Leprosy. In: Clinical Tropical Diseases, Oxford, Blackwell Scientific publications, 1984, 8th Edition, pp. 211-245.
3. Dastier, D.K. 1978 Leprosy - an infectious and immunological disorder of the nervous system Ch. 19 In: Hand-book of clinical Neurology, 1984, Vol. 33 pp. 421-468.
4. Vernon, J.M.I., McDougall, A.C., Latham, A.J. and Harris. H.J. Lepromatous leprosy presenting with polyarthritis, uveitis and immune complex glomerulonephritis Br. Med J., 1975, iii, 619-621.
5. Joplin, W.H. Clinical aspects of Leprosy. Tubercle., 1982; 63: 295-305.
6. Shepard, C.C. Leprosy today. N. Engl J. Med., 307: 1982; 1640-1641.
7. Wood, M., Anderson, M. Neurological infections. W.B.Saunders Company, 1988; pp 591-600.