



THE AGA KHAN UNIVERSITY

eCommons@AKU

Department of Radiology

Medical College, Pakistan

October 2013

An unsuspected bleeding Meckel's diverticulum in an adult detected on mesenteric angiography

Muhammad Ali
Aga Khan University

Raza Sayani
Aga Khan University, raza.sayani@aku.edu

Muhammad Azeemuddin
Aga Khan University, muhammad.azeemuddin@aku.edu

Tanveer-ul-Haq
Aga Khan University, tanveer.haq@aku.edu

Rizwan Khan
Aga Khan University, khan.rizwan@aku.edu

Follow this and additional works at: https://ecommons.aku.edu/pakistan_fhs_mc_radiol



Part of the [Radiology Commons](#)

Recommended Citation

Ali, M., Sayani, R., Azeemuddin, M., Tanveer-ul-Haq, ., Khan, R. (2013). An unsuspected bleeding Meckel's diverticulum in an adult detected on mesenteric angiography. *Journal of the College of Physicians and Surgeons Pakistan*, 23(10), 759-760.

Available at: https://ecommons.aku.edu/pakistan_fhs_mc_radiol/151

An Unsuspected Bleeding Meckel's Diverticulum in an Adult Detected on Mesenteric Angiography

Muhammad Ali¹, Raza Sayani¹, Muhammad Azeemuddin¹, Tanveer-ul-Haq¹ and Rizwan Khan²

ABSTRACT

Meckel's diverticulum is usually asymptomatic and found in almost 2% of the population. Haemorrhage from a Meckel's diverticulum is common in children but rare in adults. Here we report a case of 20 years old male with recurrent gastrointestinal bleeding. Meckel's diverticulum was diagnosed due to abnormal vascularity on mesenteric angiography and embolization was performed. Diagnosis was correlated with other radiological imaging and later elective resection was performed. This case is reported to emphasize the potential role of mesenteric angiography in the detection and management of bleeding Meckel's diverticulum and correlation with other radiological imaging.

Key Words: *Meckel's diverticulum. Mesenteric angiography. Recurrent gastrointestinal haemorrhage.*

INTRODUCTION

Meckel's diverticulum was first described by Johann Friedrich Meckel in 1809 and is the most common congenital anomaly of the gastrointestinal tract.¹ It is a true diverticulum with all layers of the intestinal wall present, and usually arises from the antimesenteric border.² It has its own blood supply from a terminal branch of the superior mesenteric artery known as vitello-intestinal artery.³ It is usually asymptomatic with occasional complications of bleeding, obstruction, diverticulitis and neoplasm.⁴ Because most symptomatic diverticula contain ectopic gastric tissue, radionuclide imaging with Technetium (Tc) ^{99m} pertechnetate is considered to be the method of choice for their detection.⁵ However, a bleeding Meckel's diverticulum may not be detected on radionuclide imaging inspite of the presence of ectopic gastric mucosa.⁵ In these cases, mesenteric angiography is an alternative procedure for detecting Meckel's diverticulum.⁶

This case is reported to emphasize the potential role of mesenteric angiography in the detection and management of bleeding Meckel's diverticulum and correlation with other radiological imaging.

CASE REPORT

A 20 years old male presented to ER with the complaint of painless rectal bleeding for last 6 days. He had a similar episode 6 months back when extensive investigation was performed including upper GI endoscopy, colonoscopy and mesenteric angiogram, but all came out to be negative.

Department of Radiology¹ / Surgery², The Aga Khan University Hospital, Karachi.

Correspondence: Dr. Muhammad Azeemuddin, II-A-6/24, Nazimabad, Karachi-74600.

E-mail: muhammad.azeemuddin@aku.edu

Received: December 23, 2011; Accepted: January 19, 2013.

On admission, the patient's blood pressure was 100/60 mm Hg, haemoglobin level was 8.9 g/dl and hematocrit was 21%. On examination, he had painless per rectal bleeding. Episodes of bleeding continued over next 3 days of admission and a total of 8 units of packed red cells were administered. He bled profusely on the third day and was shifted to the special care unit. His urgent RBC-tagged radionuclide scan was performed which showed abnormal focus of bleeding in the pelvis (Figure 1a). His mesenteric angiogram was performed which showed profuse active extravasation of contrast from an abnormal end artery arising from ileocolic branch of superior mesenteric artery. The bleeding vessel was successfully embolized with micro-coils. Due to the abnormal location and course of the vessel, it appeared to be vitello-intestinal artery and suspicion of Meckel's diverticulum was raised (Figure 1b). His subsequent CT scan showed a blind ending intestinal pouch with enhancing walls in the lower mid abdomen (Figure 2a). Later on radionuclide Meckel's diverticulum scintigraphy was performed with 200 MBq Tc ^{99m} pertechnetate, which demonstrated tracer deposition in

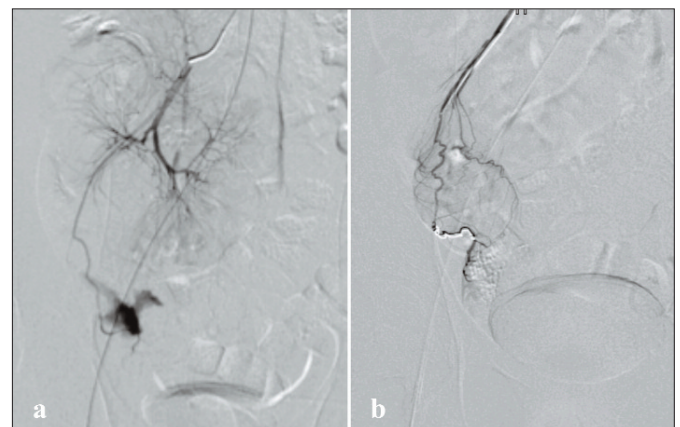

Figure 1: (a) Selective angiogram of ileocolic artery demonstrated profuse bleeding from an aberrant branch of SMA. (b) The vessel was super selectively cannulated and embolized with two pushable platinum coils.

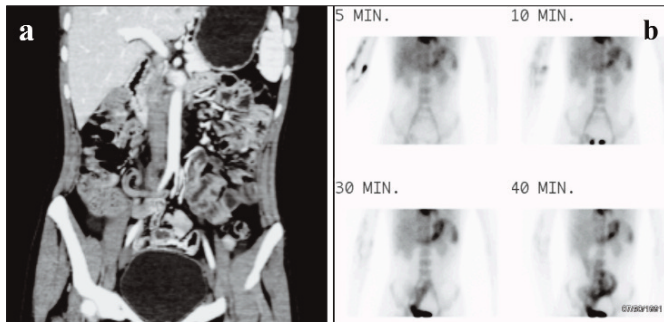


Figure 2: (a) Coronal reformatted image of contrast enhanced CT scan demonstrated abnormal blind ended bowel loop in hypogastric region with enhancing walls. (b) Subsequent pertechnetate scan showed abnormal tracer accumulation in the hypogastric region.

the hypogastric region (Figure 2b). Findings confirmed the presence of heterotopic gastric mucosa due to Meckel's diverticulum.

After that, an open Meckel diverticulectomy was performed. Meckel's diverticulum was found around 2 cm from ileocecal junction on the anti-mesenteric border. Patient recovered well from surgery and was discharged on the third day. There have been no further episodes of gastrointestinal bleeding on follow-up till 2 months after surgery.

DISCUSSION

There are many causes of obscured gastrointestinal haemorrhage in young adults including angiodysplasia, diverticulitis, tumours, Crohn's disease, and NSAID-induced ulcers.² However, haemorrhage from a Meckel's diverticulum is very rare in the adult age group and is usually overlooked as the possible cause of occult lower gastrointestinal bleed.⁷ Angiographic detection of vitello-intestinal artery plays a pivotal role in detection of Meckel's diverticuli. The vitello-intestinal artery has been seen to arise as fifth, sixth or seventh ileal branch and appears as a long branch with few or no branch. Groebli *et al.* found haemorrhage in 15% of symptomatic diverticula in 52 adults.⁸ Mackey and colleagues reviewed 402 patients with Meckel's diverticulum in which only 16.9% of the patients were symptomatic and only one quarter of them had gastrointestinal haemorrhage.⁹ Haemorrhage is caused by peptic ulceration produced by secretion of acid and pepsin from ectopic gastric mucosa as it was found in this case and described by several authors.^{2,6} The traditional diagnostic test of choice has been the Meckel's scan, in which technetium-^{99m} is taken-up by ectopic gastric mucosa but it cannot be performed in emergency setup.¹⁰ Other options include enteroclysis, CT scan, magnetic resonance imaging, ultrasound and capsule endoscopy.⁶

Angiography plays a dominant role, because it can show the bleeding site and, at the same time, provide

effective treatment of haemorrhage by transcatheter embolization.^{2,4} In patients with intermittent bleeding, demonstration of an abnormal embryonic artery indicates the high probability of Meckel's diverticulum; even without active extravasation of contrast. Previous reports have also identified this abnormal artery supplying the Meckel's diverticulum.⁸

In this case, there was a history of recurrent lower gastrointestinal haemorrhage but there was no clinical suspicion of Meckel's diverticulum. Angiographic detection and later confirmation by other modalities and surgery, as in this case, is infrequent. By using microcatheter, this artery was super selectively catheterized and successfully embolized the bleeding vessel with limited risk to the adjacent bowel.

In conclusion, possibility of Meckel's diverticulum should be suspected in adult patients with occult gastrointestinal haemorrhage and finding of abnormal vitello-intestinal artery on mesenteric angiography.

REFERENCES

1. Levy AD, Hobbs CM. From the archives of the AFIP. Meckel's diverticulum: radiologic features with pathologic correlation. *Radiographics* 2004; **24**:565-87.
2. Lee JS, Moon W, Park SJ, Park MI, Kim KJ, Lee SH, *et al.* Haemorrhagic Meckel's diverticulum in an older woman diagnosed by repeated angiographies. *Turk J Gastroenterol* 2009; **20**:282-6.
3. Stone PA, Hofeldt MJ, Lohan JA, Kessel JW, Flaherty SK. A rare case of massive gastrointestinal haemorrhage caused by Meckel's diverticulum in a 53-year-old man. *WV Med J* 2005; **101**:64-6.
4. Mitchell AW, Spencer J, Allison DJ, Jackson JE. Meckel's diverticulum: angiographic findings in 16 patients. *AJR Am J Roentgenol* 1998; **170**:1329-33.
5. Geelhoed GW, Druy EM, Steinberg WM. Recurrent bleeding from Meckel's diverticulum in an adult: angiographic demonstration after normal scans. *South Med J* 1986; **79**: 65-8.
6. Munroe CA, Copland A, Pai R, Friedland S, Triadafilopoulos G. Meckel's diverticulum with gastrointestinal bleeding: role of computed tomography in diagnosis. *Dig Dis Sci* 2010; **55**:242-4.
7. Kopácová M, Vykouril L, Vacek Z, Tycová V, Bárťová J, Rejchrt S, *et al.* Inverted Meckel's diverticulum with ectopic pancreatic tissue as a source of severe gastrointestinal bleeding. *J Gastrointest Surg* 2010; **14**:578-81.
8. Groebli Y, Bertin D, Morel P. Meckel's diverticulum in adults: retrospective analysis of 119 cases and historical review. *Eur J Surg* 2001; **167**:518-24.
9. Mackey WC, Dineen P. A fifty year experience with Meckel's diverticulum. *Surg Gynecol Obstet* 1983; **156**:56-64.
10. Huang MC, Huang FC, Cheng YF, Shieh CS. The value of angiography in diagnosis of Meckel's diverticulum: case report. *Chang Gung Med J* 2000; **23**:716-9.

