



THE AGA KHAN UNIVERSITY

eCommons@AKU

Section of Cardiology

Department of Medicine

January 2005

Cardiogenic shock after dipyridamole administration for myocardial perfusion imaging

Fahim H. Jafary
Aga Khan University

Nageeb Basir
Aga Khan University, nageeb.basir@aku.edu

Adnan Amin
Aga Khan University

Nasiruddin Ahmed
Aga Khan University, nasiruddin.ahmed@aku.edu

Follow this and additional works at: https://ecommons.aku.edu/pakistan_fhs_mc_med_cardiol

 Part of the [Cardiology Commons](#), [Critical Care Commons](#), and the [Pulmonology Commons](#)

Recommended Citation

Abstract not provide by Author/Publisher.



Cover Page

Cardiogenic Shock Following Dipyridamole Administration for Myocardial Perfusion Imaging

Journal:	<i>Journal of Nuclear Cardiology</i>
Manuscript ID:	JNC-05-005-BU.R1
Manuscript Type:	Bullet
Date Submitted by the Author:	19-Jan-2005
Complete List of Authors:	Jafary, Fahim; Aga Khan University Hospital, Section of Cardiology Basir, Nageeb; Aga Khan University Hospital, Section of Cardiology Amin, Adnan; Aga Khan University Hospital, Section of Cardiology Ahmed, Nasiruddin; Aga Khan University Hospital, Section of Cardiology
Keywords:	Vasodilator stress, Unstable angina, Ischemia, myocardial, Infarction, myocardial, Dipyridamole
Note: The following files were submitted by the author for peer review, but cannot be converted to PDF. You must view these files (e.g. movies) online.	
Figure3.tif Figure4.tif	

powered by ScholarOne
Manuscript Central™

Cardiogenic Shock Following Dipyridamole Administration for Myocardial Perfusion Imaging

Fahim H. Jafary, M.D., F.A.C.C.^{1§}, Nageeb Basir², M.D., Adnan Amin³, M.D.,
Nasiruddin Ahmed⁴, M.D.

^{1,2,3,4} Department of Medicine,
Section of Cardiology,
Aga Khan University Hospital, Karachi, Pakistan.

[§] corresponding author

Address for Correspondence:

Fahim H. Jafary, M.D., F.A.C.C.
Assistant Professor and Consultant Cardiologist
Department of Medicine, Section of Cardiology
Aga Khan University Hospital
PO Box 3500, Stadium Road, Karachi 74800
Pakistan
Fax +9221 493-4294
Telephone +9221 4859-4700
Email jafary@pobox.com

Competing Interests: None

Word Count 981

Case Presentation:

This 52-year-old gentleman with a prior history of hypertension, transient ischemic attacks and prior myocardial infarction 24-years ago presented to our hospital with a two week history of worsening exertional angina. He was brought to the nuclear laboratory for a dipyridamole myocardial perfusion study. Resting images were taken following the injection of 290 MBq of intravenous Tc-99m tetrofosmin (figure 1). Dipyridamole was infused at 0.56 mg/kg over four minutes. A few minutes after completion of the infusion the patient's initial blood pressure declined from 120/70 mm Hg to 70/40 mm Hg. This was associated with profound ST-depression in multiple ECG leads (figure 2), chest pain, dyspnea and overt signs of congestive heart failure. He was given intravenous aminophylline (125 mg) immediately with improvement in his blood pressure to 90 mm Hg systolic and partial resolution of the ST depression on his ECG. Owing to his unstable condition, stress images were deferred and the patient was shifted immediately to the cardiac catheterization laboratory where he was electively intubated for worsening heart failure and hypoxemia. Coronary angiography revealed critical left main coronary artery disease (figure 3; *single arrow*) with poor antegrade flow in the left anterior descending (LAD) artery (figure 3; *small arrows*) and complete occlusion of the left circumflex (LCx) artery. The right coronary artery also had a critical lesion proximally (figure 4; *single arrow*) with collateral flow to the LCx (figure 4; *double arrows*) and the LAD (figure 4; *arrowheads*). An intra-aortic balloon pump was inserted and the patient was taken for emergent coronary artery bypass surgery. He received vein grafts to the LAD, right coronary and marginal arteries. His post-operative course was relatively uneventful and he was discharged on the seventh day after the operation. Creatine-kinase (MB) prior to surgery

1
2
3 was 30.6 ng/ml (0-3.97). Left ventricular function following discharge was 40-45% by
4
5 echocardiography.
6
7
8
9
10

11 **Discussion:**

12
13
14
15
16
17 Intravenous dipyridamole is a widely used agent for pharmacologic stress myocardial perfusion
18 imaging (MPI). Dipyridamole induces a differential degree of coronary vasodilatation in beds
19 supplied by normal and stenosed epicardial coronary arteries. As the vessels subtended by a
20 stenosed coronary artery are significantly dilated at rest, further dilatation (and increase in flow) in
21 response to a vasodilator like dipyridamole is limited. On the other hand, vessels in the normal
22 areas undergo significantly more vasodilation (and increase in flow) leading to heterogeneity of
23 perfusion and, hence, a difference in uptake of flow-dependent radioisotopes like technetium
24 following dipyridamole administration. Thus, although regions supplied by stenotic epicardial
25 arteries appear “ischemic” on MPI due to differential blood flow (and radiotracer uptake), in the
26 majority of cases true tissue ischemia does not occur – in fact, due to some degree of additional
27 vasodilatation in response to dipyridamole (over the resting state) coronary blood flow actually
28 increases in these underperfused regions ¹.
29
30
31
32
33
34
35
36
37
38
39
40
41
42
43
44
45
46
47
48

49 The exception to this is when the phenomenon of “coronary steal” occurs, whereby an unfavorable
50 redistribution of blood flow takes place from underperfused areas towards better perfused regions
51 ^{2,3}. This has been described in association with collateral dependent myocardium, which becomes
52 ischemic following coronary vasodilation because of a decrease in pressure in the distal bed of the
53
54
55
56
57
58
59
60

1
2
3 feeder vessel. Perfusion to the collateralized myocardium declines as blood flow takes the path of
4
5 "least resistance". Estimates suggest that this phenomenon can occur in as many as 45% of
6
7 patients with severe coronary artery disease ⁴ and is frequently associated with ischemic ST-
8
9 segment depression ³. There are a number of reports in the literature of severe transient ischemia
10
11 induced during intravenous ⁵ and oral ^{6,7} dipyridamole administration requiring reversal of the effect
12
13 with intravenous aminophylline as well as intravenous nitrates. However, the overall incidence is
14
15 extremely low. In a large series on the adverse effects of dipyridamole MPI published by
16
17 Ranhosky et al., ⁸ four out of 3911 patients (0.10%) suffered a major adverse cardiac event (two
18
19 fatal and two nonfatal myocardial infarctions). Three of these four patients had a previous history
20
21 of worsening angina. More recently, in a report on 73,806 patients who underwent intravenous
22
23 dipyridamole MPI ⁹, there were seven cardiac deaths (0.95 per 10,000) and 13 nonfatal myocardial
24
25 infarctions (1.76 per 10,000). Although transient hypotension can occur in approximately 5% of
26
27 subjects ⁸, to date there are no formal reports of cardiogenic shock precipitated by intravenous
28
29 dipyridamole. In our patient the left coronary system was essentially occluded and was extensively
30
31 collateralized by the right coronary artery. While it is possible that dipyridamole induced
32
33 hypotension may have triggered an ischemic cascade, it is likely that dipyridamole caused a
34
35 significant degree of "steal" in the left coronary system leading to acute severe ischemia, heart
36
37 failure and shock. In retrospect, our patient did give a history of significantly worsening angina
38
39 (including resting symptoms) over the last few weeks but during the initial assessment he under-
40
41 reported his symptoms. Perhaps if the true symptomatology had been known, he may have been
42
43 scheduled directly for coronary angiography. However, at the time of the test, the patient was not
44
45 having active symptoms of angina.
46
47
48
49
50
51
52
53
54
55
56
57
58
59
60

1
2
3 To the best of our knowledge, this is the first report describing cardiogenic shock occurring
4 following intravenous dipyridamole administration. That said, it is likely that at least some of the
5 patients who suffered myocardial infarctions in the reports by Ranhosky ⁸ and Lette ⁹ also
6 developed cardiogenic shock. Nevertheless, our report highlights an important (and potentially
7 fatal) complication of dipyridamole MPI. Although fatal complications are extremely rare, especially
8 with the advent of aggressive coronary revascularization (Rahnosky's paper ⁸, for example,
9 included patients who were tested between 1978 and 1985 when aggressive coronary intervention
10 was not in common practice) it is essential to be cognizant of the possibility and the presence of
11 appropriate backup services is important to prevent catastrophic events. This is of particular
12 relevance to office-based nuclear cardiology facilities. This report also reemphasizes the fact that
13 patients with active unstable angina should not undergo dipyridamole MPI unless stabilized.
14
15
16
17
18
19
20
21
22
23
24
25
26
27
28
29
30
31
32
33
34
35
36
37
38
39
40
41
42
43
44
45
46
47
48
49
50
51
52
53
54
55
56
57
58
59
60

References

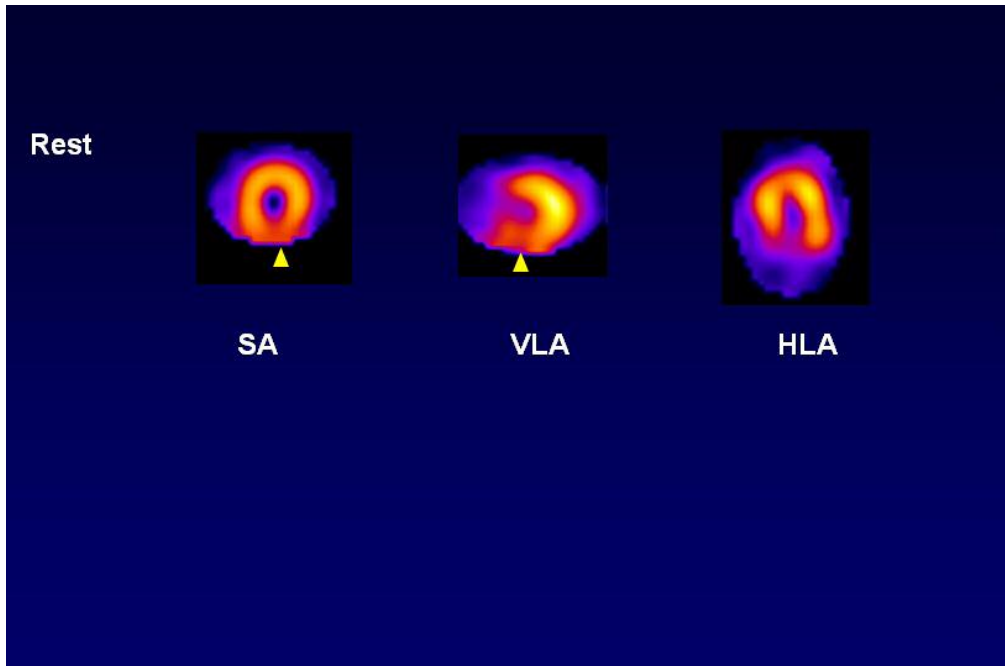
1. Gould KL, Casscells SW, Buja LM, Goff DC. Non-invasive management of coronary artery disease. Report of a meeting at the University of Texas Medical School at Houston. *Lancet* 1995; **346**:750-3.
2. Wilcken DE, Paoloni HJ, Eikens E. Evidence for intravenous dipyridamole (persantin) producing a "coronary steal" effect in the ischaemic myocardium. *Aust N Z J Med* 1971; **1**:8-14.
3. Chambers CE, Brown KA. Dipyridamole-induced ST segment depression during thallium-201 imaging in patients with coronary artery disease: angiographic and hemodynamic determinants. *Journal of the American College of Cardiology* 1988; **12**:37-41.
4. Akinboboye OO, Idris O, Chou RL, Sciacca RR, Cannon PJ, Bergmann SR. Absolute quantitation of coronary steal induced by intravenous dipyridamole. *Journal of the American College of Cardiology* 2001; **37**:109-16.
5. Hansen CL, Williams E. Severe transmural myocardial ischemia after dipyridamole administration implicating coronary steal. *Clin Cardiol* 1998; **21**:293-6.
6. Biddle P, Lanspa TJ, Mohiuddin SM, Malesker MA, Hilleman DE. Myocardial infarction after dipyridamole-assisted thallium-201 imaging. *Dicp* 1989; **23**:665-7.
7. Kwai AH, Jacobson AF, McIntyre KM, Williams WH, Tow DE. Persistent chest pain following oral dipyridamole for thallium 201 myocardial imaging. *Eur J Nucl Med* 1990; **16**:745-6.
8. Ranhosky A, Kempthorne-Rawson J. The safety of intravenous dipyridamole thallium myocardial perfusion imaging. *Circulation* 1990; **81**:1205-1209.
9. Lette J, Tatum JL, Fraser S, et al. Safety of dipyridamole testing in 73,806 patients: the Multicenter Dipyridamole Safety Study. *J Nucl Cardiol* 1995; **2**:3-17.

Conflicts of Interest: None

For Peer Review

1
2
3
4
5
6
7
8
9
10
11
12
13
14
15
16
17
18
19
20
21
22
23
24
25
26
27
28
29
30
31
32
33
34
35
36
37
38
39
40
41
42
43
44
45
46
47
48
49
50
51
52
53
54
55
56
57
58
59
60

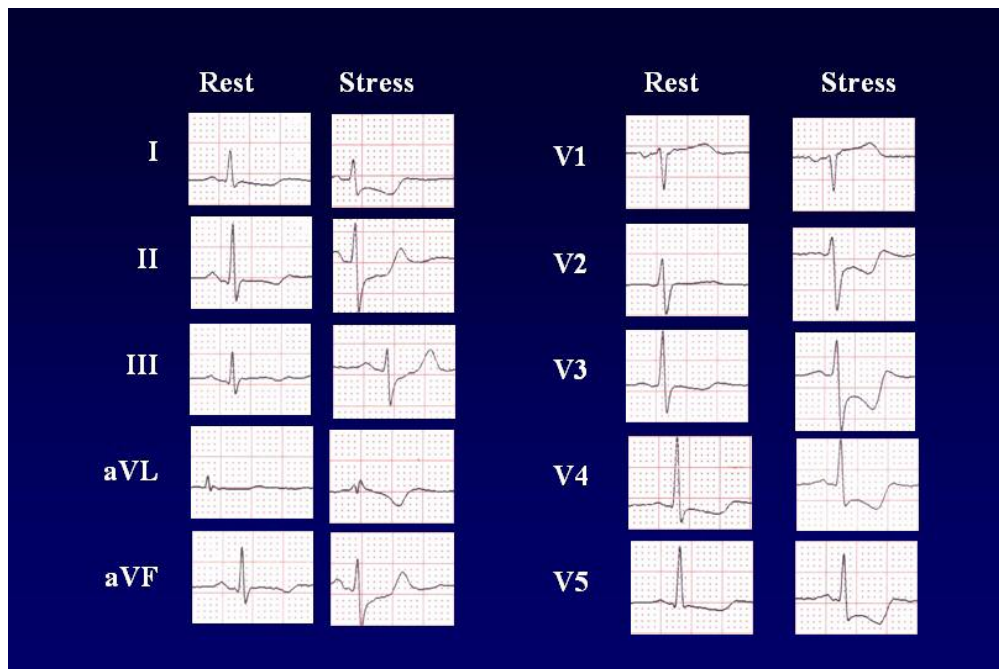
1
2
3
4
5
6
7
8
9
10
11
12
13
14
15
16
17
18
19
20
21
22
23
24
25
26
27
28
29
30
31
32
33
34
35
36
37
38
39
40
41
42
43
44
45
46
47
48
49
50
51
52
53
54
55
56
57
58
59
60



Resting images showing an inferior perfusion defect
285x190mm (72 x 72 DPI)

Review

1
2
3
4
5
6
7
8
9
10
11
12
13
14
15
16
17
18
19
20
21
22
23
24
25
26
27
28
29
30
31
32
33
34
35
36
37
38
39
40
41
42
43
44
45
46
47
48
49
50
51
52
53
54
55
56
57
58
59
60



Baseline and Stress ECG
285x190mm (72 x 72 DPI)

Review