



THE AGA KHAN UNIVERSITY

eCommons@AKU

Section of Neurosurgery

Department of Surgery

November 2003

# Giant choroid plexus papilloma of the third ventricle

A.A. Razzaq  
*Aga Khan University*

Ashfaq A. Razzaq  
*Aga Khan University, ashfaq.wadalawala@aku.edu*

Khalid Chishti  
*Aga Khan University*

Follow this and additional works at: [https://ecommons.aku.edu/pakistan\\_fhs\\_mc\\_surg\\_neurosurg](https://ecommons.aku.edu/pakistan_fhs_mc_surg_neurosurg)



Part of the [Surgery Commons](#)

## Recommended Citation

Razzaq, A. A., Razzaq, A. A., Chishti, K. (2003). Giant choroid plexus papilloma of the third ventricle. *Journal of Pakistan Medical Association*, 53(11), 573-575.

**Available at:** [https://ecommons.aku.edu/pakistan\\_fhs\\_mc\\_surg\\_neurosurg/132](https://ecommons.aku.edu/pakistan_fhs_mc_surg_neurosurg/132)

# Giant Choroid Plexus Papilloma of the Third Ventricle

A. A. Razzaq, K. N. Chishti

Department of Surgery, Section of Neurosurgery, Aga Khan University Medical Centre, Karachi.

## Introduction

Choroid plexus papilloma (CPP) is an uncommon tumour of the central nervous system, accounting for less than 1% of all verified intracranial neoplasms.<sup>1-4</sup> The frequent locations are the lateral ventricle in infants and children and the fourth ventricle in adults.<sup>2</sup> The third ventricle is a rare site for a CPP; only a limited number of CPPs have been reported at this location. To our knowledge, all the reported cases of third ventricular choroid plexus papillomas have ranged from 2-5 cms in size. This report describes the largest choroid plexus papilloma reported in the English literature. This large tumor was removed successfully and the patient remains well without any neurological deficit at two year follow-up.

## Case Report

This 8 month old male infant presented with a two month history of increasing head size, lethargy, decreased activity and inability to sit. Examination revealed an irritable child with a tense anterior fontanelle and head circumference of 45 cm. (greater than ninetieth percentile of normal). Tone was increased in all four activities but there was no paresis. There was bilateral papilloedema. T1 weighted MR scan with contrast showed a homogeneously

enhancing mass within the third ventricle. This mass measured 8x5x5 cm. There was associated hydrocephalus of the lateral ventricles. (Figures 1-3). Cerebral angiography revealed a moderately vascular tumor fed by anterior choroidal artery.

At surgery, a right frontal craniotomy was performed and a transcortical transforaminal route was undertaken to approach the tumor. After entering the right lateral ventricle, a cauliflower-like mass was observed in the lateral ventricle protruding out of the foramen of Monro. There was no attachment to the choroid plexus of the lateral ventricle. The tumor was moderately vascular and after the removal of the lateral ventricular component the procedure was halted due to significant blood loss, with a view to second stage removal. An external ventricular drain was placed. The patient woke up without any neurological deficits. He had focal left sided seizures during the post-op period which were controlled with anti-epileptics.

The post op contrast enhanced CT scan showed bilateral subdural collections and residual tumor within the third ventricle (Figure 4).

The second stage procedure was performed one week later. At operation the previous gyrotomy was reopened and

the remaining tumor was excised from the third ventricle using the dilated foramen of Monro. A subdural external drain was placed and the previous ventricular drain was removed.

After removal of the subdural drain there were persistent subdural collections, therefore a subdural peritoneal shunt was placed 10 days after the second procedure (Figure 5). The child remained well during this time and had no neurological symptoms.

Histological examination showed a papillary lesion comprised of cells arranged in a fibrovascular core and covered by round cells. There was minimal epithelial dysplasia. The diagnosis was benign choroid plexus

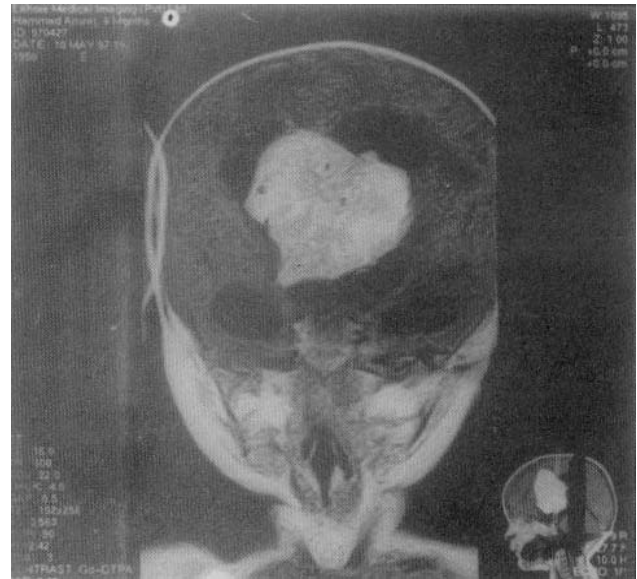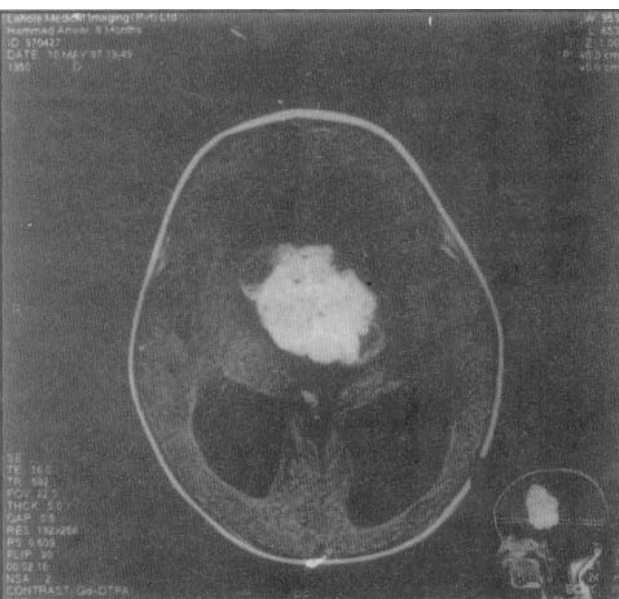
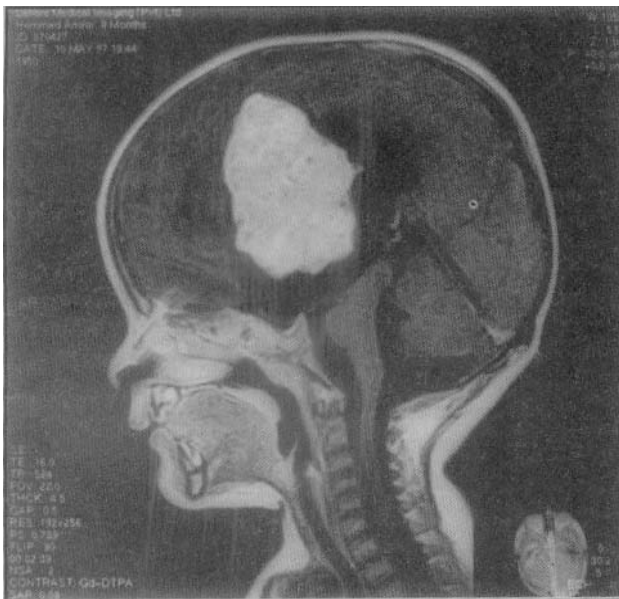


Figure 1-3. T1 weighted contrast enhanced MR scans (sagittal, axial and coronal views), demonstrating a large uniformly enhancing third ventricular tumor, extending upward into the lateral ventricle.

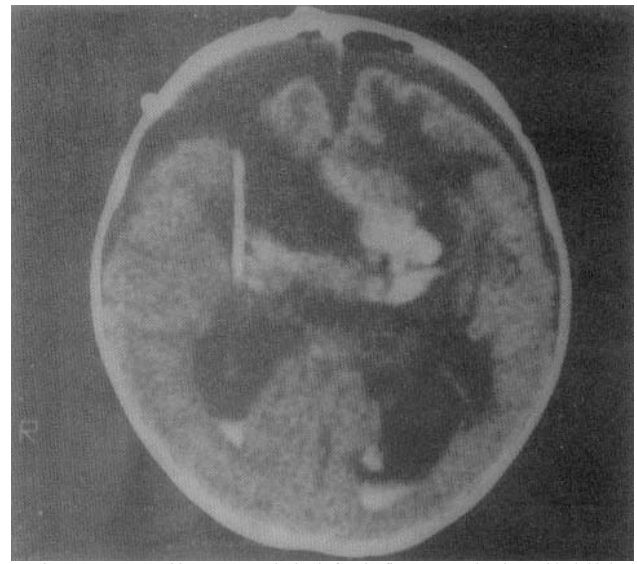


Figure 4. CT scan without contrast obtained after the first surgery, showing residual third ventricular tumour.

papilloma (Figure 6).

Periodic follow-up visits upto two years of age revealed normal development and neurological status of the patient (Figure 7).

## Discussion

Although CPP is one of the neoplasms frequently observed to occur primarily within the ventricular system, it rarely involves the third ventricle; its incidence is 10% or less of all CPPs.<sup>5-7</sup> These lesions typically manifest with macrocephaly and signs of raised intracranial pressure. The size of the tumor has not been reported to be more than 3-5 cms

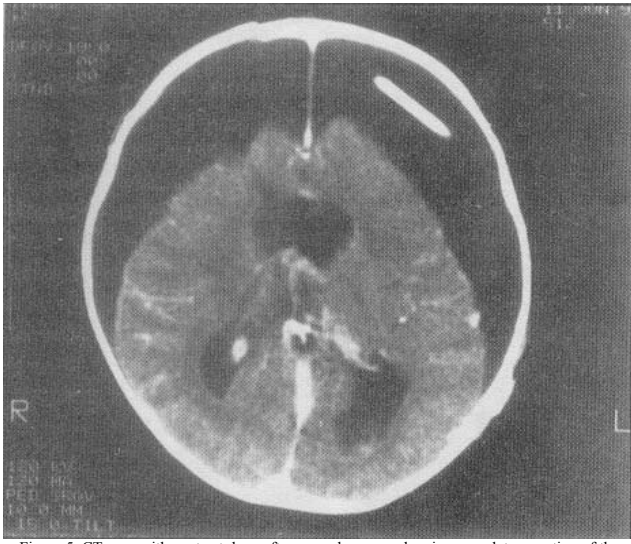


Figure 5. CT scan with contrast done after second surgery showing complete resection of the tumour, but significant bilateral subdural collections.

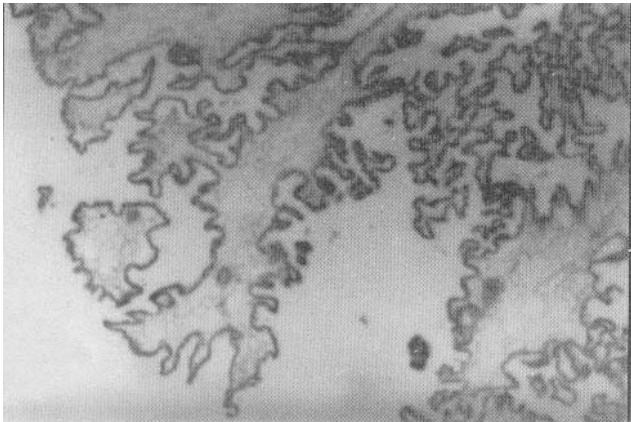


Figure 6. Pathological examination showing tumor arranged in multiple papillary projections with fibrovascular core.

in any report.<sup>1-10</sup> However, our patient had a truly huge tumor measuring 8x5x5 cms. which was protruding through the foramen of Monro into the right lateral ventricle. This tumor was removed by a right frontal transcortical transforaminal route in two stages. The child had a good outcome although the post-operative course was complicated by subdural effusions.

This report stresses the importance of precise surgical debulking in managing large CPPs of the third ventricle. Various approaches have been utilized to approach third ventricular tumors including transcallosal, supracerebellar infratentorial and trans-frontal, transforaminal routes.<sup>8-10</sup> We believe that the approach should be individualized based upon the location, anatomy, size, blood supply and extension through the Foramen of Monro. In this case the tumor was debulked through the transfrontal route as it was protruding into the lateral ventricle through the dilated Foramen of Monro. The entire tumor was




Figure 7. Patient two years after the operation.

excised in two stages. This approach has been previously described.<sup>1</sup>

The size of third ventricular CPPs has not received much attention in the literature previously. To our knowledge this case represents the largest reported CPP to have originated in the third ventricle. The safe removal of such a tumor requires strict adherence to the principles of microsurgical technique and adequate visualization of venous structures especially while working in or near the foramen of Monro. Attention to these details will ensure a good outcome even with such giant choroid plexus papillomas.

## References

1. Apuzzo MLJ, Chikovani OK, Gott PS, et al. Transcallosal, interforaminal approaches for lesions affecting the third ventricle: surgical considerations and consequences. *Neurosurgery* 1982;10:547-54.
2. Azzam NI, Timperley WR. Intracerebral cyst due to ectopic choroid plexus. *J Neurosurg* 1981;55:651-3.
3. Bauer BL, Hellwig D: Intracranial and intraspinal endoscopy. In: Schmidek HH, Sweet WH (eds): operative neurosurgical techniques. Philadelphia: W.B. Saunders, 1995, pp. 695-713.
4. Carmel PW: Tumors in the third ventricle. *Acta Neurochir (Wien)*, 1985;75:136-46.
5. Fortuna A, Celli P, Ferrante L, et al. A review of papillomas of the third ventricle. *J Neurosurg Sci* 1979; 23:61-76.
6. Furness PN, Lowe J, Tarrant GS. Subepithelial basement membrane deposition and intermediate filament expression in choroid plexus neoplasms and ependymomas. *Histopathology* 1990;16:251-5.
7. Gradin WC, TAYLOR C, FRUIN AH. Choroid plexus papilloma of the third ventricle. *Neurosurgery* 1983;12:217-20.
8. Greene RC. Extraventricular and intracerebellar papilloma of the choroid plexus. *J Neuropathol Exp Neurol* 1951;10:204-7.
9. Iwasaki K, Kondo A, Takahashi JB, et al. Intraventricular craniopharyngioma: Report of two cases and review of literature. *Surg Neurol* 1992;38:294-301.
10. Kimura M, Takayasu M, Suzuki Y, et al. Primary choroid plexus papilloma located in the suprasellar region. *Neurosurgery* 1992;31:563-6.