



THE AGA KHAN UNIVERSITY

eCommons@AKU

Department of Biological & Biomedical Sciences

Medical College, Pakistan

January 2014

# Gossypiboma diagnosed fifteen years after a cesarean section: A case report

Abdul Rehman  
*Aga Khan University*

Noor Ul-Ain Baloch  
*Aga Khan University*

Muhammad Awais  
*Aga Khan University*

Follow this and additional works at: [https://ecommons.aku.edu/pakistan\\_fhs\\_mc\\_bbs](https://ecommons.aku.edu/pakistan_fhs_mc_bbs)

 Part of the [Biochemistry Commons](#), and the [Radiology Commons](#)

## Recommended Citation

Rehman, A., Baloch, N. U., Awais, M. (2014). Gossypiboma diagnosed fifteen years after a cesarean section: A case report. *Qatar Medical Journal*, 2014(2), 65-69.

**Available at:** [https://ecommons.aku.edu/pakistan\\_fhs\\_mc\\_bbs/496](https://ecommons.aku.edu/pakistan_fhs_mc_bbs/496)

CASE REPORT

# Gossypiboma diagnosed fifteen years after a cesarean section: A case report

Abdul Rehman<sup>1</sup>, Noor Ul-Ain Baloch<sup>1</sup>, Muhammad Awais<sup>2</sup>

Address for Correspondence:

**Abdul Rehman**

<sup>1</sup>Department of Biological & Biomedical Sciences,  
Aga Khan University, Karachi, Sindh, Pakistan

<sup>2</sup>Department of Radiology, Aga Khan University Hospital,  
Karachi, Sindh, Pakistan

Email: [jmawais@yahoo.com](mailto:jmawais@yahoo.com)

<http://dx.doi.org/10.5339/qmj.2014.12>

Submitted: 27 August 2014

Accepted: 19 September 2014

© 2014 Rehman, Baloch, Awais, licensee Bloomsbury Qatar Foundation Journals. This is an open access article distributed under the terms of the Creative Commons Attribution license CC BY 4.0, which permits unrestricted use, distribution and reproduction in any medium, provided the original work is properly cited.

Cite this article as: Rehman A, Baloch N U, Awais M. Gossypiboma diagnosed fifteen years after a cesarean section: A case report, Qatar Medical Journal 2014;12 <http://dx.doi.org/10.5339/qmj.2014.12>

## ABSTRACT

Gossypiboma, a retained surgical sponge, is a rare complication following any surgical procedure and is primarily a result of human error. Such patients often have vague clinical presentations and the diagnosis often comes as a surprise. We present the case of a 40-year-old woman who had a long-standing history of lower abdominal discomfort. She was diagnosed with a gossypiboma fifteen years after a cesarean section. All general physicians, surgeons and radiologists must be aware of this rare but clinically significant entity.

Keywords: gossypiboma, textiloma, retained surgical sponge, medical errors

## INTRODUCTION

Surgical sponges and gauze retained in the body after a surgical procedure result in a gossypiboma. This term is derived from the Latin word, *gossipium* (cotton) and the Kiswahili word, *boma* (a place of concealment).<sup>1</sup> Being a rare clinical entity, patients often experience symptoms for years before a definitive diagnosis is made. In most such cases, the diagnosis is unexpected and comes as a surprise.<sup>2</sup> Although it is an iatrogenic and preventable entity, it can be a source of significant morbidity for the patient. Several such cases have been reported in the literature up until now. However, physicians seldom consider it in their differential diagnoses. In the case that we present here, a gossypiboma was diagnosed fifteen years following a cesarean section.

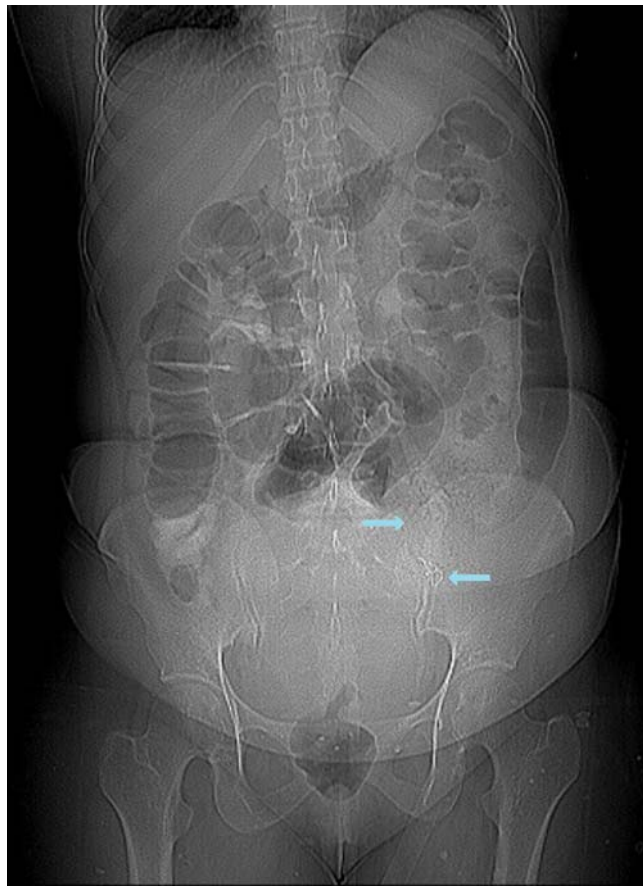
## CASE REPORT

A 40-year-old woman presented to a general physician at our institution with complaints of nausea, loss of appetite and lower abdominal fullness and discomfort. On further inquiry, she revealed that she

had been experiencing these symptoms for the past ten years. She also had occasional bouts of colicky abdominal pain, which were moderate in intensity and often relieved spontaneously. She had reduced bowel movements for the past few years, although stool consistency was reportedly normal. She did not report any urinary or menstrual complaints. She also did not have any history of fever, rash or joint pains. However, she did report a decrease in appetite and weight (3 kg in 5 years). Her past history was unremarkable except for two spontaneous vaginal deliveries and one lower segment caesarean section (LSCS) fifteen years back. This emergency LSCS was performed under general anesthesia at 35 weeks gestation due to placental abruption via a Pfannenstiel incision. She was not taking any drugs and did not have any addictions. On physical examination, she was vitally stable. Her abdominal examination revealed a LSCS scar and some ill-defined lower abdominal fullness. No discrete masses were palpable and per vaginal and digital rectal examinations were unyielding.

The patient had undergone an extensive work-up prior to presentation. Her complete blood counts and routine blood chemistry were unremarkable on most occasions, except for mild microcytic hypochromic anemia. A urine detailed report obtained three days prior to presentation was unremarkable. The patient had undergone ultrasonography of the lower abdomen and pelvis twice in the past, but was unremarkable. She had also undergone esophago-gastroduodenoscopy and colonoscopy, both of which were unremarkable. Based on these available investigations and the lower abdominal fullness noted on physical examination, the decision was made to obtain a CT scan of the abdomen and pelvis. The CT scan revealed a rounded mass lesion in the left lower abdomen with multiple central mottled lucencies and a thin coiled metallic density (Figures 1 and 2). These findings were discussed by the reporting radiologist with the ordering physician and a strong suspicion of a gossypiboma (retained surgical sponge) was raised.

The patient and her family were counseled in detail regarding the situation and the need for removing the foreign body surgically. She was referred to a general surgeon and a shared decision was made to remove the retained gauze. Laparoscopy was performed under general anesthesia using four different ports. After the creation of a pneumoperitoneum, a conglomerate mass was visualized in the left iliac fossa, which was partly adherent to the omentum and

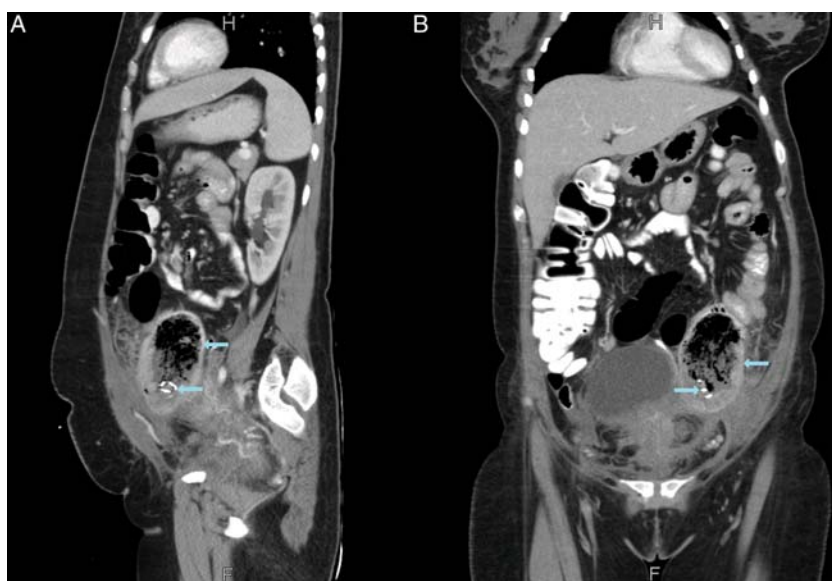


**Figure 1.** A computed tomography scout film of the abdomen and pelvis demonstrating the presence of subtle mottled lucencies in the left iliac fossa along with a thin coiled metallic density projecting over it (arrows).

bowel loops. Irrigation and gentle suctioning was used to separate bowel loops and omentum from the mass. The mass was removed from the left lower side port after enlarging the incision to a slight extent. The removed specimen was sent for pathology. Pathologic evaluation was consistent with a retained foreign body along with surrounding inflammation and fibrosis. Post-operatively, the patient made an uneventful recovery and remained well. At a one year follow-up visit, the patient remains symptom-free and continues to lead a normal life.

## DISCUSSION

Human error is the main etiologic factor for gossypiboma and this clinical entity can be viewed as a preventable medical error.<sup>1</sup> While gossypiboma had first been recognized in 1884,<sup>2</sup> such mishaps continue to happen even today. Use of radiopaque sponges and strict counting of sponges have been



**Figure 2.** Sagittal and coronal plane reconstructions of computed tomography of the abdomen and pelvis demonstrating the presence of a rounded mass lesion in the left lower abdomen with multiple central mottled lucencies and a thin coiled metallic density (arrows).

shown to reduce the incidence of this iatrogenic entity;<sup>3</sup> however, in centers where such protocols are not strictly enforced, many cases continue to occur.<sup>4</sup> It is estimated that a foreign body is retained in 1 of every 1000 to 1500 abdominal surgeries<sup>5</sup> and this may well be a conservative estimate.

Retention of surgical sponges not only increases the morbidity of patients, it also has adverse sequelae for the health professionals involved. Many such cases receive wide media coverage, which can adversely affect the reputation of the operating surgeon.<sup>6</sup> Research has shown that the only two factors consistently associated with gossypiboma are emergency surgery and poor communication amongst the healthcare team.<sup>4</sup> In nearly all such cases, sponge count is erroneously pronounced to be correct at the end of the procedure.<sup>4,7</sup> In addition to these factors, small-scale studies have also implicated 'obesity' as a risk factor for retained surgical sponges.<sup>8</sup> In our case, the patient had undergone an emergency LSCS; moreover, retrospective evaluation of operative notes showed that sponge count was erroneously pronounced as correct at the end of the procedure.

Patients with gossypiboma present with vague clinical symptoms and the diagnosis is most often not anticipated. Site of the retained surgical sponge determines the particular clinical features that a

patient experiences. The most common sites have been reported to be abdomen, pelvis and thorax,<sup>4</sup> while the most common symptoms are pain, discomfort, palpable mass or unexplained fever.<sup>8</sup> In some cases, gossypiboma may be asymptomatic and is only diagnosed incidentally.<sup>1,4,9</sup>

Sponges retained in the abdomen can result in a number of complications. The retained foreign body may incite an acute inflammatory reaction manifesting as acute peritonitis. In more longstanding cases, fibrosis with adhesion formation can precipitate intestinal obstruction. Fistulae may result when sponges result in inflammation of surrounding bowel loops. In some cases, such inflammation may result in erosion of the surrounding bowel wall with migration of the sponge into the bowel lumen.<sup>10</sup>

Diagnosis of gossypiboma is often difficult to make and the attending doctor must have a high index of suspicion. Generally speaking, gossypiboma must be kept in the differential diagnosis of all patients who present with vague clinical features and have a past history of a surgical procedure. In most cases, such symptoms do not have a clear association to the surgical procedure; therefore, temporality of symptoms must be considered carefully. While obtaining a past surgical history, it is important to record the nature of past surgeries (i.e., whether elective or emergency). Despite these clinical caveats, only

radiologic imaging modalities can accurately identify a gossypiboma. A plain abdominal radiograph may be sufficient to visualize a radiopaque marker within the sponge. On CT scans, gossypiboma typically appear as spongiform lesions with mottled lucencies and gas bubbles. A characteristic pattern of calcification can sometimes be noted within the surgical gauze; this is referred to as a "calcified reticulate rind" sign.

Once a gossypiboma is suspected, the attending doctor must inform the patient regarding the incident in a clear, but tactful manner. A coordinated approach between the primary physician, radiologist and a surgeon can help the patient make an informed decision. Surgical removal of the retained foreign object provides definitive cure. Histopathologic examination of the excised specimen is necessary to confirm the diagnosis—this has medicolegal importance as well. Most patients continue to live a healthy life after removal of the retained sponge.

Prevention is far better than cure for gossypiboma.<sup>6</sup> Numerous strategies have been proposed to prevent such mishaps. Adherence to sponge counting protocols can be easily ensured; however, it is highly dependent on human performance and susceptible to human errors.<sup>7</sup> Novel methods of preventing gossypiboma are currently under study. The use of a barcode system to count sponges has been proposed, which would ensure that no sponge has been retained inside the body. Another novel method involves the use of radiofrequency identification microchips. These microchips would produce radiofrequency signals that can be detected by a handheld scanner. Nevertheless, in less developed centers, raising awareness about this issue, implementing sponge counting protocols and improving communication among members of the healthcare team can effectively safeguard against such incidents.

## CONCLUSION

Gossypiboma is a rare iatrogenic disorder with substantial morbidity and significant medicolegal implications. Such incidents are wholly preventable and prevention is far better than cure. Emergency nature of surgery and poor communication among members of the healthcare team are strongly associated with the possibility of a retained surgical sponge. Most patients with this disorder present with vague clinical features. Therefore, all general physicians, surgeons and radiologists must be aware of this rare clinical entity to ensure patient safety and prevent iatrogenic morbidity.

## ACKNOWLEDGEMENTS

None

## CONFLICT OF INTERESTS

The authors of this manuscript declare no conflict of interests regarding the findings reported herein.

## SOURCE OF FUNDING

No source of funding was received or sought for the preparation of this manuscript.

## ETHICAL CONSIDERATIONS

Written informed consent was obtained from the patient for the preparation of this manuscript.

## CONTRIBUTIONS OF AUTHORS

AR was involved in the direct care of this patient. AR wrote down the first part of the manuscript (case presentation), while NB and MA performed a review of literature and wrote down the discussion. The manuscript was read and approved by all authors in its current form.

## REFERENCES

1. Yildirim S, Tarim A, Nursal TZ, Yildirim T, Caliskan K, Torer N, Karagulle E, Noyan T, Moray G, Haberal M. Retained surgical sponge (gossypiboma) after intraabdominal or retroperitoneal surgery: 14 cases treated at a single center. *Langenbecks Arch Surg.* 2006;391:390–395.
2. Wilson CP. Foreign bodies left in the abdomen after laparotomy. *Gynecol Tr.* 1884;9:109–112.
3. Christian CK, Gustafson ML, Roth EM, Sheridan TB, Gandhi TK, Dwyer K, Zinner MJ, Dierks MM. A prospective study of patient safety in the operating room. *Surgery* 2006;139:159–173.
4. Wan W, Le T, Riskin L, Macario A. Improving safety in the operating room: a systematic literature review of retained surgical sponges. *Curr Opin Anesthesiol.* 2009;22:207–214.
5. Hyslop JW, Maull KI. Natural history of the retained surgical sponge. *South Med J.* 1982;75:657–660.

6. Gawande AA, Studdert DM, Orav EJ, Brennan TA, Zinner MJ. Risk factors for retained instruments and sponges after surgery. *N Engl J Med*. 2003;348:229–235.
7. Greenberg CC, Regenbogen SE, Lipsitz SR, Diaz-Flores R, Gawande AA. The frequency and significance of discrepancies in the surgical count. *Ann Surg*. 2008;248:337–341.
8. Bani-Hani KE, Gharaibeh KA, Yagha RJ. Retained surgical sponges (gossypiboma). *Asian J Surg*. 2005;28:109–115.
9. Cevik I, Dillioglugil O, Ozveri H, Akdas A. Asymptomatic retained surgical gauze towel diagnosed 32 years after nephrectomy. *Int Urol Nephrol*. 2008;40:885–888.
10. Choi JW, Lee CH, Kim KA, Park CM, Kim JY. Transmural migration of surgical sponge evacuated by defecation: mimicking an intraperitoneal gossypiboma. *Korean J Radiol*. 2006;7:212–214.