



THE AGA KHAN UNIVERSITY

eCommons@AKU

Section of Gastroenterology

Department of Medicine

10-1-2017

De novo descending aorta thrombus in a patient with metastatic colorectal cancer: A case report

Om Parkash

Aga Khan University, om.parkash@aku.edu

Adil Ayub

Aga Khan University

Buria Naeem

Aga Khan University

Saeed Hamid

Aga Khan University, saeed.hamid@aku.edu

Follow this and additional works at: https://ecommons.aku.edu/pakistan_fhs_mc_med_gastroenterol



Part of the [Gastroenterology Commons](#)

Recommended Citation

Parkash, O., Ayub, A., Naeem, B., Hamid, S. (2017). De novo descending aorta thrombus in a patient with metastatic colorectal cancer: A case report. *JPMA. The Journal of the Pakistan Medical Association*, 67(10), 1606-1608.

Available at: https://ecommons.aku.edu/pakistan_fhs_mc_med_gastroenterol/239

De novo descending aorta thrombus in a patient with metastatic colorectal cancer: A case report

Om Parkash, Adil Ayub, Buria Naeem, Saeed Hamid

Abstract

Thromboembolic events in patients with cancer are frequently reported in literature and usually involve the venous circulation. De novo thrombus formation in the arterial system without any underlying atherosclerosis, dissection or aneurysm is extremely rare. We report the case of a patient with metastatic colorectal carcinoma who developed a thrombus in the descending aorta without any intervention or risk factors. The patient presented with non-specific gastrointestinal symptoms. A CT scan revealed an aortic thrombus obstructing 70% of the lumen. She opted for no treatment of her thrombus and was later complicated by extensive lower limb emboli. Patients with aortic thrombosis usually present with subtle symptoms which may be underestimated by both the patient and the physician. A high index of suspicion is required for early recognition and prevention of complications.

Keywords: Thrombus, Arterial, Descending aorta, Cancer, Colorectal Carcinoma, Case report.

Introduction

The increased risk of thromboembolic events in malignancy is well documented in literature and has many causes including chemotherapy, surgical intervention, immobilization and malignancy induced hypercoagulability.¹ An aortic thrombus however is extremely rare in patients with cancer. In the absence of underlying atherosclerosis, dissection and aneurysm, it may be related to factors predisposing to the formation of clots such as sepsis, autoimmune disease, disseminated intravascular thrombosis and polycythemia.^{2,3} We report the case of a patient with

metastatic colorectal cancer who was found to have an incidental descending aorta thrombus without any predisposing factors. To our knowledge, there is no such case documented in literature.

Case Presentation

A 55-year-old lady, nondiabetic, nonhypertensive presented to our emergency department (Aga Khan University, Karachi, Pakistan; August, 2010) with abdominal distension and constipation. She had recently presented with complaints of bleeding per rectum for 1 month. Colonoscopy at that time revealed a rectal mass 5 cm from the anal verge and biopsy confirmed the

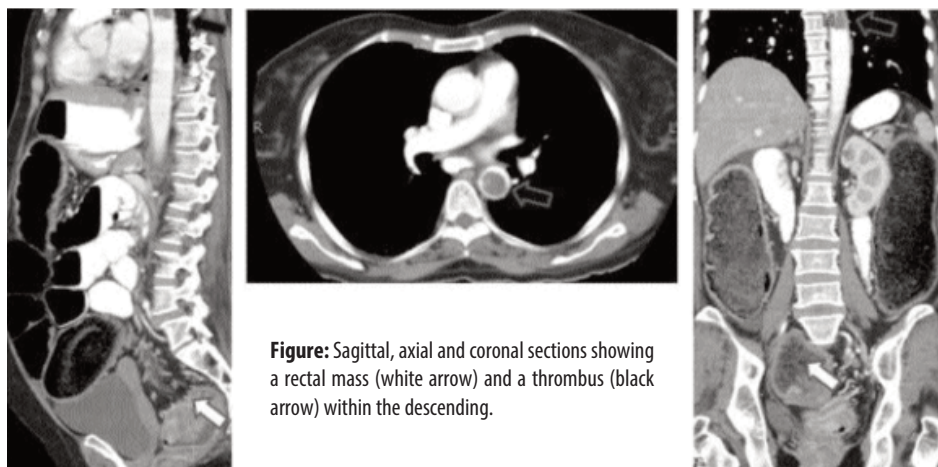


Figure: Sagittal, axial and coronal sections showing a rectal mass (white arrow) and a thrombus (black arrow) within the descending.

diagnosis of a well-differentiated adenocarcinoma for which she had refused any treatment. Abdominal X-ray at the current visit showed colonic obstruction with distended bowel loops. CT scan revealed a rectal mass with liver metastasis and an incidental finding of a descending aorta thrombus, obstructing 70% of the lumen (Figure).

Her Cardiovascular examination was unremarkable. There was no evidence of aneurysm, dissection or atherosclerosis. Further laboratory work-up for autoimmune and coagulation disorders, such as anti-phospholipid syndrome, protein-S, protein-C and anti-thrombin III deficiency was negative. There was no

.....
Aga Khan University Hospital, Karachi, Pakistan.

Correspondence: Om Parkash. Email: om.parkash@aku.edu

significant cardiovascular history. EKG was normal and transthoracic echography didn't reveal any valvular lesions or chamber abnormalities.

The patient was shifted to the operating room and a diverting colostomy was performed. A sigmoidoscopy ± stenting was planned, but she refused any further treatment and was discharged on palliative care. Three months later, she presented with severe leg swelling and a doppler ultrasound examination revealed extensive echogenic emboli involving whole of the left lower limb. Unfractionated heparin was started which was stopped later due to patient's wish to discontinue any form of treatment. Her condition deteriorated and she died 2-weeks later of multiple organ failure.

Discussion

A review of literature shows only a few cases of aortic thrombosis in cancer patients. Out of these patients, all except two had received chemotherapy for their primary disease which is a known predisposing factor for thromboembolic disease.³ Among these two cases that developed de novo thrombosis, one patient was a known case of protein c and protein s deficiency⁴ and the other one⁵ underwent invasive pelvic surgery, both identified as potential causes for the thrombus formation. In our patient, no risk factors or interventions were identified for the formation of thrombus.

Recognition of aortic thrombosis is important because it constitutes a dangerous condition and exposes the patient to potentially preventable complications such as peripheral embolism, ischaemia and angina. Patients usually present with subtle or no symptoms which may be underestimated by both the patient and the physician.⁶ This was seen in the present case where the patient refused any management for the aortic thrombus. The only identifiable source of her lower extremity emboli was the thrombus in the descending aorta.

Complications related to aortic thrombus are preventable and require prompt recognition and management. Long term anticoagulation with unfractionated heparin is most widely accepted as a first line therapy.⁷ Surgical intervention for thrombus resection and catheter guided thrombolysis are reserved for patients with contraindications to long-term-anticoagulation therapy.⁶

This case also highlights the importance of identifying and counselling patients prone to leaving against

medical advice. Limited work has been done regarding these patients and various factors have been identified that increase the risk of leaving care against medical advice. These factors include absence of medical insurance, trauma admission, increased age, substance abuse and mental illnesses.⁸ All these factors are important to address because these patients have higher readmission and mortality rates and understanding the underlying cause of leaving may result in improved care and outcomes. The effort begins with recognizing patients who are at risk and targeting these patients for early intervention and advice. Clark et al⁹ offered a systematic approach called AIMED (includes risk assessment, determination of decision-making capacity, investigation of patient motivations, mitigation of harm and clear communication) that can minimize the harm and ethical lapses and result in better and safer patient outcomes. Therefore, recognizing known risk factors that predict high likelihood of against medical advice discharge and targeting these patients for early intervention may be beneficial. In addition, nurses and medical students can play a vital role by providing information about their disease and prognosis, conveying concerns about possible issues after discharge and stressing on the fact that they can always return back for additional care.¹⁰

Conclusion

Aortic thrombosis in malignancy is extremely rare. We report the case of an elderly woman developed a thrombus in the descending aorta without any intervention or risk factors and therefore such cases should be anticipated in cancer patients without any resection, chemotherapy, risk factors or interventions. It is imperative for the clinician to have a high level of clinical suspicion for vascular complications in patients with aortic thrombosis. Delays in diagnosis may have a significant impact on morbidity and outcomes.

Disclaimer: "All authors would like to undertake that the manuscript has not been published or under editorial review for publication elsewhere. All authors have read and approved the submission. None of the authors have any conflict of interests to declare. The paper was presented at the 6th Health Sciences Research Assembly 2011, Aga Khan University, Karachi (Abstract ID 2.13)"

Conflict of Interest: None.

Funding Source: None.

References

1. Fernandes DD, Louzada ML, Souza CA, Matzinger F. Acute aortic

- thrombosis in patients receiving cisplatin-based chemotherapy. *Curr Oncol* 2011, 18: e97-100.
2. Saxena R, Kumar MV, Kumar S, Gharde P, Talwar S, Choudhary SK. Thrombus in the Proximal Aorta: Cardiopulmonary Bypass Strategy and Surgical Management. *Ann Thorac Surg* 2015; 100: 311-3.
 3. Poiree S, Monnier-Cholley L, Tubiana JM, Arrive L. Acute abdominal aortic thrombosis in cancer patients. *Abdom Imaging* 2004; 29: 511-3.
 4. Serck LC, Cogbill TH. Aortic, celiac axis, and superior mesenteric artery thrombosis associated with sigmoid colon adenocarcinoma and hypercoagulable state. *Vasc Endovasc Surg* 2009; 43: 284-5.
 5. Casillas S, Nicholson JD. Aortic thrombosis after low anterior resection for rectal cancer: report of a case. *Dis Colon Rectum* 2002; 45: 829-32.
 6. Tsilimparis N, Hanack U, Pisimisis G, Yousefi S, Wintzer C, Ruckert RI. Thrombus in the non-aneurysmal, non-atherosclerotic descending thoracic aorta -- an unusual source of arterial embolism. *Eur J Vasc Endovasc Surg* 2011; 41: 450-7.
 7. Sawada T, Shimokawa T. Giant thrombus in the ascending aorta that caused systemic embolism. *Interact Cardiovasc Thorac Surg* 2011; 12: 1048-50.
 8. Lee CA, Cho JP, Choi SC, Kim HH, Park JO. Patients who leave the emergency department against medical advice. *Clin Exp Emerg Med* 2016; 3: 88-94.
 9. Clark MA, Abbott JT, Adyanthaya T. Ethics seminars: a best-practice approach to navigating the against-medical-advice discharge. *Academic emergency medicine : official journal of the Society for Academic Emerg Med* 2014; 21: 1050-7.
 10. Bartley MK. Against medical advice. *J Trauma Nurs* 2014, 21: 314-8.
-