



THE AGA KHAN UNIVERSITY

eCommons@AKU

Section of Otolaryngology, Head & Neck Surgery

Department of Surgery

January 2013

Tuberculosis verrucosa cutis in a patient with keloid over ear lobule

Muhammad Sohail Halim

Sadaf Qadeer Ahmed

Montasir Junaid

Muhammad Rizwan Bashir

Follow this and additional works at: https://ecommons.aku.edu/pakistan_fhs_mc_surg_otolaryngol_head_neck

 Part of the [Otolaryngology Commons](#), and the [Surgery Commons](#)

Recommended Citation

Halim, M. S., Ahmed, S. Q., Junaid, M., Bashir, M. R. (2013). Tuberculosis verrucosa cutis in a patient with keloid over ear lobule. *BMJ Case Reports*, 2013.

Available at: https://ecommons.aku.edu/pakistan_fhs_mc_surg_otolaryngol_head_neck/84

CASE REPORT

Hibernoma larynx with large multinodular goitre: unusual airway challenge

Haissan Iftikhar, Moghira Iqbaluddin Siddiqui

Section of Otolaryngology,
Department of Surgery, Aga
Khan University Hospital,
Karachi, Sindh, Pakistan

Correspondence to
Dr Moghira Iqbaluddin
Siddiqui, moghira.siddiqui@
aku.edu

Accepted 20 July 2015

SUMMARY

A 56-year-old man presented with a 6-month history of progressively increasing neck swelling, dysphagia and hoarseness of voice. CT scan revealed multi-nodular goitre and also showed a lesion in the supraglottis. It also showed another lesion in the supraglottis. Fine-needle aspiration cytology of thyroid revealed follicular cells. Routine flexible laryngoscopy was performed to evaluate vocal cord function; however, we found a smooth well-defined lesion just above the glottis, obstructing the direct view of the vocal cords, and an endangered airway. A provisional diagnosis of a laryngeal cyst was made. With all necessary precautions intubation was performed with a bougie and a reinforced endotracheal tube was inserted. Total thyroidectomy was performed first. With direct suspension laryngoscopy an attempt was made to deliver the laryngeal lesion, however, the lesion could not be removed. A suprahyoid lateral pharyngotomy was performed to deliver the lesion. Histopathology of the lesion revealed hibernoma.

BACKGROUND

What makes our case special is the concomitant laryngeal mass with a multinodular goitre pushing the epiglottis anteriorly thereby obstructing the airway for intubation. Induction of anaesthesia was a challenge, as the airway was not accessible transorally due to this lesion, and a large thyroid mass was obscuring it anteriorly.

CASE PRESENTATION

A 56-year-old man presented to our outpatient clinic with a 6-month history of progressively increasing neck swelling and difficulty in swallowing. The patient also reported hoarseness and pain on raising his voice. He had difficulty in breathing on lying down. CT scan was performed 5 months earlier outside our institute, which revealed an enlarged thyroid gland with multiple nodules; fine-needle aspiration cytology revealed follicular cells of thyroid with no atypical cells seen. CT scan also showed a cystic lesion causing a narrowed airway in the supraglottic area (figure 1). On examination, a multinodular thyroid swelling, around 4×4 cm bilaterally, was noted. Flexible laryngoscopy was performed at our clinic, which revealed a smooth, well-defined lesion just above the glottis, more on the right side, obstructing the direct view of the vocal cords. The patient was electively taken for surgery. We had a an endangered airway with this large lesion obstructing the glottis, thus making intubation difficult; in any case, a quick

tracheostomy was not possible owing to a huge multinodular goitre. With all necessary precautions, intubation was performed with a bougie and a reinforced endotracheal tube was inserted. Total thyroidectomy was performed first before addressing the laryngeal lesion so as to get access to the trachea before attempting excision of the laryngeal mass. Direct suspension laryngoscopy was performed to excise the lesion; however, we were surprised that it was not cystic; rather, it appeared firm and was too large to be delivered orally. Lateral pharyngotomy (figure 2) was performed and a smooth yellowish lesion was seen just above the glottis (figure 3), which was excised successfully with no significant bleeding; the bilateral vocal cords were visible and mobile (figure 4). Tracheostomy was performed to maintain the airway as oedema was expected in the operative site. The thyroid gland along with the excised lesion is seen in figure 5. Histopathology of the lesion revealed hibernoma. The patient was discharged on fifth postoperative day. Oedema at supraglottis persisted for 3 weeks before we were able to decannulate him.

INVESTIGATIONS

CT scan showed a multinodular goitre and was suggestive of a cystic lesion in the laryngeal area. Flexible laryngoscopy was performed at our clinic, which revealed a smooth, well-defined lesion just above the glottis, more on the right side, obstructing the direct view of the vocal cords.

DIFFERENTIAL DIAGNOSIS

- ▶ Pharyngeal cyst
- ▶ Lipoma
- ▶ Mucocoele

TREATMENT

Total thyroidectomy was performed. Lateral pharyngotomy was performed to deliver the hibernoma from supraglottis. Furthermore, tracheostomy was performed to maintain a safe airway.

OUTCOME AND FOLLOW-UP

The patient was discharged on fifth postoperative day and was decannulated 3 weeks later. He remained healthy thereafter, with no morbidity.

DISCUSSION

Hibernomas were first described by Merkel in 1906, but remained unnamed until Grey,¹ in 1914, named them 'Hibernomas' owing to their resemblance to the fat found in hibernating animals. Their incidence in the reported literature is very



CrossMark

To cite: Iftikhar H, Siddiqui MI. *BMJ Case Rep* Published online: [please include Day Month Year] doi:10.1136/bcr-2015-210976

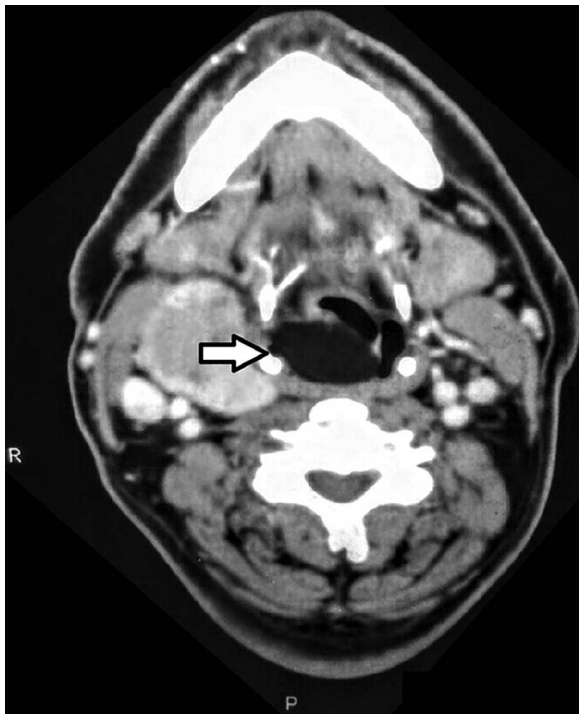


Figure 1 CT scan. Arrow showing lesion in the supraglottis compromising airway. The right lobe of multi-nodular goitre is also seen.

low, with very few cases described in the head and neck region.² To the best of our knowledge, only four previous cases of hibernoma in the larynx have been described in the literature.²

Hibernomas appear in regions of fetal brown fat deposits such as on the back, thorax, axilla and retroperitoneum; however, they have also been reported in regions devoid of

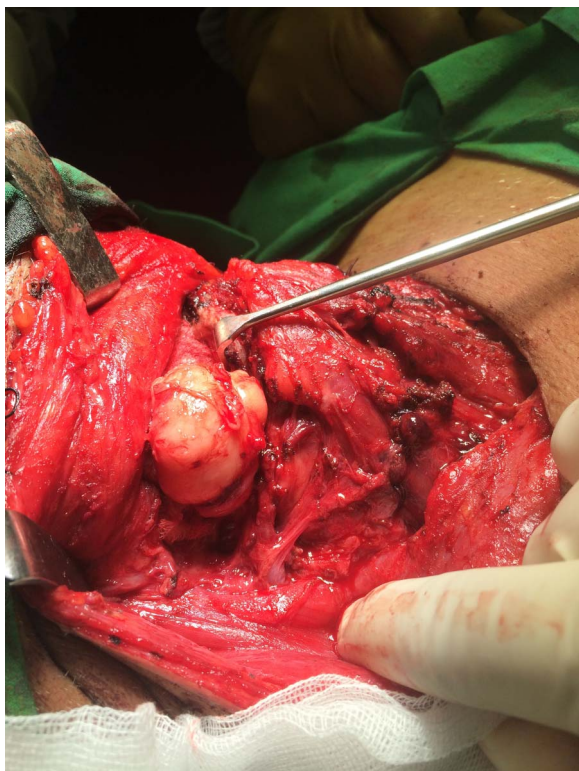


Figure 2 Supra glottic lesion delivered through lateral pharyngotomy.

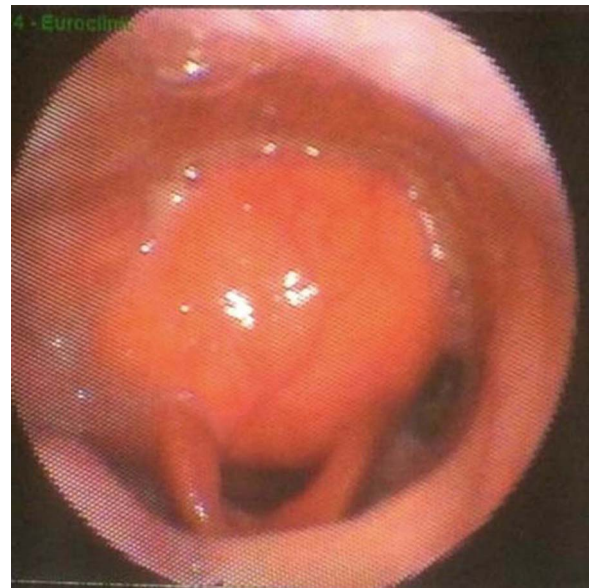

Figure 3 Lesion seen in supraglottis with flexible laryngoscope.

brown fat such as popliteal fossa and thigh.³ There are two theories linked to the origin of hibernomas, the first suggests remnants of brown fat dispersed in the body from where they grow, the other suggests a transformation of white fat into brown fat and its neoplastic growth.⁴ There are marked differences between the two types of fat, the white fat stores energy whereas brown fat regulates non-shivering thermogenesis.² Brown fat is highly vascular, which is similar to appearances of a hibernoma. Brown fat contains abundant mitochondria and a unique uncoupling protein in its inner membrane that allows unrestrained fuel consumption and thermogenesis as a byproduct.²

Hibernomas predominantly affect men, as suggested by the largest study of hibernomas, including 170 patients, with 58%

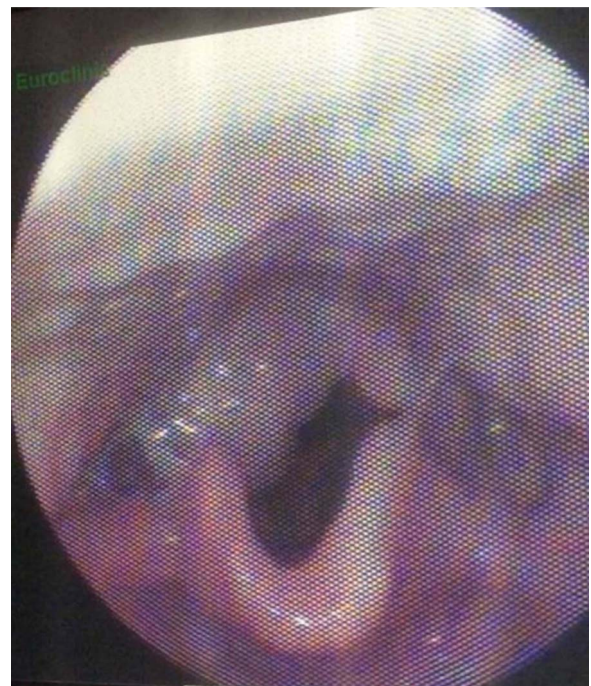


Figure 4 Visualization of larynx post excision of lesion.

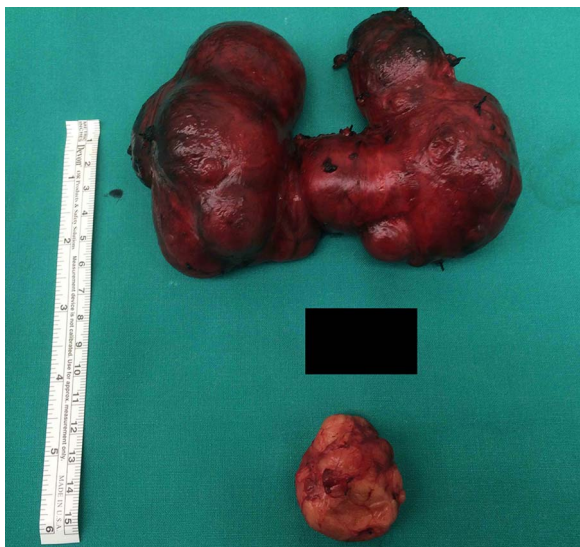

Figure 5 Lesion (hibernoma) below and thyroid above.

being found in men and 42% in females.⁵ The peak incidence is in the fourth decade of life with the earliest case in a 6 weeksold.⁴ The most common locations are the thigh, shoulder and back.⁵ Hibernomas present only when large enough to disturb the surrounding anatomy.^{6,7} Clinically, they are firm, slowly growing, non-tender masses.³ MRI is the imaging modality of choice; it shows a heterogeneous enhancing mass with focal areas of hypointensity and internal septations. CT scan reveals them as contrast-enhancing lesions that are well circumscribed.² They are distinguished from lipoma by the presence of internal vessels and fibrous bands.⁸ Positron-emission tomography reveals a standardised uptake value between 9 and 11, which is higher than in lipomas and liposarcomas, where values are lower than 2, and 2–9, respectively.⁹ Four histological variants of hibernoma have been described, namely, typical, myxoid, lipoma-like and spindle cell.^{5,10–13} The myxoid type is exclusively seen in the head and neck region.¹⁴

Hibernoma is a benign tumour; however, there has been a reported case of hibernoma with an infiltrative pattern and cellular atypia,¹⁵ areas of hibernoma and areas consistent with a well-differentiated liposarcoma. Work up in a patient with a suspected fat-containing lesion includes complete history and examination with imaging; fine-needle aspiration cytology is non-diagnostic and core biopsy is discouraged due to the potential of haemorrhage owing to its internal vascularity,⁸ as also reported in one case leading to excessive bleeding.¹⁶

What makes our case special is its the presence of simultaneous lesions both obstructing the airway. Induction of anaesthesia was a challenge as the airway was not accessible transorally due to this lesion, and a large thyroid mass was covering it anteriorly; an emergency tracheostomy would have been difficult. This highlights the importance of preoperative

laryngoscopy in clinic, which can detect any abnormality in the upper airway besides providing information about vocal fold mobility. This information is also useful to the anaesthesiologist, to help plan a safe intubation.

Learning points

- ▶ Careful planning and measures should be taken preoperatively to ensure successful intubation.
- ▶ Lesions appearing cystic on laryngoscopy may turn out solid and one should be ready to perform pharyngotomy if needed.
- ▶ Tracheostomy should be carried out to avoid airway compromise in such cases secondary to oedema at the site of surgery.

Contributors HI was responsible for the literature review and complete write-up of the case report. MIS did the final editing and reviewed the case report.

Competing interests None declared.

Patient consent Obtained.

Provenance and peer review Not commissioned; externally peer reviewed.

REFERENCES

- 1 Abemayor E, McClean PH, Cobb CJ, et al. Hibernomas of the head and neck. *Head Neck Surg* 1987;9:362–7.
- 2 Cain RB, Zarka MA, Hinni ML. Laryngeal hibernoma: case series of a rare tumor. *Head Neck* 2014;36:E39–43.
- 3 Dagher W, Fedore L, Wein RO. Hibernoma presenting as an asymptomatic neck mass. *Am J Otolaryngol* 2013;34:755–6.
- 4 Minni A, Barbaro M, Vitolo D, et al. Hibernoma of the para-glottic space: an unusual tumour of the larynx. *Acta Otorhinolaryngol Ital* 2008;28:141–3.
- 5 Furlong MA, Fanburg-Smith JC, Miettinen M. The morphologic spectrum of hibernoma: a clinicopathologic study of 170 cases. *Am J Surg Pathol* 2001;25:809–14.
- 6 Carinci F, Carls FP, Pelucchi S, et al. Hibernoma of the neck. *J Craniofac Surg* 2001;12:284–6.
- 7 da Motta AC, Tunkel DE, Westra WH, et al. Imaging findings of a hibernoma of the neck. *AJNR Am J Neuroradiol* 2006;27:1658–9.
- 8 Smith JC, Barnes EL Jr, Fukui MB, et al. Pathology forum: quiz case 2. Diagnosis: hibernoma *Arch Otolaryngol Head Neck Surg* 2000;126:1154; discussion 1158–9.
- 9 Tsuchiya T, Osanai T, Ishikawa A, et al. Hibernomas show intense accumulation of FDG positron emission tomography. *J Comput Assist Tomogr* 2006;30:333–6.
- 10 Seemayer TA, Knaack J, Wang NS, et al. On the ultrastructure of hibernoma. *Cancer* 1975;36:1785–93.
- 11 Dardick I. Hibernoma: a possible model of brown fat histogenesis. *Hum Pathol* 1978;9:321–9.
- 12 Cox RW. Hibernoma: the lipoma of immature adipose tissue. *J Pathol Bacteriol* 1954;68:511–18.
- 13 Hashimoto CH, Cobb CJ. Cytodiagnosis of hibernoma: a case report. *Diagn Cytopathol* 1987;3:326–9.
- 14 Chiriac LR, Dekmezian RH, Ayala AG. Characterization of the myxoid variant of hibernoma. *Ann Diagn Pathol* 2006;10:104–6.
- 15 Enterline HT, Lowry LD, Richman AV. Does malignant hibernoma exist? *Am J Surg Pathol* 1979;3:265–72.
- 16 Lung RJ, Lapidus S, Miller SH, et al. Hibernoma: report of two cases. *J Surg Oncol* 1977;9:563–6.

Copyright 2015 BMJ Publishing Group. All rights reserved. For permission to reuse any of this content visit <http://group.bmj.com/group/rights-licensing/permissions>.
BMJ Case Report Fellows may re-use this article for personal use and teaching without any further permission.

Become a Fellow of BMJ Case Reports today and you can:

- ▶ Submit as many cases as you like
- ▶ Enjoy fast sympathetic peer review and rapid publication of accepted articles
- ▶ Access all the published articles
- ▶ Re-use any of the published material for personal use and teaching without further permission

For information on Institutional Fellowships contact consortiasales@bmjgroup.com

Visit casereports.bmj.com for more articles like this and to become a Fellow