



THE AGA KHAN UNIVERSITY

eCommons@AKU

Section of Haematology/Oncology

Department of Medicine

March 2018

Treatment options for Primary CNS Lymphoma

Abid Laghari

Aga Khan University, abid.laghari@aku.edu

Syed Ijlal Ahmed

Aga Khan University

Adnan Jabbar

Aga Khan University, adnan.jabbar@aku.edu

Muhammad Shahzad Shamim

Aga Khan University, shahzad.shamim@aku.edu

Follow this and additional works at: https://ecommons.aku.edu/pakistan_fhs_mc_med_haematol_oncol



Part of the [Cardiology Commons](#), [Oncology Commons](#), and the [Surgery Commons](#)

Recommended Citation

Laghari, A., Ahmed, S. I., Jabbar, A., Shamim, M. (2018). Treatment options for Primary CNS Lymphoma. *JPMA. The Journal of the Pakistan Medical Association*, 68(3), 499-500.

Available at: https://ecommons.aku.edu/pakistan_fhs_mc_med_haematol_oncol/40

Treatment options for Primary CNS Lymphoma

Altaf Ali Laghari, Syed Ijlal Ahmed, Adnan Jabbar, Muhammad Shahzad Shamim

Abstract

Primary CNS lymphoma (PCNSL) is a rare and aggressive brain tumour that is uniformly fatal. The rarity of the disease and the poor response to treatment makes it difficult to reach a consensus with regards to treatment options. In this review, the authors have discussed different treatment modalities used in the management of PCNSL including chemotherapy, surgery and radiation, as well as the results of recent clinical trials on treatment options for PCNSL.

Keywords: Primary CNS Lymphoma, Cerebral malignancy, Chemotherapy, Radiotherapy

Introduction

The incidence of primary CNS lymphoma (PCNSL) has been on the rise since the 1970s, even in immuno-competent patients. The risk is 2-6% in patients with acquired immunodeficiency syndrome, and will probably increase with improving life expectancy in these patients. Transplant patients have a cumulative risk of 1-5% for developing PCNSL. Similarly, patients with congenital immune deficiency carry a risk of 4%. Moreover, PCNSL may also present as a secondary malignancy. In addition to age and performance status, which are well known prognostic factors, symptoms, tumour volume, presence of meningeal dissemination and serum LDH level also significantly influence survival in these patients.¹ Chemo-radiation therapy has remained the mainstay of management in patients with PCNSL and is associated with reasonable efficacy but with high incidence of neurotoxicity. As a consequence, a difficulty in PCNSL treatment is the choice between strategies designed to intensify therapy to improve the cure rate, versus strategies of treatment de-escalation to avoid severe neurotoxicity.² In this review, the authors have discussed the various options for the management of PCNSL including chemotherapy, surgery and radiation therapy, alone or in combination.

Review of Evidence

Primary CNS lymphoma was conventionally treated by

.....
Aga Khan University Hospital, Karachi, Pakistan.

Correspondence: Muhammad Shahzad Shamim.

Email: shahzad.shamim@aku.edu

corticosteroids and whole brain radiotherapy (WBRT). In 1990, Deangelis et al., introduced a protocol that included intrathecal and systemic methotrexate along with cranial radiotherapy. This vigorous multi-modality regimen showed improved survival rate over conventional therapy.³ Ferreri et al., based their phase II trial on MATILDE regimen which included high dose methotrexate combined with CNS penetrating chemotherapeutic agents (cytarabine, idarubicin and thiotepa) followed by response tailored radiotherapy. They concluded that this regimen increased the survival with reduction in neurological adverse effects of WBRT and intrathecal chemotherapy.⁴ Follow up of this trial also supported the initial findings and suggested an improvement in disease remission at 12 years.⁵ In another study, authors concluded that intra-venous nimustine (ACNU), a drug that crosses the blood brain barrier, combined with WBRT improved the survival of immunocompetent patients with PCNSL. However, it was associated with bone marrow suppression and late onset neurotoxicity especially in elderly population.⁶

Ghesquieres et al., in a prospective multicenter trial also showed that combination therapy in the form of C5R protocol (methotrexate, doxorubicin, vincristine, cyclophosphamide and cytarabine with XRT) is a better management option for younger immunocompetent patients but the results were not promising in elderly population because of leukoencephalopathy and cognitive decline.⁷ Morris et al., also found combination therapy as a superior option, and used rituximab, methotrexate, procarbazine, vincristine for induction and then consolidation with reduced dose of XRT and cytarabine with high response rate, long term disease control and minimal neurotoxicity.⁸ Hirono et al., suggested that stereotactic radiosurgery followed by high dose methotrexate improves overall survival with the preservation of daily activities compared to WBRT in newly diagnosed PCNSL.⁹

The recently published trial assessed the tolerability and efficacy of adding rituximab with or without thiotepa to methotrexate-cytarabine combination therapy (the MATRix regimen), followed by a second randomization comparing consolidation with whole-brain radiotherapy or autologous stem cell transplantation in patients with

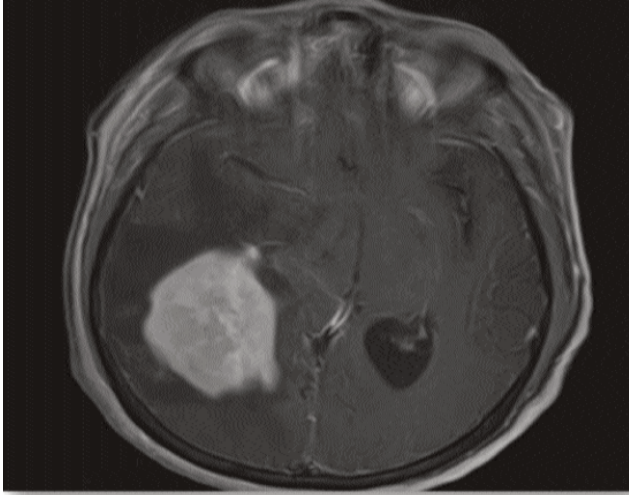


Figure: MRI brain T1WI with gadolinium enhancement showing large enhancing abnormal signal intensity lesion in the right occipital lobe involving part of splenium of corpus callosum and wrapping the right occipital horn. Later, neuronavigation guided stereotactic biopsy proved PCNSL.

primary CNS lymphoma. With the limitations of a randomized phase 2 study design, the IELSG32 trial provides a high level of evidence supporting the use of MATRix combination as the new standard chemotherapeutic for patients aged up to 70 years with newly diagnosed primary CNS lymphoma and as the control group for future randomized trials.¹⁰ In a prospective observational cohort study, Alvarez-Pinzon et al., compared high dose methotrexate alone with combination of high dose methotrexate and SRS. They concluded that combination therapy is useful in local control of the newly diagnosed or relapsed cases without significant neurotoxicity.¹¹

Conventionally, the role of surgery is limited to biopsy of the lesion for histopathological diagnosis. However, recently Sonabend et al., suggested surgical resection as an alternative treatment option in selected patients. In their series, even though the complication rates were comparable to other intracranial high-grade lesions, the authors were not able to prove the superiority of surgery to other therapeutic modalities in the treatment of PCNSL.¹²

Conclusion

There appear variations in the management of PCNSL and preferences dictate the use of methotrexate, other chemotherapeutics, and radiotherapy as management options. Most authors have advocated combination of

chemotherapy and radiotherapy more successful than any of these treatments alone. The role of stereotactic radiosurgery as co-adjuvant with methotrexate is also emerging as useful tool in disease control, better survival and lesser complications in recent studies. It is of significant value that better survival rates of PCNSL patients can be obtained by employing multidisciplinary treatment options.

References

- Hayabuchi N, Shibamoto Y, Onizuka Y. Primary central nervous system lymphoma in Japan: a nationwide survey. *Int J Radiat Oncol Biol Phys.* 1999; 44: 265-72.
- Ferreri AJ, Marturano E. Primary CNS lymphoma. *Best Pract Res Clin Haematol.* 2012; 25: 119-30.
- DeAngelis LM, Yahalom J, Heinemann MH, Cirrincione C, Thaler HT, Krol G. Primary CNS lymphoma: combined treatment with chemotherapy and radiotherapy. *Neurology.* 1990; 40: 80-6.
- Ferreri AJ, Dell'Oro S, Foppoli M, Bernardi M, Brandes AA, Tosoni A, et al. MATILDE regimen followed by radiotherapy is an active strategy against primary CNS lymphomas. *Neurology.* 2006; 66: 1435-8.
- Ferreri AJ, Ciceri F, Brandes AA, Montanari M, Balzarotti M, Spina M, et al. MATILDE chemotherapy regimen for primary CNS lymphoma: results at a median follow-up of 12 years. *Neurology.* 2014; 82: 1370-3.
- Sonoda Y, Matsumoto K, Kakuto Y, Nishino Y, Kumabe T, Tominaga T, et al. Primary CNS lymphoma treated with combined intra-arterial ACNU and radiotherapy. *Acta Neurochir (Wien).* 2007; 149: 1183-9.
- Ghesquieres H, Ferlay C, Sebban C, Perol D, Bosly A, Casasnovas O, et al. Long-term follow-up of an age-adapted C5R protocol followed by radiotherapy in 99 newly diagnosed primary CNS lymphomas: a prospective multicentric phase II study of the Groupe d'Etude des Lymphomes de l'Adulte (GELA). *Ann Oncol.* 2010; 21: 842-50.
- Morris PG, Correa DD, Yahalom J, Raizer JJ, Schiff D, Grant B, et al. Rituximab, methotrexate, procarbazine, and vincristine followed by consolidation reduced-dose whole-brain radiotherapy and cytarabine in newly diagnosed primary CNS lymphoma: final results and long-term outcome. *J Clin Oncol.* 2013; 31: 3971-9.
- Hirono S, Iwadate Y, Higuchi Y, Serizawa T, Nagano O, Matsutani T, et al. Stereotactic radiosurgery in combination with up-front high-dose methotrexate as a first-line treatment for newly diagnosed primary central nervous system lymphoma. *J Neurooncol.* 2015; 123: 237-44.
- Ferreri AJ, Cwynarski K, Pulczynski E, Ponzoni M, Deckert M, Politi LS, et al. Chemoimmunotherapy with methotrexate, cytarabine, thiotepa, and rituximab (MATRix regimen) in patients with primary CNS lymphoma: results of the first randomisation of the International Extranodal Lymphoma Study Group-32 (IELSG32) phase 2 trial. *The Lancet Haematology.* 2016; 3: e217-e27.
- Alvarez-Pinzon AM, Wolf AL, Swedberg H, Coy SR, Valerio JE. Primary Central Nervous System Lymphoma (PCNSL): Analysis of Treatment by Gamma Knife Radiosurgery and Chemotherapy in a Prospective, Observational Study. *Cureus.* 2016; 8: e697.
- Cloney MB, Sonabend AM, Yun J, Yang J, Iwamoto F, Singh S, et al. The safety of resection for primary central nervous system lymphoma: a single institution retrospective analysis. *J Neurooncol.* 2017; 132: 189-97.