



THE AGA KHAN UNIVERSITY

eCommons@AKU

Section of Pulmonary & Critical Care

Department of Medicine

October 2017

# Case of undiagnosed pneumocystis pneumonia (PCP)

Verda Arshad  
*Aga Khan University*

Nousheen Iqbal  
*Aga Khan University, nousheen.iqbal@aku.edu*

Haider Ali Saleem  
*Aga Khan University*

Muhammad Irfan  
*Aga Khan University, muhammad.irfan@aku.edu*

Follow this and additional works at: [https://ecommons.aku.edu/pakistan\\_fhs\\_mc\\_med\\_pulm\\_critcare](https://ecommons.aku.edu/pakistan_fhs_mc_med_pulm_critcare)

 Part of the [Critical Care Commons](#), and the [Pulmonology Commons](#)

## Recommended Citation

Arshad, V., Iqbal, N., Saleem, H. A., Irfan, M. (2017). Case of undiagnosed pneumocystis pneumonia (PCP). *BMJ case reports*.  
**Available at:** [https://ecommons.aku.edu/pakistan\\_fhs\\_mc\\_med\\_pulm\\_critcare/62](https://ecommons.aku.edu/pakistan_fhs_mc_med_pulm_critcare/62)

## CASE REPORT

## Case of undiagnosed pneumocystis pneumonia (PCP)

Verda Arshad,<sup>1</sup> Nousheen Iqbal,<sup>2</sup> Haider Ali Saleem,<sup>1</sup> Muhammad Irfan<sup>2</sup><sup>1</sup>Aga Khan Medical College, Aga Khan University, Karachi, Pakistan<sup>2</sup>Section of Pulmonology and Critical Care, Department of Medicine, Aga Khan University and Hospital, Karachi, Pakistan**Correspondence to**

Dr Nousheen Iqbal, naush\_gr8smcian@hotmail.com

Accepted 9 October 2017

**SUMMARY**

Pneumocystis pneumonia (PCP) is an opportunistic fungal infection that is usually seen in immunocompromised patients, especially those with HIV, malignancies, organ transplants and on drug therapies like chemotherapy and steroids. PCP has subacute presentation in patients with AIDS which if left untreated gets worse and is a significant cause of morbidity and mortality. Here we present a case of PCP went undiagnosed, partially due to the patient being unaware of his HIV positive status and partially because no organism could be found under the microscope.

**BACKGROUND**

Pneumocystis pneumonia (PCP) is caused by the fungus *Pneumocystis jirovecii*. Although the advent of highly active antiretroviral therapy for patients with HIV has led to a decrease in cases of PCP, it remains the most common opportunistic infection in patients with AIDS.<sup>1</sup> Clinically, PCP presents as a subacute process with symptoms being gradual in onset. Pneumocystis cannot be cultured; therefore, definitively diagnosing PCP depends on microscopic examination of tissues or fluids from the lungs.<sup>2</sup> Diagnosing PCP can be a hard task because in comparison with other pulmonary pathologies, PCP has no unique presentation that would allow a clinician to differentiate and diagnose it. Here we present a case of PCP in which all the specimens failed to show any form of the organism and later on lung biopsy diagnosed PCP, and the patient was then treated for it and got better and turned out HIV positive.

**CASE PRESENTATION**

A 50-year-old man presented to the pulmonology clinic with complaints of fever, weight loss and productive cough since the last 1 month. His fever was low grade and spiked in the evenings, reaching a maximum of 38°C. He had previously taken several antibiotics without any relief and most recently had finished a course of amoxicillin for 7 days. He had noticed a significant decrease in appetite in the immediate past and had lost approximately 8–10 kg. He had placement of permanent pacemaker 10 years ago due to sick sinus syndrome. With a history of carcinoma of the stomach, he had received chemotherapy and undergone partial gastrectomy 5 years ago. A few months ago, he had been hospitalised due to upper gastrointestinal bleeding secondary to gastric ulcers. Significantly, he had received multiple blood transfusions in the past. There was no known tuberculosis contact

history and no extramarital affairs. On examination, he was a thin, lean young male with no evident respiratory distress. His blood pressure was 103/68 mm Hg, his pulse was 90 beats/min, respiratory rate was 14 breaths/min and his weight was 43 kg. On auscultation, normal vesicular breathing was heard with no added sounds. His oxygen saturation was consistent at 99% on room air.

**INVESTIGATIONS**

His chest X-ray showed bilateral diffuse interstitial prominence with nodular infiltrates (figure 1). CT scan showed patchy area of ground glass with relative sparing of the apices and intralobular septal thickening with some nodular infiltrates in bilateral lung fields (figure 2). Complete blood count was unremarkable. He was unable to expectorate sputum, so bronchoscopy was advised but the patient refused for any intervention. Considering the high TB burden in Pakistan, he was started on empiric antituberculous therapy (ATT) but despite being on ATT for a month no improvement was noted. Patient returned to the clinic with worsening symptoms. Fever was persisting daily during the night. Chest X-ray was repeated and it showed alveolar infiltrates on bilateral perihilar and lower zones (figure 3).

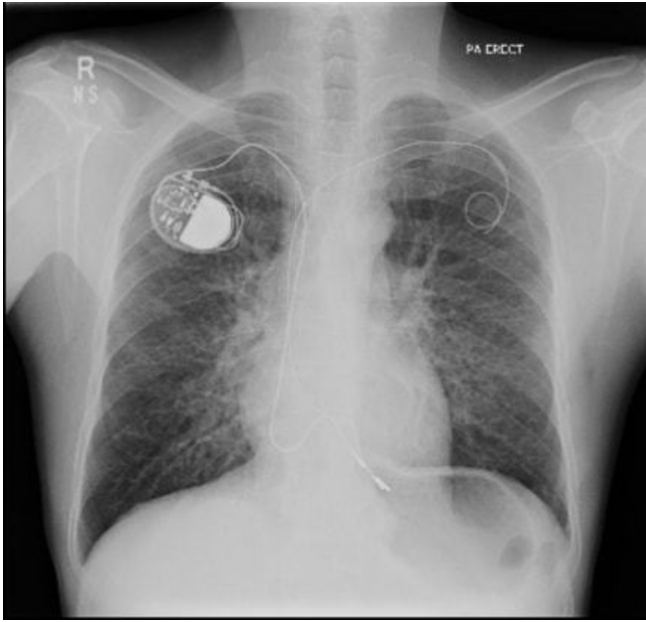
The patient eventually agreed for bronchoscopy. On bronchoscopy, there were normal airways with normal mucosa. Bronchial washings were taken from lower lobes bilaterally and specimens were sent for microbiology and cultures and cytology. His blood culture showed no growth of any organism. Acid fast bacilli smear and culture were both negative. *Nocardia*, fungus smear and culture were also negative. Gram stain showed only rare pus cells. PCP and GeneXpert/MTB-RIF were also negative. Cytology also ruled out malignancy.

Despite being on ATT for 2 months, no improvement was noted. The patient was then referred to the cardiothoracic surgeon for lung biopsy. Right open lung biopsy was taken from middle and lower lobes. Microscopy of the specimen with the silver stain, the periodic acid-Schiff-diastase stain and immunofluorescent staining did not reveal anything of significance; no evidence of granulomatous inflammation or malignancy was seen. However, within the alveolar spaces, pink frothy proteinaceous exudate was visualised (figure 4), and thus the query of PCP was raised by the histopathologist. Blood was tested for HIV the next day which came back reactive. Given the overall picture, a presumptive diagnosis of PCP was made and therapy was started.



CrossMark

**To cite:** Arshad V, Iqbal N, Saleem HA, et al. *BMJ Case Rep* Published Online First: [please include Day Month Year]. doi:10.1136/bcr-2017-221871



**Figure 1** Chest X-ray showing bilateral diffuse interstitial prominence with nodular infiltrates.

#### DIFFERENTIAL DIAGNOSIS

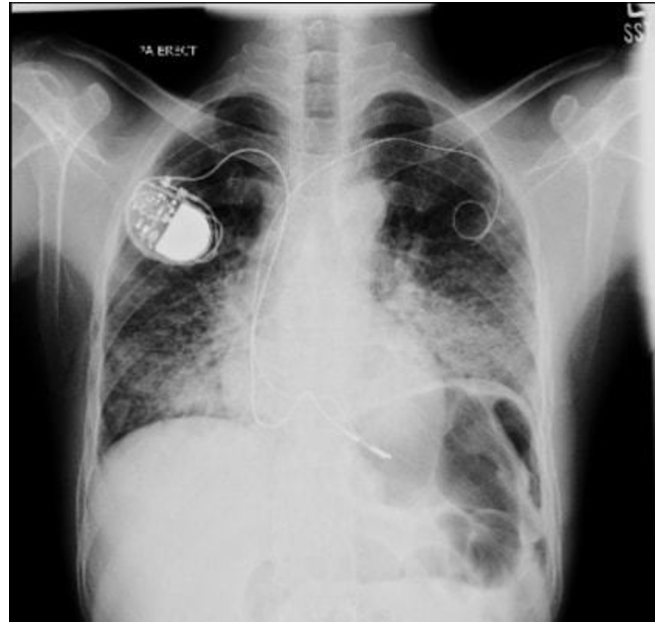
1. Tuberculosis.
2. Fungal infection.
3. Metastatic carcinoma with lymphangitis carcinomatosa.
4. *Nocardia*.
5. Sarcoidosis.

#### TREATMENT

Patient was started on Septran double strength. This contains sulfamethoxazole (800mg) and trimethoprim (160 mg). No allergic reactions were evident and the patient tolerated the therapy well for a total of 21 days.

#### OUTCOME AND FOLLOW-UP

After 1 week of treatment, the patient started getting better. The patient noted improvement in breathing and became

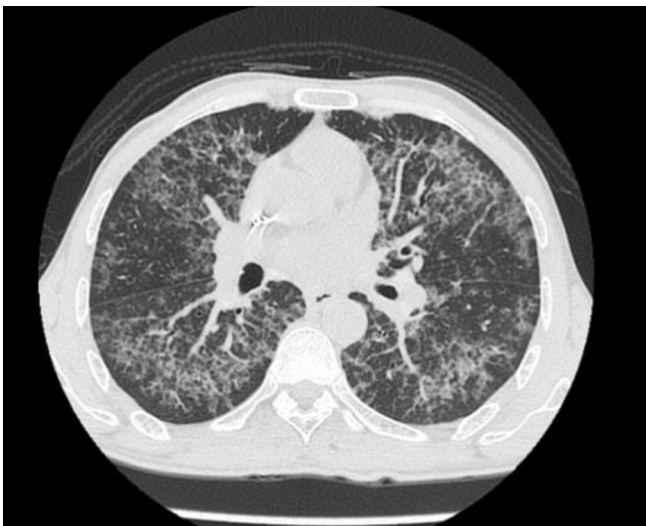

**Figure 3** Chest X-ray showing bilateral perihilar and lower zones alveolar infiltrates.

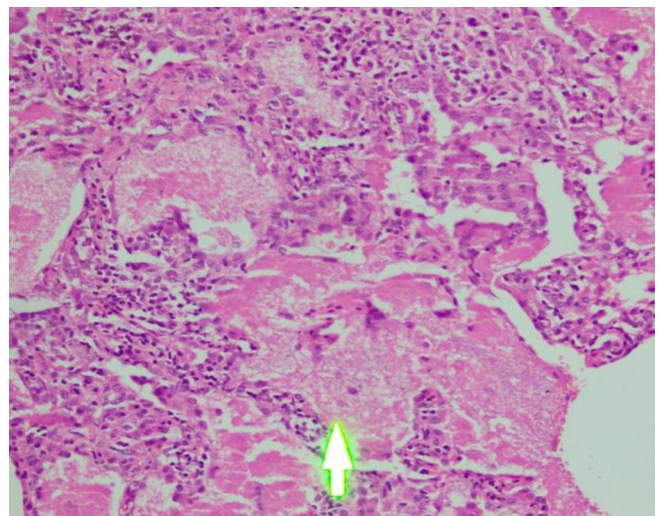
afebrile. Chest X-ray also showed signs of betterment and eventually he recovered. The patient has since been in good health and has been undergoing routine follow-ups for the last 2 years under infectious disease (for HIV) and gastroenterology.

#### DISCUSSION

Pneumocystis is currently classified as a fungus but does not respond to antifungal therapy and cannot be grown on culture in a laboratory. The common symptoms of PCP include low-grade fever (80%–100%), productive cough (95%), dyspnoea (95%) and shortness of breath.<sup>3 4</sup> Clinically diagnosing PCP is difficult even for experienced physicians because the manifestations are very non-specific.<sup>5</sup> Chest X-rays are normal in 25% of all initial cases of PCP and CT scans are inconclusive for the type of abnormality. The radiological findings can be atypical, although most commonly visualised are bilateral interstitial infiltrates.<sup>6</sup>



**Figure 2** CT scan showing septal thickening with nodular infiltrates in bilateral lung fields.



**Figure 4** Histopathology of lung tissue showing alveolar spaces filled with pink frothy proteinaceous exudate (H&E staining).

In diagnosing PCP microscopically, the samples obtained can be those of sputum obtained through expectorated induction (30%–90% specificity), from alveoli through bronchoalveolar lavage (90%–95% specificity) or most invasively from a lung biopsy (95%–100% specificity).<sup>7</sup> The stains most commonly used to view the pneumocystis are Gomori-methenamine silver (more commonly known as silver stain), the Gram-Weigert stain and the Wright-Giemsa stain. However, immunofluorescent staining using fluorescent-labelled monoclonal antibodies represent the gold standard for PCP diagnosis being more sensitive than the aforementioned general stains. Raised levels of lactate dehydrogenase are also seen in PCP but they are more indicative of lung tissue damage than PCP.<sup>8</sup> Serum 1,3-beta-d-glucan (BDG) levels have also been seen to increase in PCP infection.<sup>9</sup> Serum BDG showed excellent sensitivity and very good specificity in the diagnosis of PCP.<sup>10</sup> In order to establish an early diagnosis, BDG is helpful where patients are not able to produce sputum or refused to peruse for invasive testing like bronchoscopy as in our case but unfortunately this test was not available at the time of our patient presentation.

The diagnosis of PCP requires a high clinical suspicion from the consultant to order the relevant tests. In our case, not knowing the existence of HIV in the patient and not enquiring about it to avoid offending the patient's religious beliefs further complicated the scenario. Three months elapsed before our patient was diagnosed and his weight in the meantime fell to 37.5 kg. Fortunately, in our case, the patient survived. Our case shows the importance of an open mind from a clinician's point

of view and how it is always necessary to consider all possibilities regardless of how improbable they may seem. It also shows the normal process and time taken to diagnose an atypical disease. Upon enquiry later, it was discovered that a cousin of the patient was HIV positive and had donated blood to the patient in the past. If the patient had known to be HIV positive, he would have been on prophylactic treatment and could have avoided contracting PCP.

**Contributors** VA and HAS have equally contributed to the drafting of the manuscript and literature search. NI was responsible for drafting the manuscript and revising it critically for important intellectual content. MI critically analysed the case and was the primary physician.

**Competing interests** None declared.

**Patient consent** Obtained.

**Provenance and peer review** Not commissioned; externally peer reviewed.

© BMJ Publishing Group Ltd (unless otherwise stated in the text of the article) 2017. All rights reserved. No commercial use is permitted unless otherwise expressly granted.

## REFERENCES

- 1 Sepkowitz KA. Opportunistic infections in patients with and patients without acquired immunodeficiency syndrome. *Clin Infect Dis* 2002;34:1098–107.
- 2 Cushion MT, Beck JM. Summary of pneumocystis research presented at the 7th international workshop on opportunistic protists. *J Eukaryot Microbiol* 2001;Suppl:101s–5.
- 3 Engelberg LA, Lerner CW, Tapper ML. Clinical features of pneumocystis pneumonia in the acquired immune deficiency syndrome. *Am Rev Respir Dis* 1984;130:689–94.
- 4 Kales CP, Murren JR, Torres RA, *et al*. Early predictors of in-hospital mortality for pneumocystis carinii pneumonia in the acquired immunodeficiency syndrome. *Arch Intern Med* 1987;147:1413–7.
- 5 Thomas CF, Limper AH. Pneumocystis pneumonia. *N Engl J Med* 2004;350:2487–98.
- 6 DeLorenzo LJ, Huang CT, Maguire GP, *et al*. Roentgenographic patterns of pneumocystis carinii pneumonia in 104 patients with AIDS. *Chest* 1987;91:323–7.
- 7 Crowe S, Hoy J, Mills J. Management of the HIV-infected patient. *Nurse Pract* 1996;21:142.
- 8 Zaman MK, White DA. Serum lactate dehydrogenase levels and pneumocystis carinii pneumonia. Diagnostic and prognostic significance. *Am Rev Respir Dis* 1988;137:796–800.
- 9 Sax PE, Komarow L, Finkelman MA, *et al*. Blood (1->3)-beta-D-glucan as a diagnostic test for HIV-related pneumocystis jirovecii pneumonia. *Clin Infect Dis* 2011;53:197–202.
- 10 Karageorgopoulos DE, Qu JM, Korbila IP, *et al*. Accuracy of  $\beta$ -D-glucan for the diagnosis of pneumocystis jirovecii pneumonia: a meta-analysis. *Clin Microbiol Infect* 2013;19:39–49.

## Learning points

- ▶ Atypical pneumonia should be considered when no improvement is seen with normal antibiotics.
- ▶ Immunofluorescent staining should be used in addition to regular stains when pneumocystis is suspected.
- ▶ Definitive signs may not always be present; a clinician has to work up a holistic picture of a disease process.
- ▶ Beta-d-glucan can be helpful in such case scenarios where patient refuses for invasive testing like bronchoscopy.

Copyright 2017 BMJ Publishing Group. All rights reserved. For permission to reuse any of this content visit <http://group.bmj.com/group/rights-licensing/permissions>.  
BMJ Case Report Fellows may re-use this article for personal use and teaching without any further permission.

Become a Fellow of BMJ Case Reports today and you can:

- ▶ Submit as many cases as you like
- ▶ Enjoy fast sympathetic peer review and rapid publication of accepted articles
- ▶ Access all the published articles
- ▶ Re-use any of the published material for personal use and teaching without further permission

For information on Institutional Fellowships contact [consortiasales@bmjgroup.com](mailto:consortiasales@bmjgroup.com)

Visit [casereports.bmj.com](http://casereports.bmj.com) for more articles like this and to become a Fellow