



3-2018

Biopsy proven case of Creutzfeldt- Jacob disease from Pakistan

Rizwana Shahid

King Fahd University Hospital, Alkhobar

Saad Shafqat

Aga Khan University Hospital, Karachi

Follow this and additional works at: <https://ecommons.aku.edu/pjns>

 Part of the [Neurology Commons](#)

Recommended Citation

Shahid, Rizwana and Shafqat, Saad (2018) "Biopsy proven case of Creutzfeldt- Jacob disease from Pakistan," *Pakistan Journal of Neurological Sciences (PJNS)*: Vol. 13 : Iss. 1 , Article 9.

Available at: <https://ecommons.aku.edu/pjns/vol13/iss1/9>

Biopsy Proven Case Of Creutzfeldt- Jacob Disease From Pakistan

¹Rizwana Shahid, ²Saad Shafqat

¹King Fahd University Hospital, Alkhobar

²Aga Khan University Hospital, Karachi

Corresponding to: Rizwana Shahid, Alkhobar, KSA Email:rshahid@iau.edu.sa

Date of submission: October 11, 2017 Date of revision: November 22, 2017 Date of acceptance: December 28, 2017

ABSTRACT:

Creutzfeldt-Jakob disease (CJD) is a rare type of prion disease leading to a rapidly progressive dementia (RPD) and other associated neurological features specially startle myoclonus. The annual incidence of CJD has been reported to be 1 per million or 271 people in USA², but from Asia especially from Pakistan, only few case reports have been published.

The probable cause behind the rarity of this disease in our society is still unclear. The diagnosis of CJD requires a high level of suspicion and lack of the availability of specific markers like CSF 14-3-3 in our setup makes it more difficult. Similarly brain biopsy is not an acceptable option for families of the sufferers because of the unavailability of the specific treatment.

To our knowledge this is the first biopsy proven case of Crutzfeld Jacob disease (CJD) from Pakistan.

INTRODUCTION:

The prion diseases are defined as a large group of related neurodegenerative conditions that affect both animals and humans^[1] Prion disease is a rare disease that has a prevalence of 1 in 1 million cases.^[2] It has been reported infrequently from Asian countries. According to the recent case series from Aga Khan university Hospital by Shazma Khan et al. there were only 4 cases labeled as CJD from Pakistan till 2014 and through retrospective record of AKUH from 1997 till 2015, 12 cases were found to be labeled as CJD and only one was biopsy proven case.^[3] We are reporting the case that has been confirmed by brain biopsy to be definite CJD.

CASE HISTORY:

Our patient was a 69 years old female, who was not known to have any medical comorbid prior to her symptoms. She presented to Aga Khan University Hospital, Karachi with five months history of becoming progressively withdrawn and apathetic. There was two months history of gait unsteadiness and falls. She started to have myoclonic jerks (especially of left upper limb), two weeks prior to presentation, that were followed by progressive unresponsiveness and finally she became bed bound.

Her general physical exam was significant for mild pallor, she was febrile. Neurologically, there was spontaneous eye opening, no eye contact with examiner or surroundings and no verbal output, neither she was able to follow commands, however brainstem responses (pupils, eye movements,

spontaneous respiration) were preserved and she was able to localize deep pain from left hand, in other three limbs, there was flexion withdrawal to deep pain.

Intermittent jerky movements were seen in left upper limb, aggravated by trivial stimuli. Deep tendon reflexes were +1, symmetrical with bilateral flexor planters.

On blood testing, only positive finding was peripheral neutrophil leukocytosis with normal ECG although Chest X-ray was suggestive of aspiration pneumonia. Non contrast brain CT scan revealed generalized cerebral atrophy, which was confirmed on MRI scan. C.S.F biochemistry was normal. EEG revealed periodic sharp complexes at approximately 1.5Hz. Brain biopsy was done from nondominant frontal pole that revealed spongiform changes. Immuno-staining of biopsy sample with 3F4 monoclonal antibody revealed granular deposits (specific for prion disease).

DISCUSSION:

Prion diseases are the neurodegenerative diseases that usually have long incubation periods. Once the patient's clinical symptoms start, usually it progresses indefinitely. Among the five different human prion diseases recognized, CJD accounts for more than 90 percent of sporadic prion disease^[4].

The most of CJD cases are sporadic (85 to 95 percent), while 5 to 15 percent are due to familial CJD; iatrogenic CJD generally accounts for less than 1 percent^[5,6]

Classical sporadic CJD presents as rapidly progressive dementia usually associated with myoclonus.

Additional neurological features might include

pyramidal and extrapyramidal signs, cerebellar ataxia, and cortical blindness. The onset is usually in the 45–75 years age group with median age at death of 68 years^[7]. The clinical progression is typically over weeks that can progress to akinetic mutism with a median disease duration of 5 months.

The diagnosis of CJD is suspected when a patient presents with typical clinical symptoms and signs of rapidly progressing dementia with myoclonus^[8]; further investigations to support the diagnosis include EEG showing characteristic generalized periodic sharp wave pattern and CSF analysis for 14-3-3 protein. However, the definitive diagnosis for prion disease is only by the biopsy of brain tissue. A negative biopsy does not necessarily rule out CJD, as it may predominate in a specific part of the brain.^[9]

CONCLUSION

This report confirms the presence in our population of Creutzfeldt - Jakob disease, an uncommon but important cause of dementia.

While clinical and EEG features suggest the diagnosis, confirmation requires biopsy or autopsy.

A high index of suspicion and low threshold for biopsy examination are needed to define the burden of CJD in Pakistan.

DISCLAIMER:

N.B: The subject of this case report gave his informed consent for the publication of this article.

Conflict of interest:

The authors declare that they have no conflicts of interest.

REFERENCES:

1. Sadowski M, Verma A, Wisniewski T. Prion Diseases. Bradley WG, Daroff RB, Fenichel GM, Jankovic J, eds. Neurology in Clinical Practice.

Philadelphia: Elsevier Inc.; 2004. 1613-1630.

2. Tyler KL. Creutzfeldt-Jakob disease. *N Engl J Med* 2003; 348: 681-2.
3. Khan S, Sajjad A, Khan S. Sporadic Creutzfeldt-Jakob disease: A case series from Aga Khan University Hospital. 3rd Euro-Global Experts Meeting on Medical Case Reports June 30-July 02, 2016 Valencia, Spain.
4. Puoti G, Bizzi A, Forloni G, et al. Sporadic human prion diseases: molecular insights and diagnosis. *Lancet Neurol* 2012; 11:618.
5. Masters CL, Harris JO, Gajdusek DC, et al. Creutzfeldt-Jakob disease: patterns of worldwide occurrence and the significance of familial and sporadic clustering. *Ann Neurol* 1979; 5:177.
6. Ladogana A, Puopolo M, Croes EA, et al. Mortality from Creutzfeldt-Jakob disease and related disorders in Europe, Australia, and Canada. *Neurology* 2005; 64:1586.
7. Wadsworth JD, Collinge J. Update on human prion disease. *Biochim Biophys Acta*. 2007; 1772:598–609.
8. Sattar, Hussain A. Fundamentals of Pathology. Chicago: Pathoma LLC. p. 187
9. Sternberg's Diagnostic Surgical Pathology, 5th edition.

Figure 1:
MRI Brain showing generalized brain atrophy.

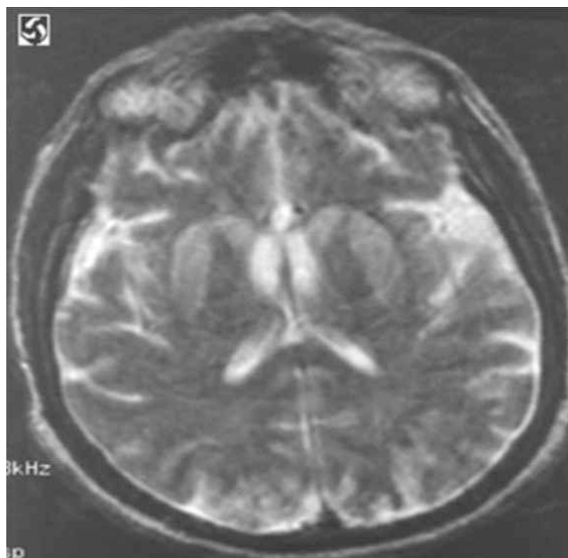
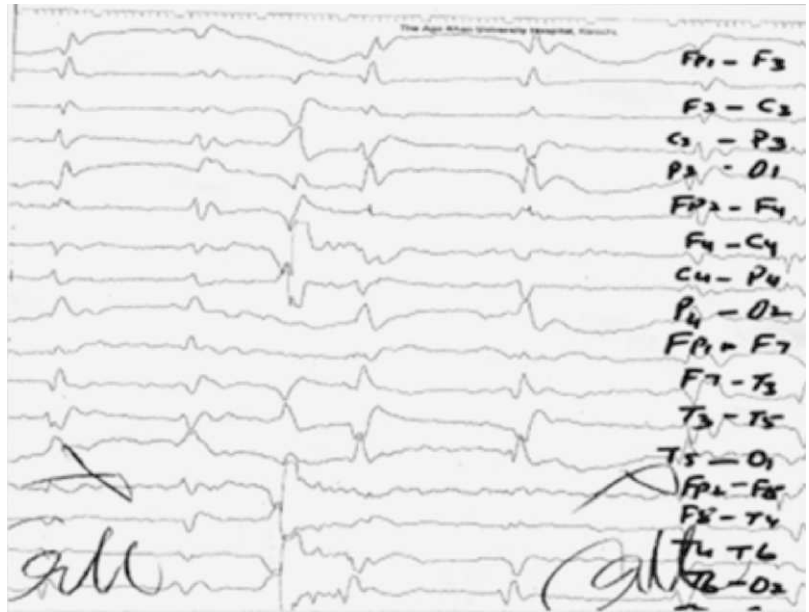
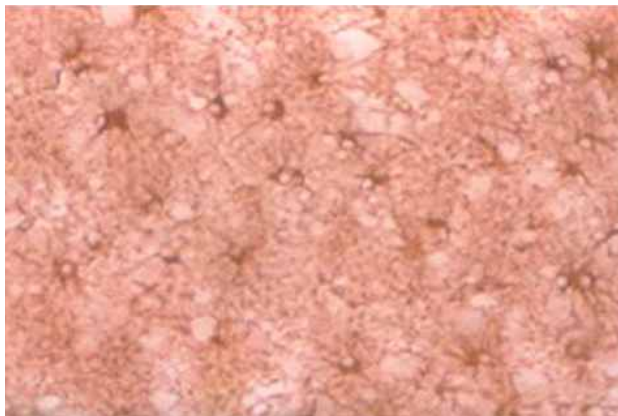


Figure 2:
EEG showing period sharp
complexes at approximately 1.5 Hz



Brain biopsy (GFAP) 20X



Brain biopsy (H&E) 40X

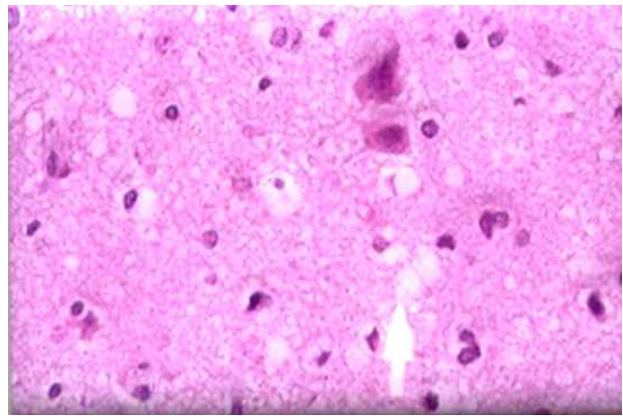


Figure 3: Brain biopsy
Showing spongiform changes and 3F4 monoclonal antibody revealed granular deposits

Conflict of interest: Author declares no conflict of interest.
Funding disclosure: Nil

Author's contribution:

Rizwana Shahid; concept, data collection, data analysis, manuscript writing, manuscript review
Saad Shafqat; concept, data collection, data analysis, manuscript writing, manuscript review