



THE AGA KHAN UNIVERSITY

eCommons@AKU

Section of Orthopaedic Surgery

Department of Surgery

2018

Primary total hip arthroplasty: Staying out of trouble intraoperatively

Shahryar Noordin

Aga Khan University, shahryar.noordin@aku.edu

Riaz Hussain Lakdawala

Aga Khan University, riaz.lakdawala@aku.edu

Bassam A. Masri

University of British Columbia, Canada

Follow this and additional works at: https://ecommons.aku.edu/pakistan_fhs_mc_surg_orthop




Part of the [Orthopedics Commons](#), and the [Surgery Commons](#)

Recommended Citation

Noordin, S., Lakdawala, R. H., Masri, B. A. (2018). Primary total hip arthroplasty: Staying out of trouble intraoperatively. *Annals of Medicine and Surgery*, 29, 30-33.

Available at: https://ecommons.aku.edu/pakistan_fhs_mc_surg_orthop/44



Review

Primary total hip arthroplasty: Staying out of trouble intraoperatively

Shahryar Noordin^{a,*}, Riaz Lakdawala^a, Bassam A. Masri^b^a Associate Professor, Orthopaedic Surgery, Aga Khan University, Karachi, Pakistan^b Professor and Head, Department of Orthopaedics, University of British Columbia, Vancouver, Canada

ARTICLE INFO

Keywords:

Total hip arthroplasty
Surgical technique

ABSTRACT

Total hip Arthroplasty is one of the most successful and commonly performed procedures in Orthopaedic Surgery. Meticulous preoperative planning allows to surgeon anticipate potential problems to reduce post-operative complications and optimize patient outcomes. Currently, the posterior approach is the most common approach utilized in the United States. In order to prevent errors in stem version, especially with cementless fixation, the entry point should be posterior, and the initial entry point should be aligned in the correct anteversion as this will determine the ultimate version of the stem. Preoperative evaluation should asses for true and apparent lengths. For successful osseointegration of cementless components, bone ingrowth occurs when there is less than 40 μ m of motion between the implant and bone. Certain socket conformations such as elliptical versus hemispherical are more prone to generate fractures at the time of impaction.

Total hip Arthroplasty is one of the most successful and commonly performed procedures in Orthopaedic Surgery. It provides a cost-effective option to relieve pain, restore physical function, mobility and improve the quality of life for patients with end stage hip arthritis. With aging of the population, the demand for total hip arthroplasty is anticipated to grow exponentially in the next two decades. Kurtz et al. reported a 50% increase in the prevalence of THA from 1990 to 2002 [1] and projected a 174% increase in THA from 208,600 in 2005 to 572,000 in 2030 [2], in the United States. In this paper we review the potential problems one can run into while performing a primary hip replacement during the surgery and the potential strategies to stay out of harm's way while ensuring an excellent outcome for the patient. It is important to note however that besides intraoperative measures in order to ensure an optimum outcome, preoperative assessment including indications for surgery, clinical judgment regarding the implants and type of fixation, as well as counselling the patient about expectations, potential complications, preoperative teaching, post-operative rehabilitation regimens and long term care also need to be adequately addressed.

1. Approach

The hip can be accessed through several approaches. Currently, the posterior approach is the most common approach utilized in the United States [3]. For this approach the patient is placed in the lateral decubitus position. Incision is centered over the posterior aspect of the greater trochanter running distally towards the vastus lateralis ridge

and curved proximally and posteriorly towards the posterior superior iliac spine. A longer incision is required if the patient is obese or muscular. After splitting the gluteus maximus fascia, the muscle fibers are split in the line with the incision taking care of any vessels. The short external rotators should be visible under the bursa and fat. A curved Hohmann retractor can be placed in a posterior-to-anterior direction above the piriformis, deep to the gluteus minimus and medius, thus elevating the gluteii to better expose the short external rotators. The hip is placed in extension, adduction and internal rotation, with the foot being supported by an assistant or on a padded Mayo stand to stretch the short external rotators. The piriformis and conjoined tendon are released along with the capsule in one layer close to their femoral insertions by a bent cautery tip aiming anteriorly ensuring that tendons are resected as close to the bone as possible (Fig. 1). If the tendons and capsule are cut short then the posterior soft tissue repair might not reach back to the femur, compromising the hip stability. With the gluteus minimus and medius elevated by the Hohmann retractor, the capsulotomy is completed as a U-shaped flap with a proximal limb anteriorly and a distal limb posteriorly, taking care to protect the sciatic nerve (Fig. 2). If the capsule remains tight, a longitudinal cut from proximal to distal is made in the inferior capsule, distal to the U-shaped flap, but deep to the quadratus femoris muscle is made. Once the palpating finger can be easily inserted distal to the femoral neck into the hip joint, the hip can be safely dislocated with flexion, adduction and internal rotation. Once the hip is dislocated, the hip is extended, and the quadratus femoris muscle is carefully released taking care to coagulate branches of the medial femoral circumflex artery to prevent

* Corresponding author.

E-mail address: Shahryar.noordin@aku.edu (S. Noordin).

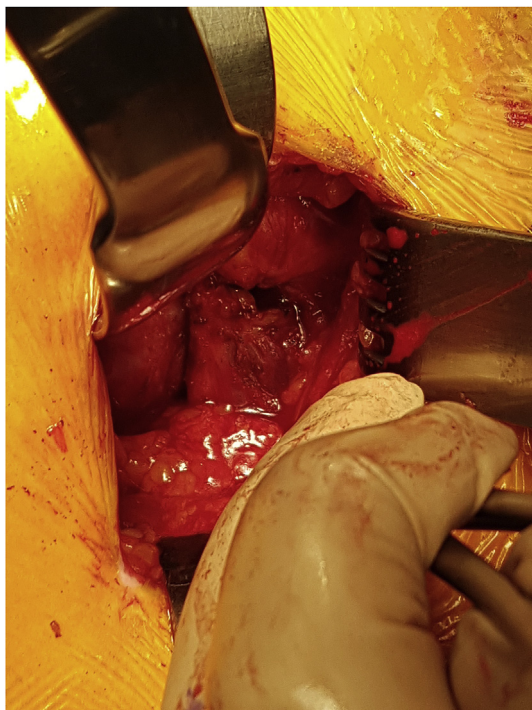


Fig. 1. Posterior capsule U shaped flap.

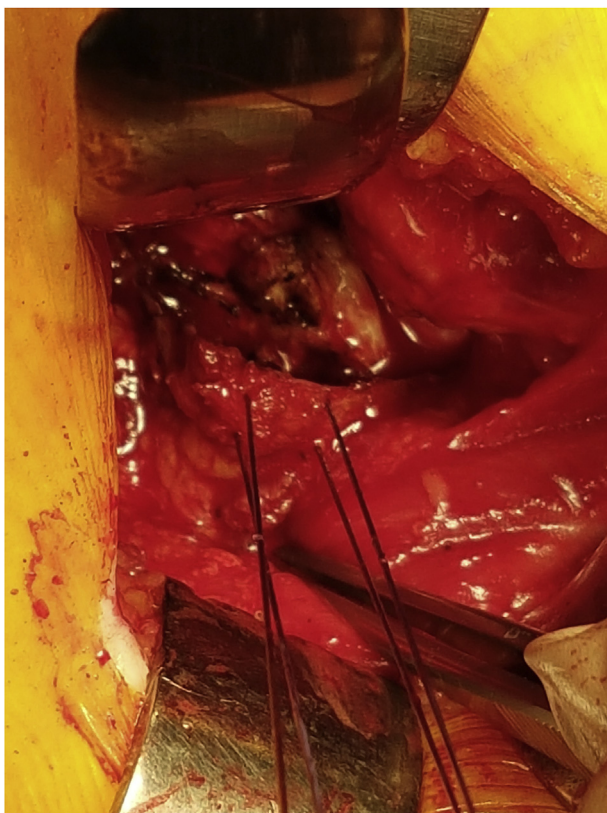


Fig. 2. The U shaped flap tagged with sutures.

excessive bleeding. The lesser trochanter is exposed to allow referencing for the neck cut, as per preoperative planning. The distance between the top of the lesser trochanter and the medial aspect of the neck cut is measured on the radiographs preoperatively, and a measured and cut Q-tip of the same templated length is used to mark the neck cut,

which is then completed with a reciprocating saw.

2. Acetabular exposure

Two retractors are placed to optimize acetabular exposure. The femur is retracted anteriorly by placing one curved Hohmann retractor (also known as a Cobra retractor) anterior to the socket. The second retractor is posteriorly along the posterior column. This is an angled Hohmann retractor that can be attached to a modular Charnley retractor. The transverse acetabular ligament (TAL) is exposed and marked for easy reference so that the position of the acetabular component, in most cases, is determined by the transverse acetabular ligament. A line parallel to the TAL may be drawn proximal to the incision, and the acetabular inserter is then referenced perpendicular to that line. Alternatively, as long as the lower extremity is held in a static position, a line perpendicular to the TAL is drawn distal to the incision, and the acetabular inserter is placed parallel to that line.

3. Femoral exposure

One of the advantages of the posterior approach is its superior femoral exposure. The caveat is that adequate retractor placement must be accomplished. A narrow and long femoral elevator with attached weights is placed anterior to the femur to bring it up into the wound. It is placed at about 45° angle to the femur along the medial aspect of the cut calcar. A Cobra retractor is placed medially between the lesser trochanter and the cut calcar to allow excellent visualization of the calcar so that any fractures may be detected and treated immediately. In order to avoid placing the stem in varus, the entry point should be well lateral, and a lateralizer should be used. In order to prevent errors in stem version, especially with cementless fixation, the entry point should be posterior, and the initial entry point with the so-called cookie-cutter should be aligned in the correct anteversion as this will determine the ultimate version of the stem.

4. Socket and stem anteversion

Lewinnek et al., in 1978 based on a series of 300 total hip arthroplasties described “safe zones” for cup placement with an anteversion angle of 5° – 25° and an inclination (abduction) angle of 30° – 50°. Using these parameters, the dislocation rate was 1.5% as compared to 6.1% when sockets were placed outside these zones [4]. Several methods have been described to help the surgeon intraoperatively with optimal cup positioning, including mechanical alignment guides [5] but only moderate accuracy has been achieved with these methods. Errors with conventional socket placement techniques may be because of several factors such as surgeon estimation error, variation in patient anatomy, and intraoperative change in pelvic orientation [6]. Positioning on the operating table, dislocation of the native hip, and the use of retractors can all cause intraoperative pelvic movement, which changes pelvic orientation [6]. [7] Computer-assisted navigation (CAN) systems have been reported to increase the accuracy of socket placement [6]. However these systems are expensive, cumbersome to set up and not universally available. Intraoperative landmarks are patient-specific, reproducible, independent of patient position and have been reported for use as intraoperative orientation guides [6]. In this respect, the transverse acetabular ligament (TAL) has been shown to be one of the potential landmarks that has been used by several investigators [7–13]. Hiddema WB et al. [6] have shown that when the acetabulum's inferior rim is aligned flush with the TAL, the socket inclination will be ideally located within the accepted safe zone of Lewinnek. They recommended that when the inferior rim of the socket is parallel to the TAL, anteversion should also be in the safe zone. Elkins et al. [14] from Iowa introduced the concept of “landing zone” as it provides socket positions that are best for maximizing construct stability and minimizing wear in relation to the femoral head diameter and femoral stem

anteversion. They showed that the “landing zone” was substantially smaller than historical guidelines [14] and specifically did not increase with increased femoral head size contrary to traditional notion that larger heads are more forgiving. They showed that for a 36 mm cup with a 20° anteverted stem, the ideal cup orientation was $46^{\circ} \pm 12^{\circ}$ inclination and $15^{\circ} \pm 4^{\circ}$ anteversion. In their study [14] the optimal landing zone for both stability and wear was more sensitive to anteversion than inclination, emphasizing the importance of combined anteversion. Excessive anteversion of the socket predisposes to anterior dislocation whereas decreased anteversion or retroversion increases the risk for posterior dislocation as well as iliopsoas impingement. Abnormal anteversion of the hip should be anticipated preoperatively in patients with hip dysplasia, Perthes disease, or previous malunited hip fractures. Similarly one should be wary of retroversion in patients with femoral acetabular impingement, slipped capital femoral epiphysis and malunited fractures.

The range for the combined anteversion of the femoral stem and cup has been defined as 25°-45° [15,16]. Femoral component version is limited by the patient’s anatomy and therefore Dorr and colleagues recommend placing the femoral component first. One can then factor in more anteversion in the socket if required. Cemented femoral components offer the potential of more anteversion. However, in the vast majority of hip replacement, 10–15° of femoral anteversion are easily accomplished, a therefore, aiming for 20–25° of acetabular anteversion will usually suffice. In dysplastic cases, where there is excessive native femoral anteversion, this can be recognized preoperatively, and a different stem design such a tapered fluted stem or a modular stem may be used to ensure adequate femoral implant anteversion. For this reason, the authors do not recommend altering the socket position based on femoral anteversion as correct femoral anteversion should be achievable in all cases, either by inserting the stem in the correct version or if not possible, by selecting a stem that is not affected by the native femoral version. On the acetabular side, the TAL remains the best guide for acetabular anteversion. If it is not readily visible, it may need to be carefully exposed by removing inferior osteophytes. We prefer to use a small acetabular reamer to gently ream through the osteophyte so that the embedded ligament can be found.

5. Joint stability and limb lengths

Preoperative evaluation should assess for true and apparent lengths. Apparent leg length discrepancy may be due to fixed pelvic obliquity, lumbar spondylosis, scoliosis with pelvic tilt, contractures of the hip capsule, rectus femoris or iliotibial band. Appropriate xrays including those of the lumbar spine may be required for the initial assessment. Preoperative roentgenographic templating is extremely important to ensure appropriate leg lengths postoperatively. At the time of surgery, prior to implanting the definitive components one should assess for stability and impingement using the trial implants and putting the hip through a range of motion. In case of instability one should assess for bony or soft tissue impingement, offset and leg lengths. In our experience, any intraoperative instability is related to component malposition, and this needs to be corrected prior to the end of the procedure. Several techniques have been described to measure leg lengths intraoperatively. A practical method for measuring leg lengths during arthroplasty requires use of a stable pelvic reference with another marker on a predetermined point on the femur, combined with a method for accurately positioning the leg during measurements. This measurement prior to hip dislocation and then with the trial components in place, provides some feedback to the surgeon. Another eyeball measurement is to palpate both knees and malleoli with the index and nonoperated limbs in the same position, but this technique requires some experience and is somewhat subjective. To correct errors in socket anteversion, lipped or face-changing liners can be used for added stability, but the senior author recommends repositioning the acetabular component and using a neutral liner, as this leads to the lowest possible

dislocation rate. Using large femoral heads further improves stability at the cost of a thinner liner, but this is not an issue for highly cross-linked polyethylene. One has to keep in mind the risk of mechanically-assisted fretting corrosion with larger cobalt-chrome femoral heads. Great care to clean the trunnion and to impact the femoral head well has to be taken to minimize that risk. The senior author has resorted to ceramic heads to reduce that risk. One has to avoid the use of high offset femoral components unless this is needed to restore the hip biomechanics based on preoperative planning. One should not use a high offset femoral stem to attempt to address instability caused by malpositioned components. Also, one should not excessively lengthen the hip to address instability that should be addressed by re-positioning the components.

6. Soft tissue balancing

Based on the preoperative radiographic templating, one can decide about the femoral neck osteotomy site in relation to its distance from the lesser trochanter. Templating also advises one of the acetabular component size and position as well as the femoral component offset and neck lengths. In the event of a varus hip, the femoral osteotomy would be closer to the lesser trochanter, and an extended offset component may be required. On the other hand, for a valgus hip, the femoral osteotomy site would be farther away from the lesser trochanter, with a standard offset femoral component. At the time of component reduction, the shuck test helps in gauging the tightness of the reduction which may also be influenced by the type of anesthesia. If the leg has been lengthened then it may be difficult to reduce the femoral head. Also, if the hip is too long, it may not be possible to fully extend the hip and flex the knee. Once the hip is fully extended and if the ipsilateral knee goes into flexion, it would indicate that the hip is lengthened with a tight rectus femoris limiting full knee flexion. In such situations, the femoral neck length can be decreased. With a preoperative hip fixed flexion contracture, one could consider an anterior hip capsule release. Another possibility is that the socket has been placed lower down or has been lateralized, which would need to be repositioned.

If the hip feels short after reduction, with significant diastasis in the shuck test, then the socket could have been placed higher with an elevated center of rotation or the femoral neck cut could have been shorter than planned. For this one could increase the neck length at the expense of increased offset. However one must be careful that the skirted femoral neck does not impinge. Another option to address this short hip is to use the next upper size of the femoral component leaving it somewhat proud. This should be done carefully as increasing the size of the femoral component could create a proximal femur fracture.

7. Intraoperative fractures

For successful osseointegration of cementless components, bone ingrowth occurs when there is less than 40 μm of motion between the implant and bone [17,18]. In the situation where gaps exist between implant and bone, fibrous healing occurs setting the stage for groin or thigh pain, depending on the area of fibrous healing. Therefore one has to aim for a large area of implant bone contact to prevent fibrous union. By oversizing the socket and obtaining stability at the rim, one risks poor contact at the dome. On the other hand, an undersized cup would tend to have good bone contact at the dome but would tend to lack primary stability. Generally underreaming the socket by 1 mm, provides the best balance between stability and bone contact for cementless cups but one should be wary of the instrumentation and system recommendations. In the situation of line-to-line reaming, the use of two or more screws provides optimal primary stability. One has to be cognizant of the position of the screws to avoid any catastrophes. The postero-superior quadrant of the acetabulum provides a safe zone for screw fixation. Placing a screw in the antero-superior quadrant and the postero-inferior quadrant risk damage to the external iliac vessels and the superior gluteal nerve and vessels respectively. Placing screws in

the antero-inferior quadrant risks damage to the obturator nerve and vessels.

When faced with a poor press-fit with the socket, one has to address potential inadequate exposure, soft tissue interposition, and lack of proper bone contact with the implant due inadequate medialization. Soft tissue interposition can be checked by ensuring that the entire rim is clear of soft tissues, especially posteriorly where visualization is worst. For adequate bone implant contact, one has to perform additional reaming. In dysplastic hips, medializing the socket improves bone contact and stability.

Certain socket conformations such as elliptical versus hemispherical are more prone to generate fractures at the time of impaction. At the time of implantation of the definitive component, if one notices it to be more medial than the corresponding trial implant, then one must actively look for a posterior column fracture. One should palpate the sciatic notch and if there is an undisplaced fracture, then one can use a cluster hole socket and place screws on each side of the fracture, carefully attempting to catch the far cortex. If the fracture is displaced, then one should plate the posterior column. (x-rays required).

Patients at risk for femoral fractures include those with osteopenia, femoral stenosis, previous femoral surgery and those with femoral deformity in the coronal or sagittal plane [17]. Preoperative templating allows one to anticipate these potential intraoperative issues. Previous operations like core decompression, DHS or intramedullary nail placement can cause stress risers. In patients with protusio derformity, making the femoral neck osteotomy in situ prior to dislocating the hip prevents a potential spiral fracture. The status of the calcar should be noted prior to and after the insertion of the femoral implant to identify any potential fractures. If the definitive implant seats deeper than the last broach, one should look for a fracture visually and by x-ray if necessary. In the event that a fracture occurs, one should expose the entire fracture line to plan appropriate secure fixation. Undisplaced calcar fractures can be managed with a cerclage wire or cable usually just above the lesser trochanter, and full weight-bearing may be allowed. If the fracture is displaced, one can wire, plate or use a long stem implant that bypasses the fracture. Undisplaced trochanteric fractures can be treated with cerclage. Displaced trochanteric fractures on the other hand require reduction followed by tension band wiring or claw fixation.

8. Summary

Intraoperative complications during THR can potentially lead to poor outcomes, patient dissatisfaction, and litigation. Meticulous preoperative planning, patient counselling in addition to excellent surgical technique, preoperative and postoperative rehabilitation are all imperative reduce postoperative complications and enhance patient outcomes.

Ethical approval

This is a review manuscript.

Sources of funding

No funding was obtained for this research.

Author contribution

Shahryar Noordin – study design, data collection, data analysis,

writing.

Riaz Lakdawala – data analysis, writing.

Bassam Masri – data analysis, writing.

Conflicts of interest

None.

Research registration number

Not applicable.

Guarantor

Shahryar Noordin.

Riaz Lakdawala.

Bassam Masri.

References

- [1] S. Kurtz, F. Mowat, K. Ong, N. Chan, E. Lau, M. Halpern, Prevalence of primary and revision total hip and knee arthroplasty in the United States from 1990 through 2002, *J Bone Joint Surg Am.* 87 (7) (2005) 1487–1497.
- [2] S. Kurtz, K. Ong, E. Lau, F. Mowat, M. Halpern, Projections of primary and revision hip and knee arthroplasty in the United States from 2005 to 2030, *J Bone Joint Surg Am.* 89 (4) (2007) 780–785.
- [3] J. Waddell, K. Johnson, W. Hein, J. Raabe, G. FitzGerald, F. Turibio, Orthopaedic practice in total hip arthroplasty and total knee arthroplasty: results from the Global Orthopaedic Registry (GLORY), *Am. J. Orthoped.* 39 (9 Suppl) (2010) 5–13.
- [4] G.E. Lewinnek, J. Lewis, R. Tarr, C. Compere, J. Zimmerman, Dislocations after total hip-replacement arthroplasties, *J Bone Joint Surg Am.* 60 (2) (1978) 217–220.
- [5] E. Xue, Z. Su, C. Chen, P.K.C. Wong, H. Wen, Y. Zhang, An intraoperative device to restore femoral offset in total hip arthroplasty, *J. Orthop. Surg. Res.* 9 (1) (2014) 1.
- [6] W.B. Hiddema, J.F. van der Merwe, W. van der Merwe, The transverse acetabular ligament as an intraoperative guide to cup abduction, *J. Arthroplasty* 31 (7) (2016) 1609–1613.
- [7] A. Viste, J. Chouteau, R. Testa, L. Cheze, M.-H. Fessy, B. Moyen, Is transverse acetabular ligament an anatomical landmark to reliably orient the cup in primary total hip arthroplasty? *J. Orthop. Traumatol.: Surgery & Research* 97 (3) (2011) 241–245.
- [8] D. Beverland, The transverse acetabular ligament: optimizing version, *Orthopedics* (9) (2010) 33.
- [9] H. Abe, T. Sakai, T. Hamasaki, M. Takao, T. Nishii, N. Nakamura, et al., Is the transverse acetabular ligament a reliable cup orientation guide? Computer simulation in 160 hips, *Acta Orthopaedica* 83 (5) (2012) 474–480.
- [10] N.G. Sotereanos, M.C. Miller, B. Smith, R. Hube, J.J. Sewecke, D. Wohlrab, Using intraoperative pelvic landmarks for acetabular component placement in total hip arthroplasty, *J. Arthroplasty* 21 (6) (2006) 832–840.
- [11] H. Archbold, B. Mockford, D. Molloy, J. McConway, L. Ogonda, D. Beverland, The transverse acetabular ligament: an aid to orientation of the acetabular component during primary total hip replacement, *Bone & Joint Journal* 88 (7) (2006) 883–886.
- [12] C.J. Pearce, S.A. Sexton, D. Davies, A. Khaleel, The transverse acetabular ligament may be used to align the acetabular cup in total hip arthroplasty, *Hip Int.* (1) (2008) 18.
- [13] N.J. Epstein, S.T. Woolson, N.J. Giori, Acetabular component positioning using the transverse acetabular ligament: can you find it and does it help? *Clin. Orthop. Relat. Res.* 469 (2) (2011) 412–416.
- [14] J.M. Elkins, J.J. Callaghan, T.D. Brown, The 2014 Frank Stinchfield Award: the 'landing zone' for wear and stability in total hip arthroplasty is smaller than we thought: a computational analysis, *Clin. Orthop. Relat. Res.* 473 (2) (2015) 441–452.
- [15] C.S. Ranawac, M.J. Maynard, Modern technique of cemented total hip arthroplasty, *Tech. Orthop.* 6 (3) (1991) 17–25.
- [16] L.D. Dorr, A. Malik, M. Dastane, Z. Wan, Combined anteversion technique for total hip arthroplasty, *Clin. Orthop. Relat. Res.* 467 (1) (2009) 119–127.
- [17] J.J. Callaghan, C. Engh Jr., T.K. Fehring, K.L. Garvin, P.F. Lachiewicz, T.M. Mabry, et al., How do I get out of this jam? Overcoming common intraoperative problems in primary total hip arthroplasty, *Instr. Course Lect.* 64 (2014) 307–325.
- [18] I. Richard Illgen, H.E. Rubash, The optimal fixation of the cementless acetabular component in primary total hip arthroplasty, *J. Am. Acad. Orthop. Surg.* 10 (1) (2002) 43–56.