



THE AGA KHAN UNIVERSITY

eCommons@AKU

Department of Anaesthesia

Medical College, Pakistan

April 2018

Palliative surgical gastrostomy under ultrasound-guided bilateral rectus sheath blocks in a head and neck cancer patient

Saima Rashid

Aga Khan University, saima.rashid@aku.edu

Faisal Shamim,

Aga Khan University, faisal.shamim@aku.edu

Maha Khan

Aga Khan University

Robyna Khan

Aga Khan University, robyna.khan@aku.edu

Follow this and additional works at: https://ecommons.aku.edu/pakistan_fhs_mc_anaesth



Part of the [Anesthesiology Commons](#)

Recommended Citation

Rashid, S., Shamim, F., Khan, M., Khan, R. (2018). Palliative surgical gastrostomy under ultrasound-guided bilateral rectus sheath blocks in a head and neck cancer patient. *Saudi Journal of Anesthesia*, 12(2), 371-373.

Available at: https://ecommons.aku.edu/pakistan_fhs_mc_anaesth/143

Palliative surgical gastrostomy under ultrasound-guided bilateral rectus sheath blocks in a head and neck cancer patient

Sir,

Palliative care aims to improve quality of life in patients facing problems associated with life-threatening illness.^[1] Incurable end-stage head and neck cancer lead to distressing symptoms and patients face unique challenges in maintaining adequate nutrition. Nearly 40% of patient suffers from dysphagia, and this is largely due to mechanical and functional obstruction and drug-induced side effects.^[1] Placement of gastrostomy tubes is the most common approach to ensuring safe delivery of adequate nutrition.^[2] Percutaneous endoscopic gastrostomy, surgically inserted open gastrostomy, and radiologically-inserted gastrostomy are the choices.^[2] Sometimes, the obstructing nature of tumor or limited mouth opening renders only the open surgical approach. At the same time, general anesthesia is required for the procedure with anticipated difficult airway. We are sharing our experience of ultrasound-guided truncal block for open surgical gastrostomy.

A 52-year-old female, weighing 45 kg, known case of the right alveolar invasive squamous cell carcinoma was scheduled for palliative surgical gastrostomy. The mass was arising from the right upper jaw [Figure 1], involving nose, hard palate, eyes, and there was gross bony destruction with extension into the right maxillary sinus. The patient and family were counseled in detail by ear, nose, and throat (ENT) team about nonresectable nature of tumor and required gastrostomy for nutritional support. The family was not willing for tracheostomy, but they have been explained

that tracheostomy will be performed only in case of loss of airway.

In the preoperative assessment, there was no significant past medical and surgical history. On airway examination, there was a right cheek lesion with no mouth opening. The tumor involved both eyes and obscured right nostril completely, but the left nostril was patent. We discussed with patient, family, and surgical team about an alternative technique for procedure that does not require airway handling. We also explained awake fiberoptic intubation but its complications or failure may result in tracheostomy. We also did explain that there may be mild pain at certain step during the procedure can be treated.

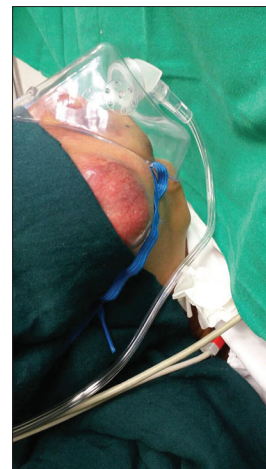

Figure 1: Large mass arising from the right cheek and upper jaw

A regional technique in the form of ultrasound-guided bilateral rectus sheath blocks was planned,^[3] though all preparations for general anesthesia, resuscitation drugs, and equipment were kept ready along with standby ENT team for emergency tracheostomy. After applying the standard monitoring (noninvasive blood pressure, electrocardiography SpO₂), area between xiphisternum and umbilicus (block site) was prepared with aseptic measures. High-frequency linear array probe is positioned just lateral to the umbilicus in an axial (transverse) plane. After identifying the layers of anterior abdominal wall, the transducer moved cephalad between costal margin and umbilicus. Skin puncture site was infiltrated using 25-gauge needle with 1 ml lignocaine 2%. We use Stimuplex needle exclusively for peripheral nerve blocks, so a 100 mm needle was inserted 3 cm lateral to the lateral edge of the transducer and advanced “in plane” from lateral to medial and superficial to deep. The needle is positioned deep to potential space between posterior border of rectus abdominis muscle, but superficial to posterior aspect of rectus sheath [Figure 2].^[4] This target site is referred as “posterior rectus sheath compartment.” Ropivacaine 0.25% 20 ml is incrementally injected while observing for the expanding anechoic

fluid collection. The same procedure is repeated on the contralateral side.

The patient tolerated surgery well, remained hemodynamically stable throughout, and the surgeon had no difficulty in performing the procedure. She was discharged home next day. This case highlights the utility of ultrasound-guided rectus sheath block as a very useful regional technique^[5] alternative to general anesthesia for short abdominal procedures, especially where airway is in jeopardy.

Declaration of patient consent

The authors certify that they have obtained all appropriate patient consent forms. In the form the patient(s) has/have given his/her/their consent for his/her/their images and other clinical information to be reported in the journal. The patients understand that their names and initials will not be published and due efforts will be made to conceal their identity, but anonymity cannot be guaranteed.

Financial support and sponsorship

Nil.

Conflicts of interest

There are no conflicts of interest.

**SAIMA RASHID, FAISAL SHAMIM,
MAHA KHAN, ROBYNA KHAN**

Department of Anaesthesiology, Aga Khan University, Karachi,
Pakistan

Address for correspondence:

Dr. Faisal Shamim,
Department of Anaesthesiology, Aga Khan University, P. O.
Box 3500, Stadium Road, Karachi 74800, Pakistan.
E-mail: faisal.shamim@aku.edu

References

1. Cocks H, Ah-See K, Capel M, Taylor P. Palliative and supportive care in head and neck cancer: United Kingdom National Multidisciplinary Guidelines. *J Laryngol Otol* 2016;130:S198-207.
2. Nugent B, Lewis S, O'Sullivan JM. Enteral feeding methods for nutritional management in patients with head and neck cancers being treated with radiotherapy and/or chemotherapy. *Cochrane Database Syst Rev* 2013. CD007904.
3. Yarwood J, Berrill A. Nerve blocks of the anterior abdominal wall. *Contin Educ Anaesth Crit Care Pain* 2010;10:182-6.
4. Salinas FV. How i do it: Ultrasound-guided bilateral rectus sheath blocks. *ASRA News* 2014;14:5-8.
5. Hasan MS, Ling KU, Vijayan R, Mamat M, Chin KF. Open gastrostomy under ultrasound-guided bilateral oblique subcostal transversus abdominis plane block: A case series. *Eur J Anaesthesiol* 2011;28:888-9.

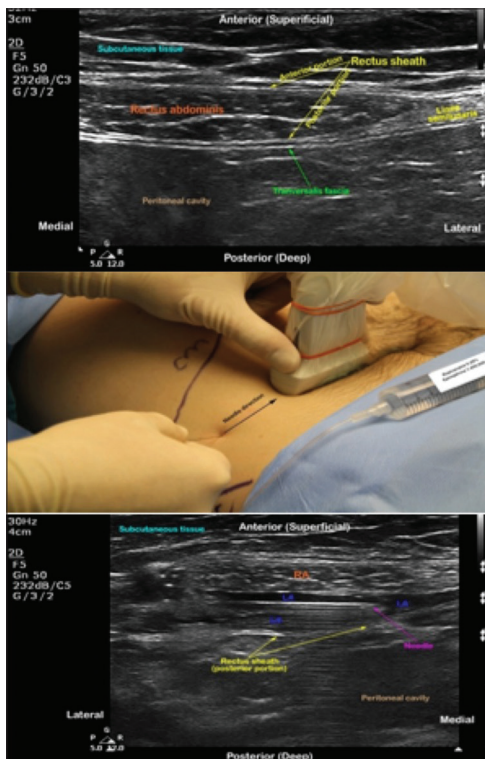


Figure 2: Ultrasound-guided rectus sheath block. Sonoanatomy, technique, and needle position shown in the upper, middle, and lower portion, respectively

Letters to Editor

This is an open access article distributed under the terms of the Creative Commons Attribution-NonCommercial-ShareAlike 3.0 License, which allows others to remix, tweak, and build upon the work non-commercially, as long as the author is credited and the new creations are licensed under the identical terms.

How to cite this article: Rashid S, Shamim F, Khan M, Khan R. Palliative surgical gastrostomy under ultrasound-guided bilateral rectus sheath blocks in a head and neck cancer patient. Saudi J Anaesth 2018;12:371-3.

© 2018 Saudi Journal of Anesthesia | Published by Wolters Kluwer - Medknow

Access this article online	
Website: www.saudija.org	Quick Response Code 
DOI: 10.4103/sja.SJA_770_17	