



THE AGA KHAN UNIVERSITY

eCommons@AKU

Section of Orthopaedic Surgery

Department of Surgery

January 2018

# Sprengel's deformity.

Muhammad Younus Khan Durrani Khan Durrani  
*Aga Khan University*, [younus.durrani@aku.edu](mailto:younus.durrani@aku.edu)

Abdul Malik Amir Humza Sohail,  
*Aga Khan University*

Inamullah Khan  
*Vanderbilt University Medical Center, Nashville TN, USA.*

Pervaiz Hashmi  
*Aga Khan University*, [pervaiz.hashmi@aku.edu](mailto:pervaiz.hashmi@aku.edu)

Follow this and additional works at: [https://ecommons.aku.edu/pakistan\\_fhs\\_mc\\_surg\\_orthop](https://ecommons.aku.edu/pakistan_fhs_mc_surg_orthop)



Part of the [Orthopedics Commons](#), and the [Surgery Commons](#)

## Recommended Citation

Durrani, M. K., Amir Humza Sohail,, A., Khan, I., Hashmi, P. (2018). Sprengel's deformity.. *Journal of Ayub Medical College, Abbottabad*, 30(1), 135-137.

**Available at:** [https://ecommons.aku.edu/pakistan\\_fhs\\_mc\\_surg\\_orthop/41](https://ecommons.aku.edu/pakistan_fhs_mc_surg_orthop/41)

## CASE REPORT

## SPRENGEL'S DEFORMITY

Muhammad Younus Khan Durrani, Amir Humza Sohail\*, Inamullah Khan\*\*, Pervaiz Hashmi

Department of Orthopedic Surgery, \*The Aga Khan University Medical College, The Aga Khan University Hospital Karachi, Pakistan, \*\*Comprehensive Spine Center, Vanderbilt University Medical Center, Nashville TN-USA.

Various shoulder bone deformities have been identified in the pediatric age group, with the most common being undescended scapula. Sprengel's deformity is dysplasia and malposition of the scapula, especially in the supraspinatus portion, mainly due to abnormal descent in the embryonic period. The clavicle is shorter and has a different contour. In some patients cervical spine deformities are also noted. This is a case of 3 years old girl presented to the clinic with difficulty in abducting right shoulder and sleeping with an internal rotation of the right arm. With physical examinations and radiological investigations sprengel's deformity was diagnosed. Sprengel's deformity is a male predominant disease which almost never occurs in isolation and is usually associated with deformities in the thoracic rib cage and the cervical and thoracic vertebrae. Our patient also had hyperpigmentation along the lines of Blaschko, which has never been previously reported with Sprengel's deformity. Sprengel's may have an association with cutaneous mosaicism syndrome

**Keywords:** Sprengel's deformity; Shoulder deformity; Cutaneous mosaicism syndrome

**Citation:** Durrani MYK, Sohail AH, Khan I, Hashmi P. Sprengel's deformity. J Ayub Med Coll Abbottabad 2018;30(1):135-7.

## INTRODUCTION

Various shoulder bone deformities have been identified in the pediatric age group, with the most common being undescended scapula.<sup>1</sup> It was first described in 1863 by Eulenberg as high grade dislocation of the scapula. Later, few more cases were reported followed by four cases reported by Kolliker who also coined the term Sprengel's deformity.<sup>2-4</sup>

Sprengel's deformity is the dysplasia and malposition of the scapula, mainly due to abnormal descent in the embryonic period.<sup>5</sup> In some patients cervical spine deformities are also noted. Secondary ossified omovertebral bone articulating with spinous processes and vertebral (infraspinatus) margin of the scapula may be noted.<sup>5-7</sup> In some cases, regional atrophy leading to limitation of shoulder movements may follow.

## CASE

A 3 years and 6 months old girl, born to non-consanguineous parents, presented to the orthopedic surgery clinic with complaints of difficulty in overhead movement of right upper limb. The complaint was not associated with any pain or any other musculoskeletal symptoms. She was left handed and slept with her right hand internally rotated. There were no systemic or constitutional symptoms. In birth history, the girl was first child of the family, born full-term via spontaneous vaginal delivery. Prenatal and postnatal history was unremarkable. Breastfeeding

was done till two years of age. Developmental history was unremarkable with neck holding, crawling and walking being achieved at three and a half months of age, eight months, and at 12 months of age, respectively. Immunization status was up-to-date. Both weight and height of the child were normal for age. Family history was negative for any musculoskeletal deformities.

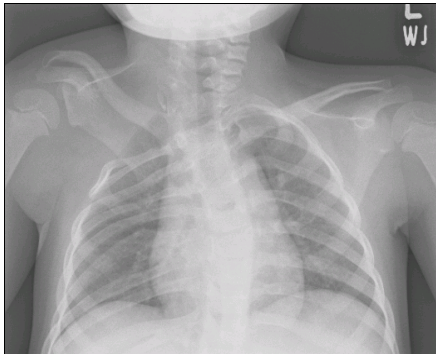
Physical examination showed asymmetry in both the shoulders. The right shoulder was higher than the left. A hyper pigmented patch was noted along the lines of Blaschko on the left lateral chest wall. On palpation, a hard swelling was noted over the right shoulder. Local signs of inflammation were absent. Both the active and passive movements were restricted in the right shoulder and crepitus was also presented. Abduction of the arm above 90 degrees elicited pain. Left shoulder examination was unremarkable. Power in all four limbs was normal and no muscle atrophy was noted. Neck, spine and hip examinations were unremarkable and neurological exam did not reveal any positive findings.

CT scan of the thorax with cervical and thoracic spine was performed which showed segmental abnormality of cervical vertebra at the cervicothoracic junction that was resulting in left-sided tilt of neck. High rising right scapula was also noted. Slight anterior wedging of T9 vertebral body was noted. Multiple rib deformities including fusion of the first rib at the anterior and posterior ends with separation of the shaft and posterior end fusion of right 8<sup>th</sup> and 9<sup>th</sup> ribs was also fused. No

soft tissue abnormality was identified. Scoliosis of thoracic spine was also noted with convexity toward the left side.

Based on the history and clinical examination and the CT scan findings, the diagnosis of Sprengel's deformity was made. The parents were reassured and surgical correction for cosmetic purposes was advised which could not be performed because of parental refusal. She had two annual follow ups; no change in signs or symptoms of neurovascular damage were noted.

As regards the chest wall hyperpigmentation, the child was suspected to have cutaneous mosaicism syndrome. High resolution karyotyping was advised to confirm the diagnosis, but it could not be performed due to lack of technical facilities.



**Figure-1: Segmental abnormality of cervical vertebra at cervicothoracic junction resulting in the left-sided tilt of neck. High rising right scapula is noted.**

## DISCUSSION

Sprengel's deformity is the most common congenital malformation of the shoulder girdles.<sup>1</sup> It has a male predominance with the deformity being three times more common among males than females.<sup>8</sup> Depending upon the severity of the deformity, it may present during childhood or later during adolescence. Generally, the diagnosis is made in early childhood; however, prenatal diagnosis of Sprengel's deformity via Ultrasound has also been reported.<sup>9</sup>

Sprengel's deformity almost never occurs in isolation and is usually associated with deformities in the thoracic rib cage and the cervical and thoracic vertebrae. Most commonly, deformities such as congenital scoliosis, fused or absent ribs, chest wall asymmetry, cervical ribs and cervical spina bifida have been noted.<sup>10</sup> As

mentioned previously skeletal deformities including scoliosis and fused ribs were present in our patient.

Various syndromes have been linked to Sprengel's deformity. The most common one is the Klippel-Feil syndrome, which is present in about 19–27% of patients with Sprengel's deformity.<sup>11</sup> Other associated syndromes include X-linked dominant hydrocephalus, mental disturbance syndrome, diastematomyelia.<sup>10</sup>

Although no particular evidence of any such syndrome was found in our case, one unusual finding, skin hyperpigmentation along the lines of Blaschko, may point towards the possibility of associated cutaneous conditions. Also, Sprengel's deformity has been reported previously with cutaneous conditions, such as Gorlin syndrome and cutaneous hemangiomas.<sup>13</sup> Hyperpigmentation along the lines of Blaschko, as seen in our patient, has never been previously reported with Sprengel's deformity. Although a definitive diagnosis of cutaneous syndrome could not be made in our patient, this case report points towards the possibility of a possible association between Sprengel's deformity and cutaneous mosaicism syndrome. To the best of our knowledge cutaneous mosaicism syndrome has never been previously reported with Sprengel's deformity.

In certain cases of Sprengel's deformity, exercise may help improve outcome.<sup>8</sup> Other cases, particularly those associated with severe deformity, have surgery as the first-line treatment.<sup>8</sup> Favorable outcome has been experienced in patients treated via the Mears procedure.<sup>12</sup> In our patient, there was moderate deformity (grade 3 of Cavendish classification) and thus only surgical correction for cosmetic purposes was offered as the deformity was not significantly impairing the day to day functioning of the patient.

## REFERENCES

1. Grogan DP, Stanley EA, Bobecko WP. The congenital undescended scapula. Surgical correction by the Woodward procedure. *J Bone Joint* 1983;65(5):598–605.
2. Eulenber M. Casuistische mittheilungen aus dem gebiete der orthopadie. *Arch Klin Chir* 1863;4:301–11.
3. Willett A, Walsham WJ. A second case of malformation of the left shoulder-girdle; removal of the abnormal portion of bone; with remarks on the probable nature of the deformity. *Med Chir Trans* 1883;66:145–58.
4. Kolliker T. Mittheilungen aus der chirurgischen casuistic und kleinere mittheilungen. Bemerkungen zum aufsatze von Dr. Sprengel. Die angebohrne verschiebung des schulterblattes nach oben. *Arch Klin Chir* 1891;42:925.
5. Ogden JA, Conlogue GJ, Phillips MS, Bronson ML. Sprengel's deformity. *Skelet Radiol* 1979;4(4):204–11.
6. Chen CP. Syndromes and disorders associated with omphalocele (III): single gene disorders, neural tube defects, diaphragmatic defects and others. *Taiwan J Obstet Gynecol* 2007;46(2):111–20.

7. Ferlini A, Ragno M, Gobbi P, Marinucci C, Rossi R, Zanetti A, *et al.* Hydrocephalus, skeletal anomalies, and mental disturbances in a mother and three daughters: a new syndrome. *Am J Med Genet* 1995;59(4):506–11.
8. Thacker MM. Sprengel Deformity [Internet]. Medscape. [cited 2014 Dec 08]. Available from: <http://www.emedicine.com/Orthoped/topic445.htm>
9. Chinn DH. Prenatal ultrasonographic diagnosis of Sprengel's deformity. *J Ultrasound Med* 2001;20(6):693–7.
10. Rashid M. Sprengel's Deformity o A Review Of The Literature. *Internet J Orthop Surg* 2009;15(2):1–6.
11. Radio FC, Digilio MC, Capolino R, Dentici ML, Unolt M, Alesi V, *et al.* Sprengel anomaly in deletion 22q11. 2 (DiGeorge/Velo–Cardio–Facial) syndrome. *Am J Med Genet A* 2016;170(3):661–4.
12. Bhasker AR, Khullar S, Habeeb M. Outcome of Mears procedure for Sprengel's deformity. *Indian J Orthop* 2011;45(2):132–5.
13. Muzio LL. Nevoid basal cell carcinoma syndrome (Gorlin syndrome). *Orphanet J Rare Dis* 2008;3(1):32.

*Received: 27 December, 2016*

*Revised: 3 October, 2017*

*Accepted: 12 November, 2017*

**Address for Correspondence:**

**Inamullah Khan**, 2005 Capers Ave Apt 14 Nashville TN, 37212-United States

**Cell:** +92 346 559 9044

**Email:** [inamullah.aku.co15@gmail.com](mailto:inamullah.aku.co15@gmail.com)