



9-2017

## Spontaneous disc resolution: Illustrative Cases with supportive argument for a more conservative approach

Muhammad Waqas Shaiq  
*Aga Khan University Hospital*

Muhammad Shahzad Shamim  
*Aga Khan hospital karachi*

Follow this and additional works at: <https://ecommons.aku.edu/pjns>

 Part of the [Neurology Commons](#)

### Recommended Citation

Shaiq, Muhammad Waqas and Shahzad Shamim, Muhammad (2017) "Spontaneous disc resolution: Illustrative Cases with supportive argument for a more conservative approach," *Pakistan Journal of Neurological Sciences (PJNS)*: Vol. 12 : Iss. 3 , Article 7.  
Available at: <https://ecommons.aku.edu/pjns/vol12/iss3/7>

# Spontaneous disc resolution: Illustrative Cases with supportive argument for a more conservative approach

Muhammad Waqas Shaiq<sup>1</sup>, Muhammad Shahzad Shamim<sup>2</sup>

**Corresponding to:** M Shahzad Shamim, MCPS, MRCS, FCPS, FEBNS, FACS, FRCS(Eng), FRCSGlas(NeuroSurg), Director, Internship Program, Director, Surgical Neuro-Oncology Fellowship Program, Assistant Professor and Consultant Neurosurgeon, Aga Khan University Hospital, Karachi, Email: shahzad.shamim@aku.edu

**Date of submission:** April 21, 2017 **Date of revision:** May 30, 2017 **Date of acceptance:** June 1, 2017

## ABSTRACT

### BACKGROUND:

The phenomenon of spontaneous disc resolution is well described in literature, yet it is underappreciated and often overlooked in the process of clinical decision making. We report three different cases and discuss how the phenomenon of spontaneous disc resolution can affect clinical decision-making.

### CASE DESCRIPTION:

The first patient presented with S1 lumbar radiculopathy and a large disc prolapse at L5-S1. He opted against surgical intervention. His symptoms resolved with conservative management with complete resolution of disc at 6 months on MRI. In another case disc resolved at L3-4 but developed at L4-5 level. In the third case patient underwent micro discectomy at L4-5 level and came back with recurrent disc at the same level.

### CONCLUSION:

The phenomenon of spontaneous disc resolution is under estimated. Given the possibility of spontaneous resolution and significant morbidity associated with the disc surgery, a conservative approach should be given more precedence over surgery.

### KEY WORDS:

Lumbar disc, disc resolution, micro discectomy

### INTRODUCTION:

With over 300,000 cases performed annually in US alone[4, 11, 12], lumbar microdiscectomy is one of the most commonly performed neurosurgical procedures[29]. It is also considered one of the safest neurosurgical procedures. However, 8-25% patients have also been reported to develop failed back surgery, a chronic debilitating condition largely attributed to scar formation[6, 22]. Indeed, scarring is an inevitable consequence of any surgical procedure, and in case of disc surgery, may involve nerve roots, leading to persistent radicular pain, which is difficult and expensive, if not impossible to treat[6].

The first report of natural history of disc herniation was published by Weber et al, in a landmark paper which completely changed the way we looked at these cases[27]. Subsequent prospective, multicenter studies have helped us to better understand the pathophysiology of radicular pain,

and it is now common knowledge that even though the immediate results of surgery for disc herniation related radiculopathy are superior to non-operative management, two-year outcomes are not too different[20]. Radiological data likewise supports the notion that given adequate time, even large herniated discs and sequestrations tend to resolve on their own[1, 3, 5, 10, 13, 21, 25, 26]. A review article by Macki et al reported spontaneous disc regression in 53 cases over a mean  $9.27 \pm 13.32$  months with symptomatic relief in  $1.34 \pm 1.33$  months soliciting conservative approach[16].

Herein, we report three illustrative cases of lumbosacral radiculopathy managed in different ways and the patients ending up with different outcomes.

### METHODS:

We conducted literature search on spontaneous lumbar disc resolution using PubMed, CINAHL,

and Cochrane databases. Articles on natural history of disc disease were reviewed. We also reviewed articles on surgical complications of disc disease. We then selected three cases of lumbar disc disease with different management and different outcomes. With the help of cases and literature we debate the utility of lumbar disc surgery versus conservative management.

## RESULTS:

### Case 1

A 40 year-old gentleman came to our office complaining of moderate to severe left lower extremity pain in S1 distribution for two months. He had an Oswestry Disability Index (ODI) score of 50 and the pain had rendered him dependent for most of his activities of daily living. On examination he did not have a neurological deficit. MRI showed a central disc prolapse at L5-S1 level slightly more towards left side (Fig 1a). He was explained various options for management, including surgery and conservative management. Over days his pain subsided with conservative management and he came back 6 months later with a repeat MRI scan. Repeat study showed a complete resolution of herniated disc and he has remained symptom free at more than 2 years follow up (Fig 1b).

### Case 2

A 41 year-old gentleman came to our office 2 years ago, with moderate to severe left lower extremity pain. He has had episodes of radiculopathy for several years but since 2 months, the pain had been become unbearable. He had clinical involvement of left L5 dermatome and MRI revealed a large paracentral disc herniation at L4-5. He was advised surgery, which he refused. His pain resolved and he remained well for two years. However, two years later he returned with excruciating pain and numbness in the same leg. Left ankle jerk was absent with mild weakness of plantarflexion. Repeat MRI showed a posterolateral disc prolapse at L5-S1 with complete resolution of previously noticed L4-5 disc Fig 2a, 2b.

### Case 3

A 55 year-old lady presented with a history right lower extremity pain for one year. Nerve root stretch signs were positive with weakness of extensor hallucis longus. MRI showed right posterolateral disc prolapse with compression of nerve root at L4-5 level. She underwent micro discectomy (Fig 3a). After two weeks of surgery she started complaining of similar pain in right lower extremity. The pain did not subside with conservative management and a repeat MRI at one month showed recurrent disc at same level (Fig 3b).

## DISCUSSION

Every spine surgeon would be able to associate with each one of these cases. Every spine surgeon would also be able to recall that most of his or her patients do not follow the course of either of these cases, and generally do well. Unfortunately, the patients who have an expected clinical outcome are easily forgotten and those who have had a more trouble some course remain etched onto ones memory. It is this recall bias which has inspired us to write this paper.

The indications for spine surgery have not changed since the introduction of microdiscectomy. To simplify, even though micro discectomy offers almost immediate pain relief associated with prolapsed disc and nerve root compression, surgery is usually reserved for the very few, who present either with progressive motor deficits, or intractable pain not responding to conservative management. With advances in pain management, most patients do not require surgery for acute pain and usually a trial of 6-8 weeks is preferred[9]. Less than 10 % of patients with symptomatic disc prolapse eventually require surgery[9]. In fact, if the patient is able to cope with the initial discomfort, 2-year outcome for patients treated with or without surgery, are similar[20]. It is therefore not inappropriate to say that lumbar disc prolapse in the absence of progressive motor deficits is a self-limiting disease.

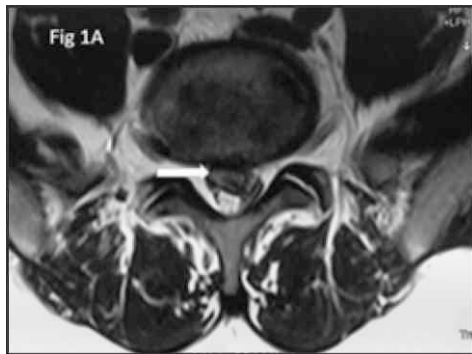
Interestingly, there are very few self-limiting conditions in the entire domain of all surgical specialties, which require surgical intervention. Yet, rates of spine surgery have been noted to show a constant increase[8, 9, 28]. These rising numbers are not peculiar to a certain part of the world, but have been reported from countries in different regions[7]. Not only that, the indications and timing of spine surgery is also a matter of concern, as several reports show marked variations for both, even across hospitals located in same regions of a country[18]. The increasing numbers are perhaps due to the fact that the modern spine surgery has become less traumatic, and thus more tolerable. The introduction of microscope and endoscope have made it possible for the operation to be carried out with smaller incisions and very little tissue injury, making it possible to be performed as a day case, a practice now common in a number of centers. Quest is still on to make it even less destructive with an increasing number of papers now focusing on further refinement of the technique. With these advances, it is understandably argued that the comparative cost analysis between various treatment options for symptomatic disc prolapse favors surgery[17]. The analysis however, does not take into account the

cost of treatment of failed surgeries, which are one of the most expensive diseases to be treated, both in terms of actual cost of treatment, as well as the loss of quality adjusted life years[19]. Moreover, the operation, whether done with a microscope or endoscopic, however safe, is not free of complications. The reported rate of complications from microdiscectomy vary and include nerve root injury, dural tear, wound related complications, recurrent disc[23, 24]. Even though the overall incidence of complications may not appear discouraging[24], in the occasional patient who does develop post-operative discitis (0.2-15%) [14] or

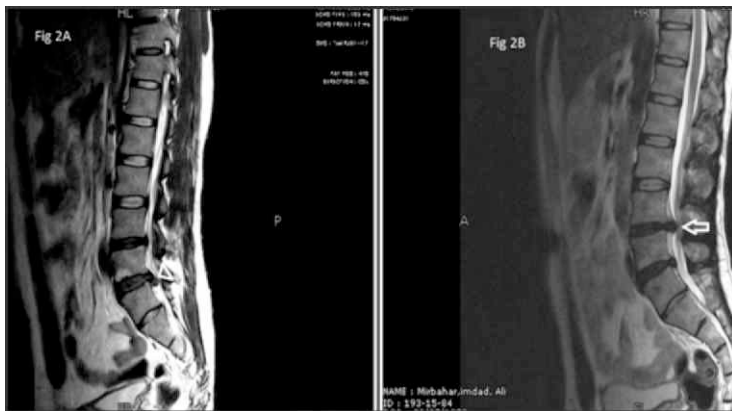
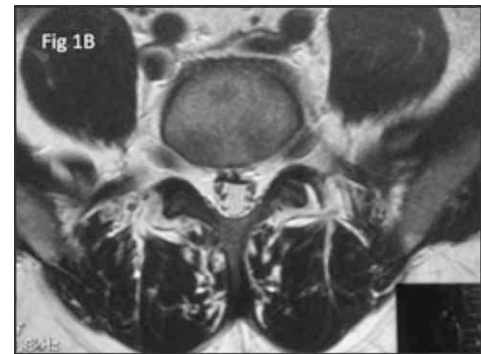
failed back syndrome (10% to 40%)[2], it becomes difficult to justify the indication. Similarly, the 10-year risk of re-operations for disc prolapse have been reported in the range of 3.3% to 24 % depending upon the surgical technique[4, 15, 24].

**CONCLUSION:**

The phenomenon of spontaneous disc resolution is under estimated. Given the possibility of spontaneous resolution and significant morbidity associated with the disc surgery, a conservative approach should be given more precedence over surgery.

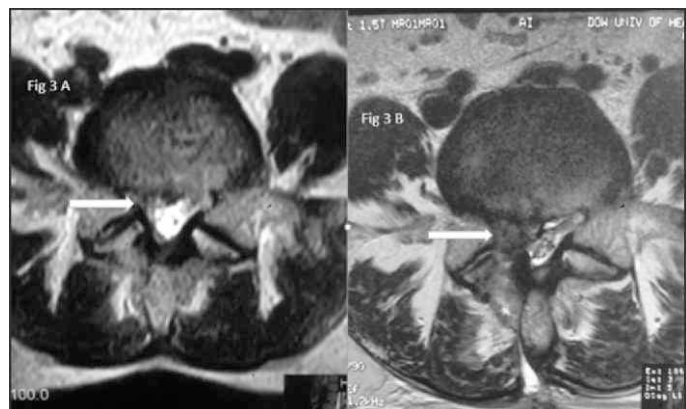


**Figure 1 A.**  
T2 weighted axial section showing disc prolapse at L5-S1 level (arrow). Complete regression of disc on follow up (1B).



**Figure 2A, 2B.**  
T2 weighted sagittal view of lumbar spine – resolution of previously visible disc at L3-4 (arrow). A new disc herniation can be appreciated at L4-5 level (arrow head).

**Figure 3A.**  
Preoperative MRI, T2 weighted axial section right posterolateral disc herniation (arrow). Fig 3B shows recurrent disc at the same level along with post-operative changes.



## REFERENCE:

1. Awad JN, Moskovich R. Lumbar disc herniations: surgical versus nonsurgical treatment. *Clinical orthopaedics and related research* 2006;443:183-197.
2. Bokov A, Isrelov A, Skorodumov A, Aleynik A, Simonov A, Mlyavykh S. An analysis of reasons for failed back surgery syndrome and partial results after different types of surgical lumbar nerve root decompression. *Pain physician* 2011;14(6):545-557.
3. Bozzao A, Gallucci M, Masciocchi C, Aprile I, Barile A, Passariello R. Lumbar disk herniation: MR imaging assessment of natural history in patients treated without surgery. *Radiology* 1992;185(1):135-141.
4. Bruske-Hohlfeld I, Merritt JL, Onofrio BM, Stonnington HH, Offord KP, Bergstralh EJ, et al. Incidence of lumbar disc surgery. A population-based study in Olmsted County, Minnesota, 1950-1979. *Spine (Phila Pa 1976)* 1990;15(1):31-35.
5. Bush K, Cowan N, Katz DE, Gishen P. The natural history of sciatica associated with disc pathology: a prospective study with clinical and independent radiologic follow-up. *Spine* 1992;17(10):1205-1212.
6. Chan Cw, Peng P. Failed back surgery syndrome. *Pain Medicine* 2011;12(4):577-606.
7. Cherkin DC, Deyo RA, Loeser JD, Bush T, Waddell G. An international comparison of back surgery rates. *Spine* 1994;19(11):1201-1206.
8. Davis H. Increasing rates of cervical and lumbar spine surgery in the United States, 1979-1990. *Spine (Phila Pa 1976)* 1994;19(10):1117-1123; discussion 1123-1114.
9. Deyo RA, Gray DT, Kreuter W, Mirza S, Martin BI. United States trends in lumbar fusion surgery for degenerative conditions. *Spine* 2005;30(12):1441-1445.
10. Fagerlund M, Thelander U, Friberg S. Size of lumbar disc hernias measured using computed tomography and related to sciatic symptoms. *Acta radiologica* 1990;31(6):555-558.
11. Frymoyer J, Cats-Baril W. An overview of the incidences and costs of low back pain. *The orthopedic clinics of North America* 1991;22(2):263-271.
12. orthopedic clinics of North America 1991;22(2):263-271.
13. Hart LG, Deyo RA, Cherkin DC. Physician office visits for low back pain: frequency, clinical evaluation, and treatment patterns from a US national survey. *Spine* 1995;20(1):11-19.
14. Jensen TS, Albert HB, Soerensen JS, Manniche C, Leboeuf-Yde C. Natural course of disc morphology in patients with sciatica: an MRI study using a standardized qualitative classification system. *Spine* 2006;31(14):1605-1612.
15. Kaliaperumal C, Kuechler D, Kaar G, Marks C, O'Sullivan M. Does Surgical Technique Affect the Incidence of Spondylodiscitis Post-Lumbar Microdiscectomy? A Retrospective Analysis of 3063 Patients. *Spine* 2013;38(4):364-367.
16. Kim CH, Chung CK, Park CS, Choi B, Kim MJ, Park BJ. Reoperation rate after surgery for lumbar herniated intervertebral disc disease: nationwide cohort study. *Spine* 2013;38(7):581-590.
17. Macki M, Hernandez-Hermann M, Bydon M, Gokaslan A, McGovern K, Bydon A. Spontaneous regression of sequestered lumbar disc herniations: Literature review. *Clinical neurology and neurosurgery* 2014;120:136-141.
18. Malter AD, Larson EB, Urban N, Deyo RA. Cost-Effectiveness of Lumbar Discectomy for the Treatment of Herniated Intervertebral Disc. *Spine* 1996;21(9):1048-1054.
19. McGuire SM, Phillips KT, Weinstein JN. Factors that affect surgical rates in Iowa. *Spine* 1994;19(18):2038-2040.
20. North RB, Kidd D, Shipley J, Taylor RS. Spinal cord stimulation versus reoperation for failed back surgery syndrome: a cost effectiveness and cost utility analysis based on a randomized, controlled trial. *Neurosurgery* 2007;61(2):361-369.
21. Peul WC, van den Hout WB, Brand R, Thomeer RT, Koes BW. Prolonged conservative care versus early surgery in patients with sciatica caused by lumbar disc herniation: two year results of a randomised controlled trial. *bmj* 2008;336(7657):1355-1358.
22. Saal JA, Saal JS. Nonoperative treatment of



- lumbar intervertebral disc with radiculopathy: an outcome study. *Spine* 1989;14(4):431-437.
23. Shamim MS, Enam SA, Qidwai U. Fuzzy Logic in neurosurgery: predicting poor outcomes after lumbar disk surgery in 501 consecutive patients. *Surgical neurology* 2009;72(6):565-572.
  24. Shamim MS, Parekh MA, Bari ME, Enam SA, Khursheed F. Microdiscectomy for lumbosacral disc herniation and frequency of failed disc surgery. *World neurosurgery* 2010;74(6):611-616.
  25. Shriver MF, Xie JJ, Tye EY, Rosenbaum BP, Kshetry VR, Benzel EC, et al. Lumbar microdiscectomy complication rates: a systematic review and meta-analysis. *Neurosurgical focus* 2015;39(4):E6.
  26. Teplick JG, Haskin ME. Spontaneous regression of herniated nucleus pulposus. *American journal of neuroradiology* 1985;6(3):331-335.
  27. Weber H. Lumbar disc herniation: a controlled, prospective study with ten years of observation. *Spine* 1983;8(2):131-140.
  28. Weber H. Spine Update The Natural History of Disc Herniation and the Influence of Intervention. *Spine* 1994;19(19):2234-2238.
  29. Weinstein JN, Lurie JD, Olson P, Bronner KK, Fisher ES, Morgan MTS. United States trends and regional variations in lumbar spine surgery: 1992–2003. *Spine* 2006;31(23):2707.
  30. Weinstein JN, Tosteson TD, Lurie JD, Tosteson AN, Hanscom B, Skinner JS, et al. Surgical vs nonoperative treatment for lumbar disk herniation: the Spine Patient Outcomes Research Trial (SPORT): a randomized trial. *Jama* 2006;296(20):2441-2450.

Conflict of interest: Author declares no conflict of interest.  
Funding disclosure: Nil

Author's contribution:

Fareed Ahmed; concept, data collection, data analysis, manuscript writing, manuscript review  
Muhammad Shahzad Shamim; data collection, data analysis, manuscript writing, manuscript review  
Sidra Asad Ali; data analysis, manuscript writing, manuscript review