

Washington University School of Medicine Digital Commons@Becker

Open Access Publications

2018

Treatment of intra-articular hip malignancy with extra-articular resection, preservation of the acetabular columns, and total hip arthroplasty

Joel E. Wells

Washington University School of Medicine in St. Louis

John C. Clohisy

Washington University School of Medicine in St. Louis

Regis J. O'Keefe

Washington University School of Medicine in St. Louis

Follow this and additional works at: https://digitalcommons.wustl.edu/open_access_pubs

Recommended Citation

Wells, Joel E.; Clohisy, John C.; and O'Keefe, Regis J., "Treatment of intra-articular hip malignancy with extra-articular resection, preservation of the acetabular columns, and total hip arthroplasty." *Arthroplasty Today*.4,4. 431-435. (2018).
https://digitalcommons.wustl.edu/open_access_pubs/7408

This Open Access Publication is brought to you for free and open access by Digital Commons@Becker. It has been accepted for inclusion in Open Access Publications by an authorized administrator of Digital Commons@Becker. For more information, please contact engeszer@wustl.edu.



Case report

Treatment of intra-articular hip malignancy with extra-articular resection, preservation of the acetabular columns, and total hip arthroplasty

Joel E. Wells, MD, MPH^{*}, John C. Clohisy, MD, Regis J. O'Keefe, MD, PhD

Department of Orthopaedic Surgery, Washington University School of Medicine, St. Louis, MO, USA

ARTICLE INFO

Article history:

Received 10 June 2018

Received in revised form

13 July 2018

Accepted 22 July 2018

Available online 7 September 2018

Keywords:

Hip

Reconstruction

Tumor

Hip replacement

Arthroplasty

Malignancy

ABSTRACT

Intra-articular malignant lesions of the hip present significant challenges. Resection often requires large resection of the acetabular bone and pelvic columns. Concurrent reconstruction options after intra-articular hip tumors are challenging and may necessitate the use of techniques and implants with uncertain long-term survivorship. We present a case of an intra-articular hip malignancy with extra-articular resection and preservation of the acetabular columns with reconstruction using a cementless acetabular shell fixed with screws.

© 2018 The Authors. Published by Elsevier Inc. on behalf of The American Association of Hip and Knee Surgeons. This is an open access article under the CC BY-NC-ND license (<http://creativecommons.org/licenses/by-nc-nd/4.0/>).

Introduction

Intra-articular malignant lesions of the hip are uncommon, yet when encountered present significant challenges in both resection technique and joint reconstruction options. En bloc resection of an intra-articular hip tumor is often accompanied with resection of the anterior and/or posterior columns of the pelvis, thus compromising pelvic stability and continuity. Concurrent reconstruction is challenging and may necessitate the use of techniques and implants with uncertain long-term survivorship [1] and high complication rates. Such techniques include acetabular reconstruction with combinations of pelvic plating, structural allografts, reconstruction cage, cup-cage constructs, saddle prostheses, and stemmed iliac prosthesis [2–11]. Theoretically, extra-articular acetabular resection with preservation of the anterior and posterior columns would maintain pelvic continuity and stability and

would potentially allow acetabular reconstruction using a cementless acetabular shell fixed with screws. Contemporary cementless acetabular fixation in the revision arthroplasty setting is associated with excellent long-term survivorship and is the optimal reconstructive technique for the majority of acetabular bone loss problems [12,13]. In this case report, we describe a resection and reconstructive technique for an intra-articular malignancy of the hip that to our knowledge has not been reported. Namely, we present an extra-articular en bloc resection of the hip for intra-articular clear-cell chondrosarcoma with preservation of the anterior and posterior columns, using the principles of the Ganz Bernese periacetabular osteotomy (PAO) [14] combined with cementless acetabular fixation without a need for more complex acetabular/pelvic reconstruction strategies.

Case history

A 60-year-old man presented to the senior author (R.O.) with 9 months of left hip groin pain that initially presented with running. The symptoms persisted despite modification of activities, physical therapy, and cessation of running. On physical examination, he had an antalgic gait, full abductor strength, hip flexion to 90°, internal rotation of 5° with pain, and external rotation of 20°. The preoperative modified Harris Hip Score (mHHS) was 72 (mild pain, slight limp, no support, 6 blocks, normal stairs, any chair 1 hour,

One or more of the authors of this paper have disclosed potential or pertinent conflicts of interest, which may include receipt of payment, either direct or indirect, institutional support, or association with an entity in the biomedical field which may be perceived to have potential conflict of interest with this work. For full disclosure statements refer to <https://doi.org/10.1016/j.artd.2018.07.007>.

^{*} Corresponding author. Department of Orthopaedic Surgery, University of Texas Southwestern Medical School, 1801 Inwood Rd., Dallas, TX 75390, USA. Tel.: +1 972 669 7070.

E-mail address: joel.wells@utsouthwestern.edu

<https://doi.org/10.1016/j.artd.2018.07.007>

2352-3441/© 2018 The Authors. Published by Elsevier Inc. on behalf of The American Association of Hip and Knee Surgeons. This is an open access article under the CC BY-NC-ND license (<http://creativecommons.org/licenses/by-nc-nd/4.0/>).

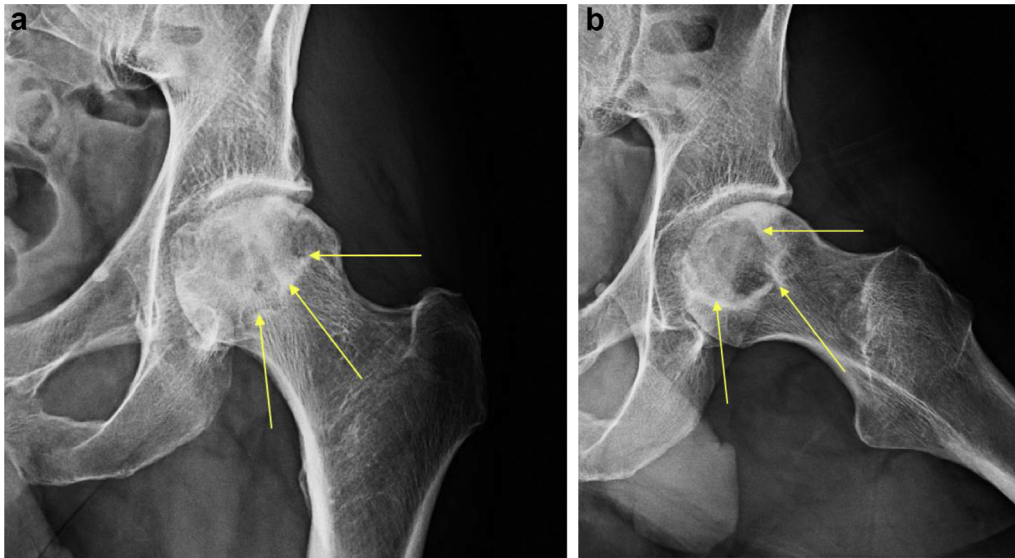


Figure 1. (a) Preoperative anteroposterior (AP) radiograph demonstrating femoral head lesion (arrows). (b) Preoperative frog-lateral radiograph.

easy shoes and socks, and able to take public transportation), Short Form-12 physical component summary scale was 56.7, Short Form-12 mental component summary scale was 62.39, and University of California Los Angeles activity score was 10 (regularly participate in impact sports).

Radiographs revealed a lytic lesion with a surrounding sclerotic border in the left femoral head (Fig. 1). Magnetic resonance imaging demonstrated a hyperintense heterogeneous lesion within the femoral head with violation of the subchondral plate and associated femoral head fracture (Fig. 2). The patient was referred to our practice for further evaluation and management. A percutaneous biopsy was performed by interventional radiology through a lateral approach through the greater trochanter to limit soft tissue contamination. Histological evaluation was consistent with a diagnosis of clear-cell chondrosarcoma. Preoperative staging studies, computed tomography of the chest, were negative for metastatic disease. The diagnostic studies indicated intra-articular extension of the tumor, and therefore, an extra-articular en bloc resection of the hip was advised. Given our extensive experience

with the PAO [15], we planned to perform an intra-articular resection with preservation of both the anterior and posterior columns and reconstruction of the acetabulum with standard cementless acetabular fixation. Additional reconstructive options (cup-cage, acetabular augments, and allograft) were available, if acetabular column integrity and/or pelvic continuity was compromised during tumor resection or if large segmental defect was created.

The patient was informed that data concerning the case would be submitted for publication, and he gave informed consent.

Surgical technique

The patient was positioned in the lateral decubitus position. A Kocher-Langenbeck [16,17] posterior approach was used, making sure to excise the previous biopsy tract. Incision was carried out along the long axis of the femur distally and proximally along the anterior margin of the gluteus maximus. Initial dissection was performed posteriorly to identify the piriformis and external

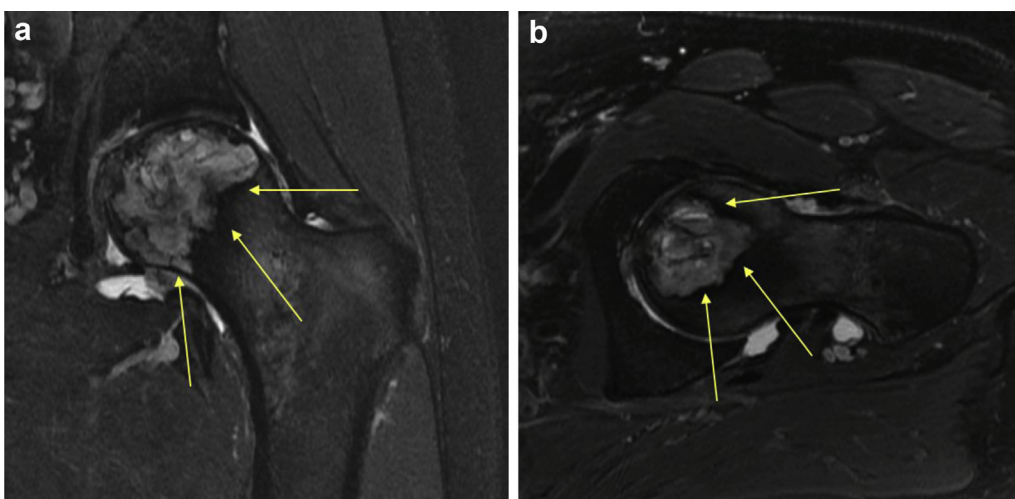


Figure 2. (a) Preoperative MRI (magnetic resonance imaging). (b) Preoperative MRI. MRI shows a hyperintense heterogeneous lesion within the femoral head (arrows) with violation of the subchondral plate and associated femoral head fracture.

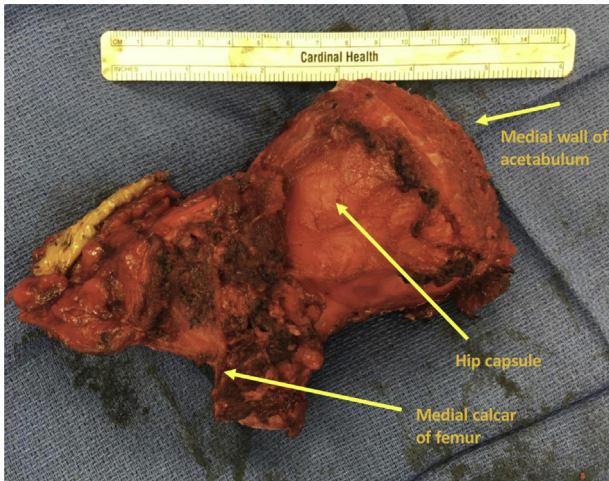


Figure 3. Intraoperative en bloc resection.

rotators of the hip. Once properly identified, the piriformis and external rotators were released off the posterior femur carefully to preserve all capsules and remain extra-articular. Further exposure of the capsule was performed by mobilizing the gluteus minimus and medius superiorly and anteriorly, as well as the abductor attachments extra-articularly along the greater trochanter. An extra-articular greater trochanteric osteotomy was performed to further mobilize the abductors off the anterior capsule and to preserve part of their insertion. Once the capsule was fully identified in a 360° manner, the proximal femur was osteotomized inferior to the hip capsule. The osteotomy was planned distal to the previous biopsy, extending into the lesser trochanter leaving part of the lesser trochanter and inferior medial calcar. At completion of the proximal femoral osteotomy, the proximal femoral segment included the intra-articular portion of the greater trochanter, femoral neck, femoral head, and complete preservation of the hip capsule.

Once the proximal femoral segment was adequately mobilized, acetabular resection was performed. Exposure included circumferential extra-articular exposure of the outer ilium, posterior column, superior pubic ramus, inner ilium, and quadrilateral plate. Intraoperative fluoroscopy was used to guide the periacetabular cuts. Resection began with the supraacetabular cuts above the superior capsule. With a series of angled osteotomies, oscillating saws, and burrs, the osteotomy was extended around the

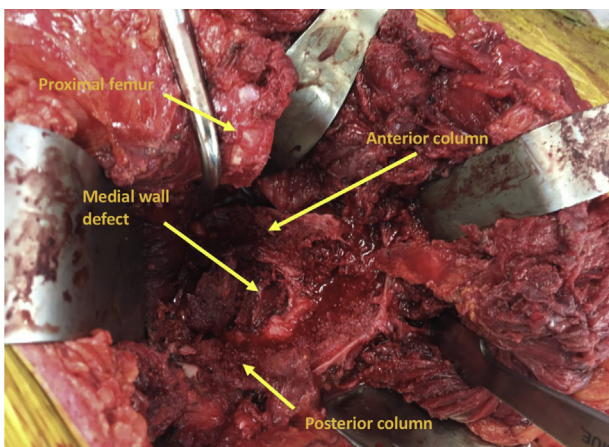


Figure 4. Intraoperative image.

acetabulum down the posterior column and into the ischium posteriorly, preserving the posterior column. Anteriorly, the resection was carried out through the superior pubic ramus and the continuity of the superomedial anterior column was maintained. Once all of the cuts were complete, the specimen was removed en bloc. The full specimen (Fig. 3) remained extra-articular, and included the medial wall of the pelvis, but with preservation of the anterior column, posterior column, and supracetabular region of the pelvis (Fig. 4), as well as the inferomedial calcar of the femur. The hip capsule remained intact, without violation of the joint.

After the extra-articular en bloc resection of the acetabulum and proximal femur, acetabular reconstruction was performed using a highly porous tantalum acetabular shell (TM Modular Multi-Hole Cup; Zimmer, Inc Warsaw, Indiana) fixed with screws and augmented with morselized allograft medially and superiorly (Fig. 5). The femoral reconstruction was performed using a modular tapered stem (Restoration Modular, Stryker Kalamazoo, MI). Abductor reattachment was performed with Ethibond (Ethicon, Somerville, NJ) in a 4-strand Krackow stitch configuration using the greater trochanteric osteotomy attachment to the modular stem.

Final pathology showed clear-cell chondrosarcoma with negative bone and soft tissue margins (Fig. 6).

At 2-year follow-up, the patient remains active, bowls, golfs, and does elliptical. The postoperative mHHS at 2-year follow-up is 93.5 (slight pain, no limp, no support, unlimited walking, normally up and down stairs, difficulty shoes and socks, any chair 1 hour, able to use public transportation). His University of California Los Angeles activity score is 8 (regularly participate in very active events). He rated his postop satisfaction as being extremely satisfied and would have the surgery again. He has no evidence of local tumor

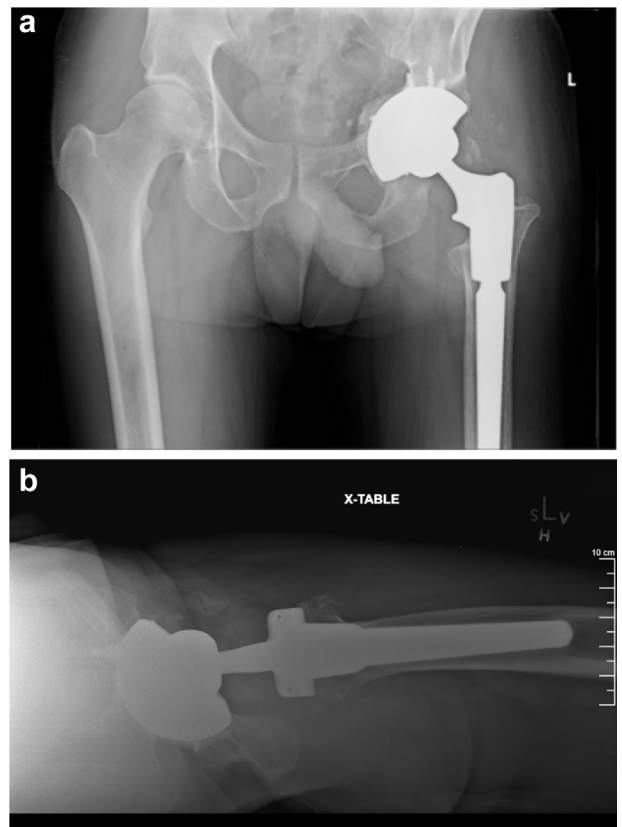


Figure 5. Postoperative AP (a) and direct lateral (b) radiographs demonstrate a well-fixed, well-positioned acetabular shell and modular femoral stem.

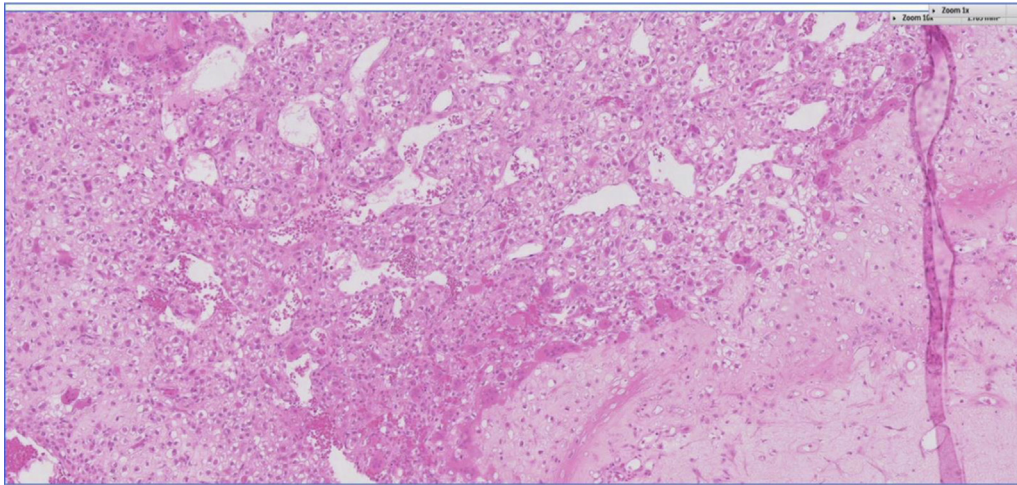


Figure 6. Final pathology confirms clear-cell chondrosarcoma.

recurrence or metastatic disease. Serial radiographs revealed no migration and no subsidence. The 2-year radiographs showed a well-fixed acetabular shell without radiographic signs of loosening and a well-fixed modular femoral stem.

Discussion

Previous extra-articular techniques for intra-articular tumors of the hip have resected the anterior and posterior columns of the pelvis, and a few have utilized techniques allowing for preservation of the posterior column but not the anterior column [1,3,18]. These techniques have required reconstructions with that of a structural allograft, cage, saddle prostheses, and various stemmed iliac prostheses [3,4,7–9,18]. Although intra-articular malignant tumors of the hip are rare, these techniques have decreased survivorship and modest functional outcomes at short-term and midterm follow-up [4,6,9–11].

We report a technique that allows preservation of both the columns of the pelvis while enabling proper oncologic resection for intra-articular tumors of the hip. With the preservation of the anterior and posterior pelvic columns, reconstruction with a multihole porous shell is possible without the need for a specialized prosthesis or structural allograft.

Rüdiger et al. [3] presented 2 cases, for whom an extra-articular resection of the hip was performed for an intra-articular tumor. Using the principles of the Bernese PAO, they maintained continuity of the posterior column while resecting the anterior column. Reconstruction was performed with the use of an acetabular allograft with plate and screw fixation to regain anterior column stability. After this, a cemented acetabular component was placed into the acetabular allograft. Barro et al. [18] also present a case of an intra-articular hip tumor resection. Extra-articular resection was performed for an osteosarcoma of the proximal femur. An en bloc resection of the acetabulum and proximal femur were performed, resecting the anterior column. The proximal femur was then removed from the acetabular fragment. The acetabular fragment then underwent radiation treatment and was re-implanted and fixed with plates and screws. Proximal femoral reconstruction was performed with a proximal femoral hemiarthroplasty compress. We describe a resection and reconstructive technique for an intra-articular malignancy of the hip while preserving the anterior and posterior columns and reconstruction with cementless acetabular fixation without the need for structural allograft or complex acetabular/pelvic reconstruction. To our knowledge, this has not

been reported and at 2-year follow-up, our patient walks with no discomfort, remains active, walks without the assistance of any structural aids, and does not limp. He reports an mHHS of 93.5, and radiographs showed no signs of loosening. His staging scans showed no signs of recurrent or metastatic disease.

Summary

In summary, the purpose of this report was to describe a technique for en bloc extra-articular resection of the hip while maintaining the anterior and posterior pelvic columns, thus allowing reconstruction without the use of a structural allograft, cage, or stemmed iliac prosthesis. This technique allowed for proper oncologic resection and provided our patient with complete pelvic stability that allowed reconstruction with a porous acetabular shell fixed with screws and thus providing a long-term reconstructive option and allowing increased activity, excellent function, and a good quality of life.

Acknowledgments

Partial support was received from the Curing Hip Disease Fund (JCC) for research personnel support.

References

- [1] Enneking WF, Dunham WK. Resection and reconstruction for primary neoplasms involving the innominate bone. *J Bone Joint Surg Am* 1978;60(6):731.
- [2] Piriou P, Sagnet F, Norton MR, Garreau de Loubresse C, Judet T. Acetabular component revision with frozen massive structural pelvic allograft. *J Arthroplasty* 2003;18(5):562.
- [3] Rüdiger HA, Dora C, Bode-Lesniewska B, Exner GU. Extra-articular resection of the hip with a posterior column-preserving technique for treatment of an intra-articular malignant lesion. A report of two cases. *J Bone Joint Surg Am* 2005;87(12):2768.
- [4] Wu S, Shi X, Zhou G, Lu M, Li C. Composite reconstruction of the hip following resection of periacetabular tumors: middle-term outcome. *J Arthroplasty* 2013;28(3):537.
- [5] Oragui E, Nannaparaju M, Sri-Ram K, Khan W, Hashemi-Nejad A, Skinner J. Case report – open access. *Int J Surg Case Rep* 2013;4(1):101.
- [6] Abolghasemian M, Sadeghi Naini M, Tangsataporn S, et al. Reconstruction of massive uncontained acetabular defects using allograft with cage or ring reinforcement: an assessment of the graft's ability to restore bone stock and its impact on the outcome of re-revision. *Bone Joint J* 2014;96-B(3):319.
- [7] Fisher NE, Patton JT, Grimer RJ, et al. Ice-cream cone reconstruction of the pelvis: a new type of pelvic replacement: early results. *J Bone Joint Surg Br* 2011;93(5):684.
- [8] Bell RS, Davis AM, Wunder JS, Buconjic T, McGovern B, Gross AE. Allograft reconstruction of the acetabulum after resection of stage-IIB sarcoma. Intermediate-term results. *J Bone Joint Surg Am* 1997;79(11):1663.

- [9] Ueda T, Kakunaga S, Takenaka S, Araki N, Yoshikawa H. Constrained total hip megaprosthesis for primary periacetabular tumors. *Clin Orthop Relat Res* 2012;471(3):741.
- [10] Jansen JA, van de Sande MAJ, Dijkstra PDS. Poor long-term clinical results of saddle prosthesis after resection of periacetabular tumors. *Clin Orthop Relat Res* 2012;471(1):324.
- [11] Barrientos-Ruiz I, Ortiz-Cruz EJ, Peleteiro-Pensado M. Reconstruction after hemipelvectomy with the ice-cream cone prosthesis: what are the short-term clinical results? *Clin Orthop Relat Res* 2017;475(3):735.
- [12] Trumm BN, Callaghan JJ, Liu SS, Goetz DD, Johnston RC. Revision with cementless acetabular components: a concise follow-up, at a minimum of twenty years, of previous reports. *J Bone Joint Surg* 2012;94(21):2001.
- [13] Delanois RE, Gwam CU, Mohamed N, et al. Midterm outcomes of revision total hip arthroplasty with the use of a multihole highly-porous titanium shell. *J Arthroplasty* 2017;32(9):2806.
- [14] Ganz R, Klaue K, Vinh TS, Mast JW. A new periacetabular osteotomy for the treatment of hip dysplasias. Technique and preliminary results. *Clin Orthop Relat Res* 1988;(232):26.
- [15] Wells J, Schoenecker P, Duncan S, Goss CW, Thomason K, Clohisy JC. Intermediate-term hip survivorship and patient-reported outcomes of periacetabular osteotomy: the Washington University Experience. *J Bone Joint Surg* 2018;100(3):218.
- [16] Cutrera NJ, Pinkas D, Toro JB. Surgical approaches to the acetabulum and modifications in technique. *J Am Acad Orthop Surg* 2015;23(10):592.
- [17] Mehlman CT, Meiss L, DiPasquale TG. Hyphenated-history: the Kocher-Langenbeck surgical approach. *J Orthop Trauma* 2000;14(1):60.
- [18] Barro V, Velez R, Pacha D, Giral J, Roca I, Aguirre M. Bernese periacetabular osteotomy in a hip extra-articular resection followed by reconstruction using an extracorporeal irradiated acetabulum autograft with megaprosthesis, for proximal femur osteosarcoma in a pediatric patient. *Case Rep Med* 2015;2015(358):1.