

Washington University School of Medicine Digital Commons@Becker

Open Access Publications

2018

Adult-onset papular purpuric gloves and socks syndrome

Monica Rosales Santillan

University of Texas McGovern Medical School - Houston

Jessica B. Dietert

Washington University School of Medicine in St. Louis

Richard Jahan-Tigh

University of Texas McGovern Medical School- Houston

Follow this and additional works at: https://digitalcommons.wustl.edu/open_access_pubs

Recommended Citation

Santillan, Monica Rosales; Dietert, Jessica B.; and Jahan-Tigh, Richard, "Adult-onset papular purpuric gloves and socks syndrome." *Dermatology Online Journal*.24,4. . (2018).
https://digitalcommons.wustl.edu/open_access_pubs/6964

This Open Access Publication is brought to you for free and open access by Digital Commons@Becker. It has been accepted for inclusion in Open Access Publications by an authorized administrator of Digital Commons@Becker. For more information, please contact engeszer@wustl.edu.

UC Davis

Dermatology Online Journal

Title

Adult-onset papular purpuric gloves and socks syndrome

Permalink

<https://escholarship.org/uc/item/02x2h6sd>

Journal

Dermatology Online Journal, 24(4)

Authors

Rosales Santillan, Monica
Dietert, Jessica B
Jahan-Tigh, Richard

Publication Date

2018-01-01

License

[CC BY-NC-ND 4.0](#)

Peer reviewed

Adult-onset papular purpuric gloves and socks syndrome

Monica Rosales Santillan¹ BS, Jessica B Dietert² MD, Richard Jahan-Tigh³ MD

Affiliations: ¹The University of Texas McGovern Medical School at Houston, Houston, Texas, USA, ²Dermatology, Department of Medicine, Center for Dermatologic and Cosmetic Surgery, Micrographic Surgery and Dermatologic Oncology Fellowship, Washington University School of Medicine, St. Louis, Missouri, USA, ³Department of Dermatology, The University of Texas McGovern Medical School at Houston, Houston, Texas, USA

Corresponding Author: Monica Rosales Santillan BS, The University of Texas McGovern Medical School at Houston, 6431 Fannin Street, Suite G400, Houston, TX 77030, Email: monica.rosalessantillan@uth.tmc.edu

Abstract

Papular purpuric gloves and socks syndrome (PPGSS) is a self-limited exanthem that presents as painful or pruritic edema, erythema, petechiae, and purpura of the palms and soles with occasional extension to the dorsal hands and feet. The majority of PPGSS cases reported in the literature are associated with parvovirus B19 and occur in children and young adults. In a recent literature search, there were 11 PPGSS cases in adults with none reporting Epstein-Barr virus (EBV) as a viral etiology. However, there have been PPGSS cases related to EBV in children. We report the case of a 72-year-old man with PPGSS associated with Epstein-Barr virus. This case report serves as a reminder that PPGSS can present not only in the setting of pediatric and young adult parvovirus B19 infection, but also in immunocompetent adults with other viral infections.

Keywords: gloves and socks syndrome; EBV; PPGSS; viral exanthem; adult-onset

Introduction

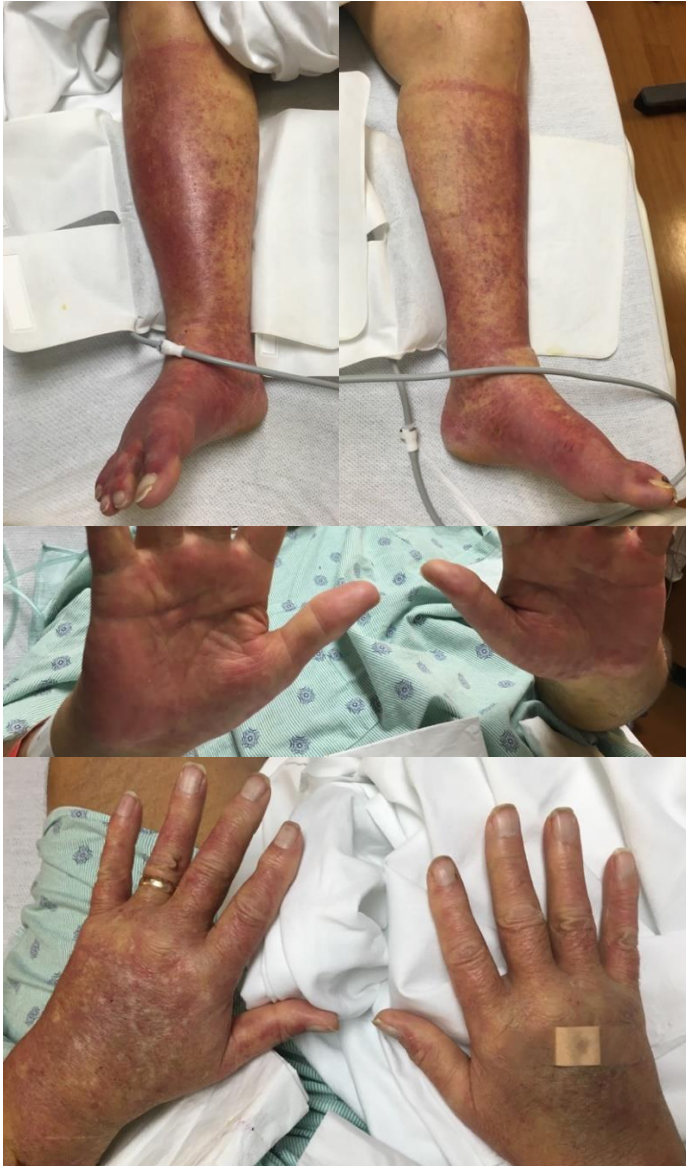Papular purpuric gloves and socks syndrome (PPGSS) is an exanthem that was first described by Harms et al. in 1990 [1]. It presents as transient painful or pruritic edema, erythema, petechiae and purpura in a gloves and socks distribution. It is associated with viral infections and resolves without treatment in 1 to 2 weeks. There have been many

reported cases of Parvovirus B19-associated PPGSS, both in children and young adults. Less commonly, PPGSS can occur in the setting of various other viral infections. Herein, we report the case of a 72-year-old man with PPGSS associated with EBV infection. This case is unusual in that the eruption occurred secondary to EBV infection in an older adult.

Case Synopsis

A 72-year-old man hospitalized for fever, malaise, elevated liver function tests, and upper respiratory infection symptoms presented with painful, progressive, purpuric papules and plaques involving the palms and soles. Three days prior to hospital admission, he tested positive for mononucleosis and influenza B at his primary care visit. The patient had recently received vancomycin, ceftriaxone, azithromycin, atorvastatin, ibuprofen, and pantoprazole.

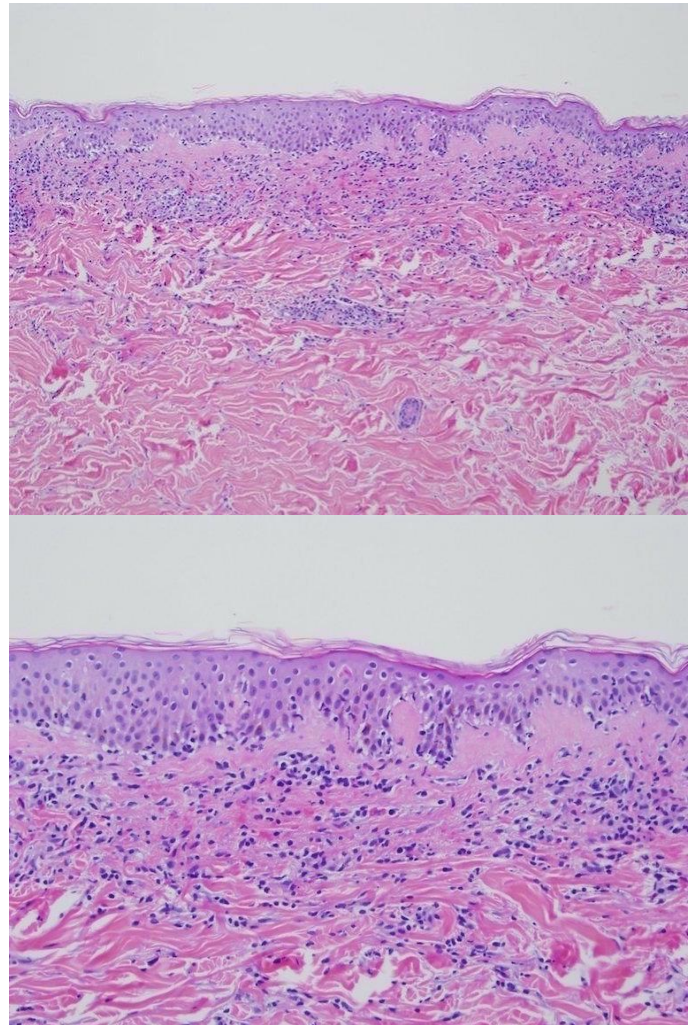
Physical examination revealed erythematous, purpuric papules and plaques involving the palms, plantar feet, and the anterior feet and ankles to a lesser extent (**Figure 1**). The patient also had palatal petechiae without oral erosions. Pertinent laboratory studies included an AST of 173 IU/L, ALT of 208 IU/L, and alkaline phosphatase of 386 IU/L. His WBC count was $11.3 \times 10^9/L$, hemoglobin of 14.6 g/dL, and platelet count of $130 \times 10^9/L$. A repeat monospot was positive but cytomegalovirus (CMV) serologies were negative for both IgM and IgG as was CMV PCR. EBV VCA IgM was positive at 4.0 (normal <0.8) while EBV VCA IgG and EBVNA IgG were both negative. EBV



Figures 1. Erythematous, purpuric papules and plaques involving the hands and feet with extension proximal to the ankles.

quantitative PCR values increased from 703,868 copies/mL to more than 1,000,000 copies/mL. The patient's prior influenza B diagnosis was not tested again since the patient's clinical presentation and lab results supported an EBV viremia diagnosis. ANA titer was 1:40 and anti-smooth muscle antibody titer was 1:20.

Punch biopsy was performed of the left plantar foot and revealed vacuolar alteration of the dermal-epidermal junction with scattered necrotic keratinocytes, mild papillary dermal edema, and perivascular lymphohistiocytic infiltrate with extravasated erythrocytes (**Figure 2**). The patient



Figures 2. **A)** Superficial dermal infiltrate with focal interface changes. H&E, 10x. **B)** Vacuolar alteration of the dermal-epidermal junction with mild papillary edema, scattered necrotic keratinocytes, and perivascular lymphohistiocytic infiltrate with extravasated erythrocytes. H&E, 20x.

was given a diagnosis of adult-onset papular purpuric gloves and socks syndrome secondary to acute EBV infection. The patient's purpuric papules and plaques progressed to involve the palms and plantar feet more confluenty. His symptoms improved with topical triamcinolone and resolved completely with resolution of his underlying EBV viremia within two weeks.

Case Discussion

Papular purpuric gloves and socks syndrome (PPGSS) was first reported by Harms et al. in 1990 [1]. In 1991, Bagot and Revuz reported the association between PPGSS and parvovirus B19 in one patient [2]. Since that time, the majority of PPGSS cases

reported in the literature have been associated with parvovirus B19 [3]. In the PPGSS histopathologic study by Smith et al. [3], a PPGSS search of the literature was conducted, which showed 46 reported cases of PPGSS. Of the 34 PPGSS cases with known viral etiologies, parvovirus B19 was responsible for around 80% [3]. There have been fewer reported cases of PPGSS and its association with viral etiologies other than parvovirus B19 described in the literature [4-7]. Additionally, PPGSS is less common in adults (**Table 1**).

In a literature search, there were 11 PPGSS cases reported in adults. Parvovirus B19 was reported in about 73% of the 11 cases (**Table 1**). The other

reported viral etiologies for adult-onset PPGSS were rubella virus, human herpesvirus 6 (HHV-6), and coxsackievirus A4 (**Table 1**). The majority of the patients presented with other skin findings and oral lesions (**Table 1**). Although EBV was not a viral etiology in these cases, there have been PPGSS cases associated with EBV in the pediatric population [17]. In a childhood-onset PPGSS study by Hsieh et al. [17], 28% of the PPGSS cases were associated with EBV.

Patients with PPGSS associated with other viral etiologies have a similar clinical presentation and course to PPGSS associated with parvovirus B19 [2, 4, 5, 18]. Perez-Ferriols et al. described PPGSS in a patient with measles virus infection [4]. The patient

Table 1. A summary of the published cases of adult-onset papular purpuric gloves and socks syndrome (PPGSS).

Case	Patient Age (yrs.)/Sex	PPGSS Reported Cause	PPGSS Duration (Weeks)	Other skin findings	Oral lesions	Author, Year, Reference
1	35/Female	Parvovirus B19	NR	None	Oropharyngeal aphthous lesions	Ozaydin, 2016, [8]
2	42 /Female	Parvovirus B19	2	None	Oral mucosal erythema with central necrosis	Gutermuth, 2011, [9]
3	48 /Female	Parvovirus B19	2	Multiple petechiae on buttocks, purpuric eruption in bathing trunk distribution	Lip erosions, lingual aphthae	Vázquez-Osorio, 2017, [10]
4	42/Female	Parvovirus B19	2	Purpuric papules on thighs and buttocks	Lingual and labial mucosal aphthae	Frühauf, 2009, [11]
5	42/Male	Parvovirus B19	2	Purpuric papules on trunk	Multiple petechiae on hard and soft palate	Loukeris, 2005, [12]
6	54/Male	Parvovirus B19	NR	Papules on trunk and extremities, purpuric lesions on groin, few petechiae on inner thighs	Multiple grouped vesicles on upper lip, hard palate petechiae, labial mucosal erosions	Passoni, 2001, [13]
7	42/Male	Parvovirus B19	1	Purpuric-petechial lesions on armpits, elbows, and groin; erythema of forehead, cheeks, and nose	Palatal petechiae	Sklavounou-Andrikopoulou, 2004, [14]
8	43/Male	Rubella virus	NR	None	None	Seguí, 2000, [6]
9	36/Female	Parvovirus B19	2	Petechiae on buttocks, proximal arms and legs; erythema of cheeks	Stomatitis	Alfadley, 2003, [15]
10	35/Male	Human herpesvirus 6	2	None	Oral mucosal petechiae and erosions	Ruzicka, 1998, [5]
11	40/Male	Coxsackievirus A4	2	None	None	Ohshita, 2015, [16]

NR, Not Reported

presented with erythematous purpuric lesions localized to her hands and feet with systemic signs of fever and malaise [4]. The patient's purpuric lesions disappeared gradually with desquamation [4]. Serologic testing was positive for measles virus at the time of admission [4]. Another PPGSS case reported in the literature was associated with HHV-6 infection [5]. Ruzicka et al. also noted similar findings on physical exam with erythematous papules and petechiae restricted to the hands and feet in a gloves-and-socks distribution [5]. The patient tested positive for a recent infection of HHV-6 on serologic testing with resolution of the lesions in two weeks [5].

We present a patient with adult-onset PPGSS associated with Epstein-Barr virus, which further supports the association of PPGSS with viral etiologies other than parvovirus B19. Our patient had a prodrome of fever and malaise prior to the onset of PPGSS, which supported a viral etiology [18]. The patient had been diagnosed with EBV viremia and other complications prior to seeing him as a consult; therefore, we did not obtain titers for parvovirus B19. The repeat positive monospot and positive EBV VCA IgM at 4.0 (normal <0.8) supported the diagnosis of EBV viremia. Although the patient's EBV VCA IgG and EBVNA IgG were negative, the patient's EBV quantitative PCR values increased from 703,868 copies/mL to more than 1,000,000 copies/mL. The patient's prior influenza B diagnosis was not tested again since an EBV viremia diagnosis correlated well with the patient's symptoms and lab results. We were unable to determine what test was used for influenza B at the patient's primary care visit. On physical exam, the patient had lesions classic for PPGSS in the setting of a new onset EBV viremia.

References

1. Harms M, Feldmann R, Saurat JH. Papular-purpuric "gloves and socks" syndrome. *J Am Acad Dermatol*. 1990;23(5):850-4. [PMID: 2147699].
2. Bagot M, Revuz J. Papular-purpuric "gloves and socks" syndrome: primary infection with parvovirus B19? *J Am Acad Dermatol*. 1991;25(2):341-2. [PMID: 1655835].
3. Smith SB, Libow LF, Elston DM, Bernert RA, Warschaw KE. Gloves and socks syndrome: Early and late histopathologic features. *J Am Acad Dermatol*. 2002;47(5):749-54. [PMID: 12399769].
4. Perez-Ferriols A, Martinez-Aparicio A, Aliaga-Boniche A. Papular-purpuric "gloves and socks" syndrome caused by measles virus. *J Am Acad Dermatol*. 1994;30(2):291-2. [PMID: 8288801].
5. Ruzicka T, Kalka K, Diercks K, Schuppe HC. Papular-purpuric 'gloves-and-socks' syndrome associated with human herpesvirus-6 infection. *Arch Dermatol*. 1998;134(2):242-4. [PMID: 9487223].
6. Segui N, Zayas A, Fuentes A, Marquina A. Papular-purpuric 'gloves-and-socks' syndrome related to rubella virus infection [letter]. *Dermatology*. 2000;200(1):89. [PMID: 10681632].

Although the diagnosis of PPGSS is made by the clinical presentation and viral serology, as in our patient, the histopathology may support the diagnosis [3]. Smith et al. examined the histopathologic characteristics of 18 out of the 47 PPGSS cases found in the literature [3]. Superficial perivascular lymphocytic infiltrates were seen in the early lesions that are nonspecific and common in viral exanthems. The 18 PPGSS cases had characteristic late pathologic findings, with 6 having vacuolar interface change and 11 demonstrating dermal hemorrhage. The authors concluded that fully evolved lesions of PPGSS show findings of vacuolar interface dermatitis, dermal hemorrhage, and dyskeratotic keratinocytes. These findings may support a PPGSS diagnosis [3].

The PPGSS cases reported in the literature resolved on their own and did not require any form of treatment. Retrospectively, our patient's exanthem most likely would have resolved even without topical triamcinolone [19]. Ilknur et al. presented a case of PPGSS in a patient whose exanthem resolved after treatment was discontinued [19].

Conclusion

In summary, we report a patient with adult-onset papular purpuric gloves-and-socks syndrome related to Epstein-Barr virus infection. Although most PPGSS cases reported in the literature are associated with parvovirus B19, this case report provides an overview of how PPGSS may present in the setting of other viral infections. This case also serves as a reminder to consider a diagnosis of PPGSS in older adults when the clinical presentation is appropriate.

7. Drago F, Parodi A, Rebora A. Gloves-and-socks syndrome in a patient with Epstein-Barr virus infection [letter]. *Dermatology*. 1997;194(4):374. [PMID: 9252766].
8. Ozaydin V, Eceviz A, Sari Dogan F, Dogan A. An Adult Patient who Presented to Emergency Service with a Papular Purpuric Gloves and Socks Syndrome: A Case Report. *Turk J Emerg Med*. 2016;14(4):179-81. [PMID: 27437515].
9. Gutermuth J, Nadas K, Zirbs M, Seifert F, Hein R, Ring J, Brockow K. Papular-purpuric gloves and socks syndrome. *Lancet*. 2011;378(9786):198. [PMID: 21742170].
10. Vázquez-Osorio I, Mallo-García S, Rodríguez-Díaz E, Gonzalvo-Rodríguez P, Requena L. Parvovirus B19 infection presenting concurrently as papular-purpuric gloves-and-socks syndrome and bathing-trunk eruption. *Clin Exp Dermatol*. 2017;42(1):58-60. [PMID: 27900796].
11. Frühauf J, Massone C, Müllegger RR. Bullous papular-purpuric gloves and socks syndrome in a 42-year-old female: molecular detection of parvovirus B19 DNA in lesional skin. *J Am Acad Dermatol*. 2009;60(4):691-5. [PMID: 19293017].
12. Loukeris D, Serelis J, Aroni K, Tsakris A, Voulgarelis M. Simultaneous occurrence of pure red cell aplasia and papular-purpuric 'gloves and socks' syndrome in parvovirus B-19 infection. *J Eur Acad Dermatol Venereol*. 2005;19(3):373-6. [PMID:15857471].
13. Passoni LF, Ribeiro SR, Giordani ML, Menezes JA, Nascimento JP. Papular-purpuric "gloves and socks" syndrome due to parvovirus B19: report of a case with unusual features. *Rev Inst Med Trop Sao Paulo*. 2001;43(3):167-70. [PMID: 11452327].
14. Sklavounou-Andrikopoulou A, Iakovou M, Paikos S, Papanikolaou V, Loukeris D, Voulgarelis M. Oral manifestations of papular-purpuric 'gloves and socks' syndrome due to parvovirus B19 infection: the first case presented in Greece and review of the literature. *Oral Dis*. 2004;10(2):118-22. [PMID: 14996283].
15. Alfadley A, Aljubran A, Hainau B, Alhokail A. Papular-purpuric "gloves and socks" syndrome in a mother and daughter. *J Am Acad Dermatol*. 2003;48(6):941-4. [PMID: 12789189].
16. Ohshita A, Nakai N, Katoh N, Konishi K. A Case of Gloves and Socks Syndrome and Related Eruptions Caused by Coxsackievirus A4 Infection Mimicking Adult-onset Still's Disease. *Indian J Dermatol*. 2015;60(3):324. [PMID: 26120191].
17. Hsieh MY, Huang PH. The juvenile variant of papular-purpuric gloves and socks syndrome and its association with viral infections. *Br J Dermatol*. 2004;151(1):201-6. [PMID: 15270892].
18. Drago F, Paolino S, Rebora A, Broccolo F, Drago F, Cardo P, Parodi A. The challenge of diagnosing atypical exanthems: a clinico-laboratory study. *J Am Acad Dermatol*. 2012;67(6):1282-8. [PMID: 22627037].
19. Ilknur T, Fetil E, Akarsu S, Gunes AT. A case of papular-purpuric gloves-and-socks syndrome receiving unnecessary treatment. *Clin Exp Dermatol*. 2011;36(1):110-1. [PMID: 21143518].