

Washington University School of Medicine Digital Commons@Becker

Open Access Publications

2018

Residual mitral regurgitation after repair for posterior leaflet prolapse- Importance of preoperative anterior leaflet tethering

Taichi Sakaguchi

The Sakakibara Heart Institute of Okayama

Nobuyuki Kagiya

Washington University School of Medicine in St. Louis

Misako Toki

The Sakakibara Heart Institute of Okayama

Arudo Hiraoka

The Sakakibara Heart Institute of Okayama

Akihiro Hayashida

The Sakakibara Heart Institute of Okayama

See next page for additional authors

Follow this and additional works at: https://digitalcommons.wustl.edu/open_access_pubs

Recommended Citation

Sakaguchi, Taichi; Kagiya, Nobuyuki; Toki, Misako; Hiraoka, Arudo; Hayashida, Akihiro; Totsugawa, Toshinori; Tamura, Kentaro; Chikazawa, Genta; Yoshitaka, Hidenori; and Yoshida, Kiyoshi, "Residual mitral regurgitation after repair for posterior leaflet prolapse-Importance of preoperative anterior leaflet tethering." *Journal of the American Heart Association*.7, e008495. (2018).
https://digitalcommons.wustl.edu/open_access_pubs/6941

This Open Access Publication is brought to you for free and open access by Digital Commons@Becker. It has been accepted for inclusion in Open Access Publications by an authorized administrator of Digital Commons@Becker. For more information, please contact engeszer@wustl.edu.

Authors

Taichi Sakaguchi, Nobuyuki Kagiya, Misako Toki, Arudo Hiraoka, Akihiro Hayashida, Toshinori Totsugawa, Kentaro Tamura, Genta Chikazawa, Hidenori Yoshitaka, and Kiyoshi Yoshida

Residual Mitral Regurgitation After Repair for Posterior Leaflet Prolapse—Importance of Preoperative Anterior Leaflet Tethering

Taichi Sakaguchi, MD; Nobuyuki Kagiya, MD; Misako Toki, BSc; Arudo Hiraoka, MD; Akihiro Hayashida, MD; Toshinori Totsugawa, MD; Kentaro Tamura, MD; Genta Chikazawa, MD; Hidenori Yoshitaka, MD; Kiyoshi Yoshida, MD

Background—Carpentier's techniques for degenerative posterior mitral leaflet prolapse have been established with excellent long-term results reported. However, residual mitral regurgitation (MR) occasionally occurs even after a straightforward repair, though the involved mechanisms are not fully understood. We sought to identify specific preoperative echocardiographic findings associated with residual MR after a posterior mitral leaflet repair.

Methods and Results—We retrospectively studied 117 consecutive patients who underwent a primary mitral valve repair for isolated posterior mitral leaflet prolapse including a preoperative 3-dimensional transesophageal echocardiography examination. Twelve had residual MR after the initial repair, of whom 7 required a corrective second pump run, 4 underwent conversion to mitral valve replacement, and 1 developed moderate MR within 1 month. Their preoperative parameters were compared with those of 105 patients who had an uneventful mitral valve repair. There were no hospital deaths. Multivariate analysis identified preoperative anterior mitral leaflet tethering angle as a significant predictor for residual MR (odds ratio, 6.82; 95% confidence interval, 1.8–33.8; $P=0.0049$). Receiver operator characteristics curve analysis revealed a cut-off value of 24.3° (area under the curve, 0.77), indicating that anterior mitral leaflet angle predicts residual MR. In multivariate regression analysis, smaller anteroposterior mitral annular diameter ($P<0.001$) and lower left ventricular ejection fraction ($P=0.002$) were significantly associated with higher anterior mitral leaflet angle, whereas left ventricular and left atrial dimension had no significant correlation.

Conclusions—Anterior mitral leaflet tethering in cases of posterior mitral leaflet prolapse has an adverse impact on early results following mitral valve repair. The findings of preoperative 3-dimensional transesophageal echocardiography are important for consideration of a careful surgical strategy. (*J Am Heart Assoc.* 2018;7:e008495. DOI: 10.1161/JAHA.117.008495.)

Key Words: echocardiography • leaflet tethering • mitral regurgitation • posterior leaflet prolapse • three-dimensional • valvuloplasty

Repair techniques for posterior mitral leaflet (PML) prolapse have been established with excellent long-term results reported.^{1,2} However, in some cases, unexpected residual mitral regurgitation (MR) is encountered even after a

seemingly straightforward PML repair. Given that residual MR greater than trivial is a risk factor for MR recurrence associated with late adverse left ventricular (LV) remodeling and increased mortality, near-complete elimination of MR during the initial repair is crucial.^{3–5}

To achieve a durable repair, it is important to create a large area for leaflet coaptation, with a coaptation length of 5 to 8 mm considered essential.^{6–9} Inadequate leaflet coaptation leads to residual MR, which can be caused by various factors, such as persistent prolapse, leaflet retraction, widened interscallop indentation, and residual annular dilatation.

In patients with functional MR, leaflet tethering is known to be an important predictor of recurrent MR after a mitral annuloplasty.^{10,11} A recent study also showed that even in patients with degenerative MR, a nonprolapsing leaflet can be tethered and exacerbate leaflet malcoaptation, thus creating a vicious MR cycle.¹² We speculated that those patients may also be at high risk for residual MR after undergoing a standard repair procedure. The present study was conducted to investigate the association of preoperative anterior mitral

From the Departments of Cardiovascular Surgery (T.S., A. Hiraoka, T.T., K.T., G.C., H.Y.), Clinical Laboratory (M.T.), and Cardiology (A. Hayashida, K.Y.), The Sakakibara Heart Institute of Okayama, Japan; Division of Cardiology, Washington University, St. Louis, MO (N.K.).

Accompanying Videos S1 through S4 are available at <http://jaha.ahajournals.org/content/7/11/e008495.full#sec-22>

The results of this study were presented at the Scientific Sessions of the American Heart Association, November 11 to 15, 2017, in Anaheim, CA.

Correspondence to: Taichi Sakaguchi, MD, Department of Cardiovascular Surgery, The Sakakibara Heart Institute of Okayama, 2-5-1 Nakai-cho, Kita-ku, Okayama City, Okayama 700-0804, Japan. E-mail: ts472@tuba.ocn.ne.jp

Received December 28, 2017; accepted May 3, 2018.

© 2018 The Authors. Published on behalf of the American Heart Association, Inc., by Wiley. This is an open access article under the terms of the Creative Commons Attribution-NonCommercial License, which permits use, distribution and reproduction in any medium, provided the original work is properly cited and is not used for commercial purposes.

Clinical Perspective

What Is New?

- This study was the first to investigate the association between specific preoperative echocardiographic findings related to mitral valve morphology and residual mitral regurgitation in patients who underwent a repair procedure for posterior leaflet prolapse.
- Our findings showed that anterior leaflet tethering angle is a significant predictor for residual mitral regurgitation.

What Are the Clinical Implications?

- Even for cases of simple posterior leaflet prolapse, careful consideration of optimum repair strategy is essential when treating patients with coexisting anterior leaflet tethering.

leaflet (AML) tethering and early outcome following repair for PML prolapse.

Methods

Data and methods will not be made available to other researchers for the purpose of reproducing the results or replicating the procedure.

Study Population

Between December 2012 and February 2017, 148 patients with severe MR attributed to isolated PML prolapse underwent a primary mitral valve (MV) repair at the Sakakibara Heart Institute of Okayama. Of those, 117 who received a preoperative valve evaluation using 3-dimensional transesophageal echocardiography (3D-TEE) were included in the present study. Patients who underwent concomitant operations for aortic valve disease, hypertrophic cardiomyopathy, or an ascending aortic aneurysm were excluded. Among those 117 patients, 12 had suboptimal results after the initial repair, of whom 7 required a corrective second pump run, 4 underwent conversion to MV replacement, and 1 developed moderate MR within 1 month. They were classified as the residual MR group, and their preoperative parameters were compared with those of 105 patients who had an uneventful MV repair (control group). Our Institutional Review Board approved the data analysis methods used for this retrospective study and waived the need for patient consent.

Echocardiography

All patients underwent preoperative transthoracic echocardiography and TEE examinations at our echocardiography department. MR grade was evaluated by measuring the color

Doppler jet area or by use of the Doppler-derived volumetric method or proximal isovelocity surface area method, according to previously published guidelines.^{13,14} Mild regurgitation was defined as effective regurgitant orifice area $<0.2 \text{ cm}^2$ and/or vena contracta width $<0.3 \text{ cm}$, moderate regurgitation as effective regurgitant orifice area $\geq 0.2 \text{ cm}^2$ and $<0.4 \text{ cm}^2$ and/or vena contracta width $\geq 0.3 \text{ cm}$ and $<0.7 \text{ cm}$, and severe regurgitation as effective regurgitant orifice area $\geq 0.4 \text{ cm}^2$ and/or vena contracta width $\geq 0.7 \text{ cm}$. For intraoperative TEE assessment of residual MR, maximum regurgitant jet area (MRA) was used because quantification of residual MR, which is mostly less than mild, is difficult with the proximal isovelocity surface area method. In addition, 3D-TEE analysis was performed off-line using the commercially available semiautomated software package, MVN (Philips Medical Systems, Best, The Netherlands), whose accuracy and reproducibility of 3D quantification have been reported.¹⁵ Briefly, the diameters of the mitral annulus were measured between A2 and P2 (anteroposterior annular diameter) and between the anterolateral commissure and posteromedial commissure (commissure-to-commissure annular diameter). Length and area of the AML (AML length, AML area) were also measured. AML/PML angles were defined as the angles between the annular line and the line that joins the anterior/posterior annulus and coaptation point. Tenting height was determined based on the distance between the point of leaflet coaptation and mitral annular line. These 3D parameters were analyzed in the mid-systolic phase. Immediate postrepair echocardiographic findings were confirmed by transthoracic echocardiography, which was performed just before and again at 1 month after discharge.

Definition of Residual MR

In the present study, residual MR was defined as (1) significant leakage found by a saline injection test during the initial repair procedure that resulted in conversion to prosthetic valve replacement based on the surgeon's decision, (2) MR with MRA $\geq 1 \text{ cm}^2$ confirmed by postbypass TEE after the initial repair procedure that required a corrective second pump run, or (3) very early (<1 month) recurrence of moderate or greater MR. Previous studies have shown that residual MR not exceeding trivial (MRA $\leq 2 \text{ cm}^2$) is associated with a durable repair result,^{5,16,17} though our institution uses more-strict criteria, as follows. Patients with MR exceeding an MRA of 1 cm^2 always undergo a corrective second pump run because complete elimination of MR is considered essential for good repair durability. Also, patients who develop early recurrent MR are classified as having residual MR because it is mostly procedure related and caused by technical issues.^{3,18}

Surgical Techniques

All operations were primarily performed by 2 of the authors (T.S., T.T.), who are qualified surgeons. Ninety-eight patients underwent a minimally invasive approach through a right minithoracotomy, whereas 19 underwent a standard median sternotomy. In most cases, the unsupported prolapsing portion of the PML was resected or pliated. For tall leaflets, a sliding or folding technique was utilized. A ring annuloplasty was performed in all cases using a true-sized annuloplasty ring, with ring selection based on surgeon preference. All patients came to the operating room with the intention to undergo an MV repair. Intraoperative postrepair TEE was performed after weaning from cardiopulmonary bypass.

Statistical Analysis

Continuous data are presented as the mean±SD, and were analyzed using a 2-tailed *t* test or compared with a Mann–Whitney *U* test for independent data, as appropriate. Categorical variables are given as numbers and percentage of patients, and were compared using a χ^2 or Fisher's exact test. Risk factors for residual MR were evaluated by univariate and multivariate logistic regression. The variables tested were age, sex, ring size and type, preoperative LV end-diastolic diameter, end-systolic diameter, LV ejection fraction (EF), left atrial (LA) volume, mitral annular area, anteroposterior and commissure-to-commissure mitral annular diameter, AML and PML angles, tenting height, and tenting volume. These factors were previously reported to be associated with MR recurrence following an MV repair.^{10,11} All continuous parameters were dichotomized at the value obtained by receiver-operating characteristics curve analysis as the threshold for logistic regression analysis. Uni- and multivariate linear regression analyses were used to investigate the relationship between AML angle and preoperative echocardiographic indices (LV end-diastolic diameter/LV end-systolic diameter, LVEF, LA volume, mitral annular area, anterior commissure/commissure-to-commissure mitral annular diameter). Univariate predictors with a *P*<0.1 were selected by a step-wise method and entered into multivariate analysis. A *P* value of less than 0.05 was considered to be significant. All data were analyzed using the Statistical Analysis Systems software package, JMP (version 13.0; SAS Institute Inc, Cary, NC).

Results

Patient Characteristics

Preoperative and intraoperative findings for the “residual MR” and control groups are presented in Table 1. Patients in the residual MR group tended to be older than those in the control

Table 1. Patient Characteristics

	Control (n=105)	Residual MR (n=12)	<i>P</i> Value
Age, y	58.6±12.3	65.6±9.9	0.063
Female, n (%)	25 (25)	4 (33)	0.469
Body surface area, m ²	1.67±0.18	1.69±0.31	0.815
Prolapsing segment, n (%)			0.462
P1	3 (3)	1 (8)	
P2	78 (74)	8 (67)	
P3	16 (15)	3 (25)	
≥2 segments	8 (8)	0 (0)	
MR etiology, n (%)			0.016
Myxomatous	43 (41)	1 (8)	
FED	56 (53)	11 (92)	
Endocarditis (healed)	6 (6)	0 (0)	
Repair techniques, n			
Resection and suture			
With height reduction	26	3	0.986
Without height reduction	47	3	0.190
Plication	22	3	0.746
Neochordal replacement	17	3	0.443
Annuloplasty ring			
Ring type, n (%)			0.066
Flexible	64 (61)	4 (33)	
Semirigid	41 (39)	8 (67)	
Ring size, mm	31±2	29±2	0.014
Approaches, n (%)			0.385
Median sternotomy	16 (15)	3 (25)	
Right minithoracotomy	89 (85)	9 (75)	
Preoperative rhythm, n (%)			0.143
Sinus	83 (79)	7 (58)	
Paroxysmal AF	12 (11)	3 (25)	
Persistent/LS persistent AF	10 (10)	2 (17)	
Concomitant procedures, n (%)			
CABG	9 (9)	2 (17)	0.363
Maze/PVI	20 (20)	5 (42)	0.070
Tricuspid ring annuloplasty	21 (20)	5 (42)	0.087

AF indicates atrial fibrillation; CABG, coronary artery bypass grafting; FED, fibroelastic deficiency; LS, long-standing; MR, mitral regurgitation; PVI, pulmonary vein isolation.

group, though the difference was not statistically significant (*P*=0.063). Patients in the residual MR group more frequently had fibroelastic deficiency (FED) as the MR etiology than the control group (*P*=0.016) and underwent implantation with a smaller annuloplasty ring (*P*=0.014). The definitive diagnosis of MR etiology was made intraoperatively. Patients were

classified as having FED when involvement of the leaflet was localized with healthy adjacent segments, or classified as having myxomatous disease when the valve had redundant tissue, annular dilatation, and chordae elongation. Sex, body surface area, distribution of prolapsing segments, repair techniques, surgical approaches, and concomitant procedures were similar between the groups, though the residual MR group tended to more frequently undergo ablation procedures for atrial fibrillation than the control group ($P=0.070$).

Operative Outcomes

There were no hospital deaths. Hospital morbidity cases included stroke (1.7%) and prolonged mechanical ventilation longer than 24 hours (0.9%), while no other major complications were noted. Four patients (3.4%), ranging in age from 73 to 78 years, had intraoperative conversion to MV replacement. FED was the etiology of MR in those patients, and leaflet resection with a 28-mm semirigid ring annuloplasty was performed in each. Intraoperatively, saline injection testing revealed obvious central leakage attributed to lack of coaptation caused by tethering of both leaflets (Video S1). In consideration of their age, MV replacement with a tissue valve was subsequently performed without a further attempt to repair. The remainder of the patients underwent a successful MV repair, though 7 (6 FED, 1 myxomatous degeneration) required a second pump run to correct residual MR. Those 7 patients showed sufficient valve competence in a saline injection test during the initial repair procedure. However, residual MR ($MRA \geq 1 \text{ cm}^2$) was revealed by postbypass TEE. The initial repair technique for those patients included leaflet resection in 3, plication in 3, and neochordal replacement in 1. During the second pump run, 5 patients were found to have leakage from a widened interscallop indentation, which was directly closed. Two patients were found to have leaflet retraction attributed to excessive plication during the initial repair (Video S2A), thus the plication sutures were removed and the repair was revised to a neochordal replacement (Video S2B). One patient had residual leaflet prolapse attributed to incomplete plication, and an additional free margin plication was added. In 2 patients who underwent implantation with a flexible annuloplasty band, a commissural annuloplasty was added instead of replacement with a smaller ring. To reduce the anteroposterior mitral annular diameter, each commissure was plicated with a mattress suture placed through the band. A commissural edge-to-edge suture was added in 1 patient. Following these second repair procedures, none of the patients showed residual MR. During the follow-up period, 1 patient developed moderate MR within the first month, which was confirmed by malcoaptation of the leaflets attributed to restrictive PML motion shown by transthoracic echocardiography.

Echocardiographic Measurements

Table 2 presents preoperative echocardiographic measurements. There were no differences between the groups regarding LV end-diastolic diameter, LV end-systolic diameter, LVEF, and LA volume measured by transthoracic echocardiography. Both the AML and PML angles were significantly higher in the residual MR group as compared with the control group, whereas no significant differences were noted in regard to mitral annular area and mitral annular diameter in either direction, AML area and length, tenting height, and tenting volume between the groups. In uni- and multivariate analyses, AML angle greater than 24.3° , a cut-off value calculated by receiver-operating characteristics curve analysis with an area under the curve of 0.77, was the only significant predictor of residual MR ($P=0.0049$; Table 3).

To determine factors influencing tethering of the AML, uni- and multivariate linear regression analyses were performed. Smaller anteroposterior annular diameter and lower LVEF were significantly associated with higher AML angle, whereas LV and LA dimension had no significant correlation (Table 4). Representative echocardiographic findings from each group are shown in Figure 1 and Video S3.

Table 2. Echocardiographic Data

	Control (n=105)	Residual MR (n=12)	P Value
3D-TEE			
Annular area, mm ²	1189±306	1075±338	0.226
Anteroposterior annular diameter, mm	34±5	32±6	0.092
CC annular diameter, mm	41±6	39±8	0.338
AML area, mm ²	734±211	669±210	0.309
AML length, mm	22±5	20±5	0.317
AML angle, °	21±8	28±7	0.002
PML angle, °	29±10	36±9	0.034
Tenting height, mm	7±6	9±4	0.258
Tenting volume, mL	1.36±1.50	2.15±1.58	0.090
2D-TTE			
LVDd, mm	54±6	53±7	0.843
LVDs, mm	34±6	32±6	0.380
LVEF, %	68±6	70±6	0.263
LAV, mL	73±53	87±35	0.380

2D-TTE indicates 2-dimensional transthoracic echocardiography; 3D-TEE, 3-dimensional transesophageal echocardiography; AML, indicates anterior mitral leaflet; CC, commissure-to-commissure; LAV, left atrial volume; LVDd, left ventricular end-diastolic diameter; LVDs, left ventricular end-systolic diameter; LVEF, left ventricular ejection fraction; MR, mitral regurgitation; PML, posterior mitral leaflet.

Table 3. Uni- and Multivariate Logistic Regression Analysis for Predictors of Residual MR

Variables	Univariate Analysis		Multivariate Analysis	
	OR (CI)	P Value	Adjusted OR (CI)	P Value
Age >67 y	3.67 (1.1–12.5)	0.0449		
Ring size ≤28 mm	6.50 (1.8–23.0)	0.0057		
Anteroposterior annular diameter ≤28 mm	5.33 (1.3–21.2)	0.0280		
AML angle >24.3°	7.86 (2.0–31.1)	0.0019	6.82 (1.8–33.8)	0.0049
PML angle >39.9°	7.08 (2.0–25.2)	0.0042		
Tenting volume >2.0 mL	4.04 (1.2–13.8)	0.0381		

AML indicates anterior mitral leaflet; CI, confidence interval; MR, mitral regurgitation; OR, odds ratio; PML, posterior mitral leaflet.

Table 4. Uni- and Multivariate Linear Regression Analysis for Predictors of AML Tethering

Variables	Univariate Analysis		Multivariate Analysis	
	R ²	P Value	Beta	P Value
Annular area	0.09	0.001		
Anteroposterior annular diameter	0.16	<0.001	−0.66	<0.001
CC annular diameter	0.10	0.001		
AML area	0.05	0.002		
LVEF	0.03	0.049	−0.26	0.002

AML indicates anterior mitral leaflet; CC, commissure-to-commissure; LVEF, left ventricular ejection fraction.

Discussion

Although the approach to a PML repair is standardized and reproducible with excellent long-term outcomes, some cases have suboptimal results even after a seemingly straightforward repair. Given that mild intraoperative residual MR is a predictor of MR recurrence and early adverse outcome,^{3,6,19} it is important to understand the mechanism of residual MR after performance of such standard repair procedures. Johnston et al examined echocardiographic findings of 2575 patients who underwent a standard quadrangular resection for PML prolapse and found that 6% developed moderate MR within the first 2 weeks after surgery. That initial rapid change in MR grade was associated with older age, LA enlargement, severe LV dysfunction, and intraventricular septal hypertrophy.²⁰ However, to the best of our knowledge, no previous reports have identified specific preoperative echocardiographic findings of 3D MV morphologies related to residual MR after a PML prolapse repair.

In the present study, we demonstrated that AML tethering is a significant predictor of residual MR after a PML repair. Even in patients with degenerative MR, it is not uncommon for preoperative echocardiography findings to show that the nonprolapsed leaflet is tethered. Otani et al noted secondary

AML tethering in 60% to 76% of patients with primary PML prolapse, which further exacerbates MR, thus creating a vicious cycle.¹² In the present study, we also found that AML tethering adversely affected early outcome after a PML repair. An AML angle greater than 23.4° predicts incomplete PML repair, resulting in conversion to MV replacement, requirement of a corrective second pump run, or early MR recurrence. Lee et al investigated the mechanism of recurrent functional MR after MV repair in cases of nonischemic dilated cardiomyopathy and found that a high apical tethering angle of the AML, with a cut-off value of 25°, was an independent risk factor of recurrent MR.¹⁰ Interestingly, our cut-off value is very similar to theirs, even though the reported etiologies of MR were different.

Regarding the mechanism of AML tethering, LV dilatation in cases of dilated cardiomyopathy has been widely proposed.^{10,11} LA dilatation may be another possible mechanism of AML tethering. Recent clinical studies have shown that LA dilatation with chronic atrial fibrillation causes not only annulus dilatation, but also leaflet tethering, which further aggravates atrial functional MR.^{21–23} However, in the present study, no significant correlations were found between LV/LA size and AML angle, with only LVEF showing a weak, but significant, negative correlation with AML angle in regard to preoperative cardiac function. These results may be explained by the fact that LV/LA remodeling was not evident in our patients, whose mean LV end-diastolic diameter/LV end-systolic diameter and LA volume values were 54±6/33±6 mm and 74±52 mL, respectively. In fact, severe LV/LA dilatation is not common in patients with degenerative MR because early surgery is generally recommended. Although leaflet tethering may occur in patients even without the presence of significant dilation of the cardiac chambers, the mechanism has not been clarified. As often observed in clinical settings, a decrease in leaflet mobility attributed to senile change is a possible alternative explanation for leaflet tethering without LV/LA dilatation (Figure 2; Video S4).

Another mechanism of AML tethering is attributable to MV morphology. Our univariate analysis findings showed that

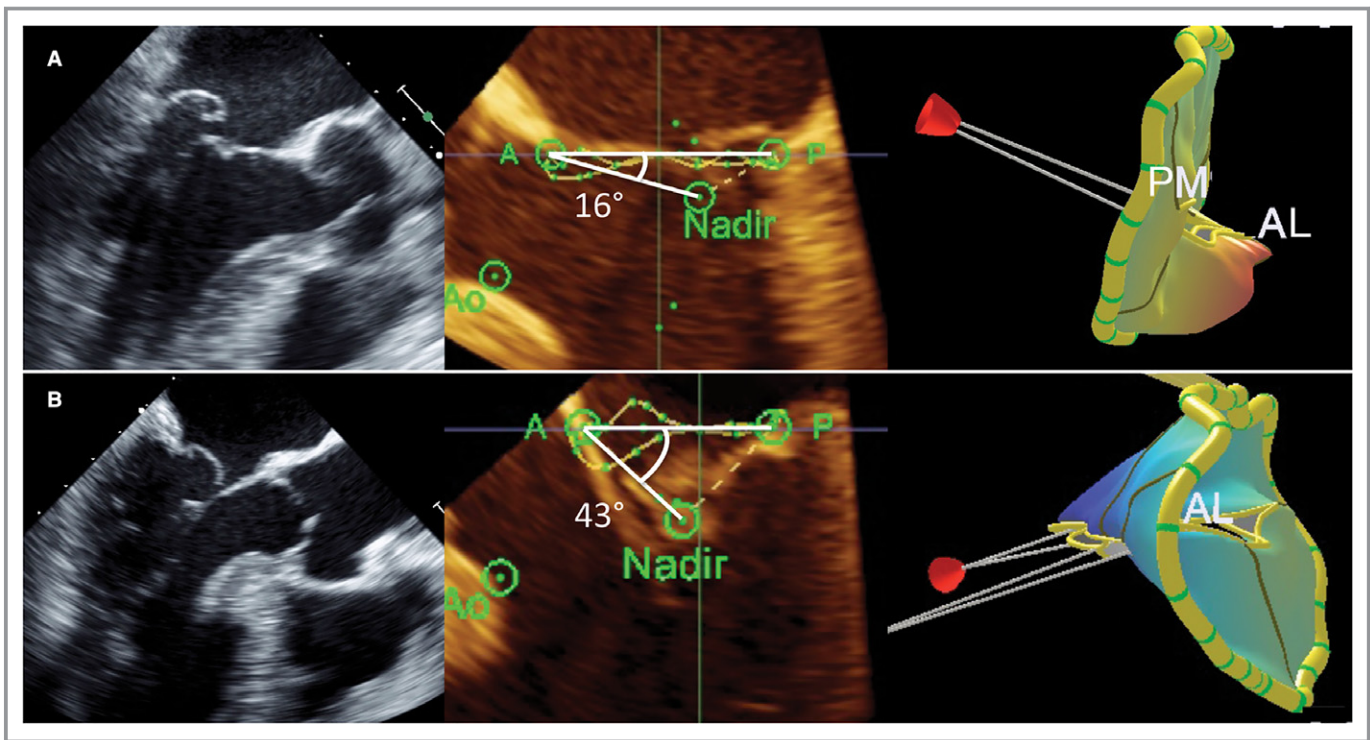


Figure 1. Preoperative transesophageal echocardiography findings in representative patients in (A) control and (B) residual MR groups. Marked AML tethering (43°) was noted in the residual MR group case (Video S3). AL indicates anterolateral; AML, anterior mitral leaflet; MR, mitral regurgitation; PM, posteromedial.

annular area, annular diameter in both directions, and AML area were negatively correlated with AML angle, whereas multivariate analysis identified anteroposterior annular

diameter as a significant predictor. In the present study, 92% of patients in the residual MR group had FED as the MR etiology, whereas the control group had a similar distribution between FED and myxomatous disease. A relatively small AML without marked annular dilatation is a common finding in patients with FED. Lack of excess leaflet tissue may make leaflet repair challenging to some degree, especially when a resection technique is utilized, which potentially increases the risk of PML tethering. Chan et al investigated the failure mode of MV repair and found that the mechanism in all recurrent MR cases after a repair for PML prolapse was leaflet tethering attributed to reduced leaflet mobility.⁶ In this context, existence of preoperative AML tethering further exacerbates leaflet malcoaptation. In the present cohort, 7 patients required a second pump run to correct residual MR and 2 who had received leaflet plication underwent conversion to neochordal replacement, whereas the other 5 received additional fine-tuning such as indentation closure, free margin plication, or an additional annuloplasty. Although these second repair procedures were successful and none of the patients developed recurrent MR (\geq moderate) during the mean follow-up period of 26.2 ± 20.0 months (5–60), careful consideration of the surgical strategy is needed for such patients. Based on our results, we currently use nonresectional techniques as the first choice for PML repair for patients with FED, especially in those with significant AML tethering.

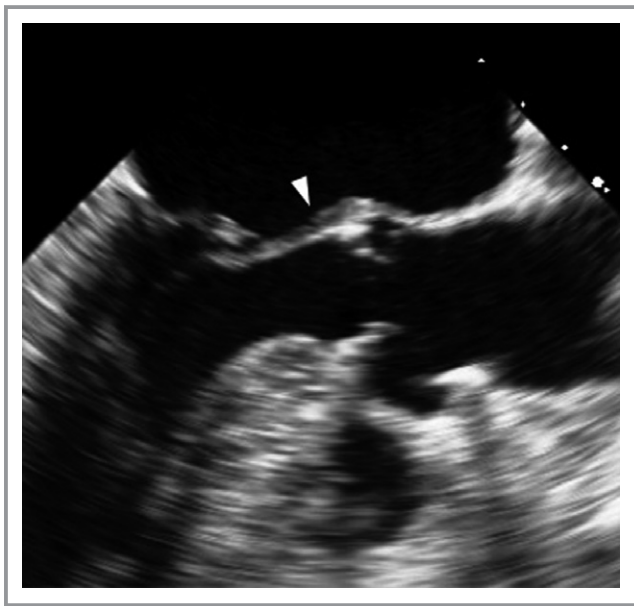

Figure 2. Representative residual MR group patient. The AML was tethered and its base thickened (arrowhead), resulting in reduced leaflet mobility (Video S4). AML indicates anterior mitral leaflet; MR, mitral regurgitation.

Limitations

The present study has several limitations. First, it was conducted as a single-center, retrospective, observational study with a relatively small number of patients, especially in the residual MR group. Because we usually do not accept any residual MR other than trivial in our patients shown by postbypass TEE, all left the operating room without significant residual MR, except for 4 who underwent conversion to MV replacement. In this context, it can be argued that patients who required a corrective second pump run should not have been included in the residual MR group because their final results were satisfactory. However, given that the aim of this study was to predict the difficulty of PML repair, we consider that such patients should be included in the analyses. Second, the end points in the present study were influenced by surgeon skill, thus there may have been some bias affecting the results. However, both surgeons who participated in the present study are well experienced, and the repair strategies used for isolated PML prolapse at our institute are generally standardized. Indeed, the reasons for residual MR in the present 12 patients were similar, with lack of leaflet coaptation the primary cause and no apparent technical failures such as suture dehiscence noted. Third, in this study, we only focused on PML prolapse, the most common finding in patients undergoing surgical treatment for degenerative MV disease. Therefore, the present results may not apply to cases with AML or bileaflet prolapse. Finally, we did not analyze late outcomes, because only 1 patient developed moderate or higher MR during the follow-up period. Larger studies with a longer follow-up period are necessary to more precisely clarify the mechanism of failure of MV repair.

Conclusions

MV repair for PML prolapse is an established procedure, and its indication is expanding into elderly populations. However, for patients with coexisting AML tethering, careful consideration of a thorough repair strategy is essential for obtaining a successful result.

Disclosures

None.

References

- Braunberger E, Deloche A, Berrebi A, Fayssol A, Celestin JA, Meimoun P, Chatellier G, Chauvaud S, Fabiani JN, Carpentier A. Very long-term results (more than 20 years) of valve repair with Carpentier's techniques in nonrheumatic mitral valve insufficiency. *Circulation*. 2001;104:I-8–I-11.
- Castillo JG, Anyanwu AC, Fuster V, Adams DH. A near 100% repair rate for mitral valve prolapse is achievable in a reference center: implications for future guidelines. *J Thorac Cardiovasc Surg*. 2012;144:308–312.
- Suri RM, Clavel MA, Schaff HV, Michelena HI, Huebner M, Nishimura RA, Enriquez-Sarano M. Effect of recurrent mitral regurgitation following degenerative mitral valve repair. Long-term analysis of competing outcomes. *J Am Coll Cardiol*. 2016;67:488–498.
- Shin HJ, Lee YJ, Choo SJ, Song H, Chung CH, Lee JW. Analysis of recurrent mitral regurgitation after mitral valve repair. *Asian Cardiovasc Thorac Ann*. 2005;13:261–266.
- Kasegawa H, Shimokawa T, Shibazaki I, Hayashi H, Koyanagi T, Ida T. Mitral valve repair for anterior leaflet prolapse with expanded polytetrafluoroethylene sutures. *Ann Thorac Surg*. 2006;81:1625–1631.
- Chan V, Elmstekawy E, Ruel M, Hynes M, Mesana TG. How does mitral valve repair fail in patients with prolapse?—Insights from longitudinal echocardiographic follow-up. *Ann Thorac Surg*. 2016;102:1459–1465.
- Adams DH, Rosenhek R, Falk V. Degenerative mitral valve regurgitation: best practice revolution. *Eur Heart J*. 2010;31:1958–1967.
- Uchimuro T, Tabata M, Saito K, Shibayama K, Watanabe H, Fukui T, Shimokawa T, Kasegawa H, Takanashi S. Post-repair coaptation length and durability of mitral valve repair for posterior mitral valve prolapse. *Gen Thorac Cardiovasc Surg*. 2014;62:221–227.
- Carpentier A. Cardiac valve surgery—the 'French correction'. *J Thorac Cardiovasc Surg*. 1983;86:323–337.
- Lee AP, Acker M, Kubo SH, Bolling SF, Park SW, Bruce CJ, Oh JK. Mechanisms of recurrent functional mitral regurgitation after mitral valve repair in nonischemic dilated cardiomyopathy. Importance of distal anterior leaflet tethering. *Circulation*. 2009;119:2606–2614.
- Magne J, Pibarot P, Dagenais F, Hachicha Z, Dumesnil JG, Sénéchal M. Preoperative posterior leaflet angle accurately predicts outcome after restrictive mitral valve annuloplasty for ischemic mitral regurgitation. *Circulation*. 2007;115:782–791.
- Otani K, Takeuchi M, Kaku K, Haruki N, Yoshitani H, Eto M, Tamura M, Okazaki M, Abe H, Fujino Y, Nishimura Y, Levine RA, Otsuji Y. Evidence of a vicious cycle in mitral regurgitation with prolapse secondary tethering attributed to primary prolapse demonstrated by three-dimensional echocardiography exacerbates regurgitation. *Circulation*. 2012;126:S214–S221.
- Nishimura RA, Otto CM, Bonow RO, Carabello BA, Erwin JP III, Guyton RA, O'Gara PT, Ruiz CE, Skubas NJ, Sorajja P, Sundt TM III, Thomas JD; ACC/AHA Task Force Members. 2014 AHA/ACC guideline for the management of patients with valvular heart disease: a report of the American College of Cardiology/American Heart Association Task Force on Practice Guidelines. *Circulation*. 2014;130:e120.
- Zoghbi WA, Enriquez-Sarano M, Foster E, Grayburn PA, Kraft CD, Levine RA, Nihoyannopoulos P, Otto CM, Quinones MA, Rakowski H, Stewart WJ, Waggoner A, Weissman NJ; American Society of Echocardiography. Recommendations for evaluation of the severity of native valvular regurgitation with two-dimensional and Doppler echocardiography. *J Am Soc Echocardiogr*. 2003;16:777–802.
- Kagiyama N, Toki M, Hara M, Fukuda S, Aritaka S, Miki S, Ohara M, Hayashida A, Hirohata A, Yamamoto K, Yoshida K. Efficacy and accuracy of novel automated mitral valve quantification: three-dimensional transesophageal echocardiographic study. *Echocardiography*. 2016;33:756–763.
- Saiki Y, Kasegawa H, Kawase M, Osada H, Ootaki E. Intraoperative TEE during mitral valve repair: does it predict early and late postoperative mitral valve dysfunction? *Ann Thorac Surg*. 1998;66:1277–1281.
- Okada Y, Nasu M, Koyama T, Shomura Y, Yuzaki M, Murashita T, Fukunaga N, Konishi Y. Outcomes of mitral valve repair for bileaflet prolapse. *J Thorac Cardiovasc Surg*. 2012;143:S21–S23.
- Dumont E, Gillinov AM, Blackstone EH, Sabik JF III, Svensson LG, Mihaljevic T, Houghtaling PL, Lytle BW. Reoperation after mitral valve repair for degenerative disease. *Ann Thorac Surg*. 2007;84:444–450.
- Rizza A, Sulcaj L, Glauber M, Trianni G, Palmieri C, Mariani M, Maffei S, Berti S. Predictive value of less than moderate residual mitral regurgitation as assessed by transesophageal echocardiography for the short-term outcomes of patients with mitral regurgitation treated with mitral valve repair. *Cardiovasc Ultrasound*. 2007;5:25.
- Johnston DR, Gillinov AM, Blackstone EH, Griffin B, Stewart W, Sabik JF III, Mihaljevic T, Svensson LG, Houghtaling PL, Lytle BW. Surgical repair of posterior mitral valve prolapse: implications for guidelines and percutaneous repair. *Ann Thorac Surg*. 2010;89:1385–1394.
- Machino-Ohtsuka T, Seo Y, Ishizu T, Sato K, Sugano A, Yamamoto M, Hamada-Harimura Y, Aonuma K. Novel mechanistic insights into atrial functional mitral regurgitation. 3-dimensional echocardiographic study. *Circ J*. 2016;80:2240–2248.
- Takahashi Y, Abe Y, Sasaki Y, Bito Y, Morisaki A, Nishimura S, Shibata T. Mitral valve repair for atrial functional mitral regurgitation in patients with chronic atrial fibrillation. *Interact Cardiovasc Thorac Surg*. 2015;21:163–168.
- Silbiger JJ. Does left atrial enlargement contribute to mitral leaflet tethering in patients with functional mitral regurgitation? Proposed role of atrio-genic leaflet tethering. *J Heart Valve Dis*. 2014;23:385–386.

Residual Mitral Regurgitation After Repair for Posterior Leaflet Prolapse—Importance of Preoperative Anterior Leaflet Tethering

Taichi Sakaguchi, Nobuyuki Kagiya, Misako Toki, Arudo Hiraoka, Akihiro Hayashida, Toshinori Totsugawa, Kentaro Tamura, Genta Chikazawa, Hidenori Yoshitaka and Kiyoshi Yoshida

J Am Heart Assoc. 2018;7:e008495; originally published June 1, 2018;

doi: 10.1161/JAHA.117.008495

The *Journal of the American Heart Association* is published by the American Heart Association, 7272 Greenville Avenue, Dallas, TX 75231
Online ISSN: 2047-9980

The online version of this article, along with updated information and services, is located on the World Wide Web at:

<http://jaha.ahajournals.org/content/7/11/e008495>