

Wright State University
CORE Scholar

Department of Surgery Faculty Publications

Surgery

9-2017

Staged Reconstruction of the Inferior Vena Cava After Gunshot Injury

Nathan M. Droz

Wright State University, nathan.droz@wright.edu

John K. Bini

Wright State University, john.bini@wright.edu

Kamran A. Jafree

Wright State University, kamran.jafree@wright.edu

John H. Matsuura

Wright State University, john.matsuura@wright.edu

Follow this and additional works at: <https://corescholar.libraries.wright.edu/surg>



Part of the [Surgery Commons](#)

Repository Citation

Droz, N. M., Bini, J. K., Jafree, K. A., & Matsuura, J. H. (2017). Staged Reconstruction of the Inferior Vena Cava After Gunshot Injury. *Journal of Vascular Surgery Cases and Innovative Techniques*, 3 (3), 136-138. <https://corescholar.libraries.wright.edu/surg/747>

This Article is brought to you for free and open access by the Surgery at CORE Scholar. It has been accepted for inclusion in Department of Surgery Faculty Publications by an authorized administrator of CORE Scholar. For more information, please contact library-corescholar@wright.edu.

Staged reconstruction of the inferior vena cava after gunshot injury

Nathan M. Droz, MD, John K. Bini, MD, Kamran A. Jafree, MBBS, and John H. Matsuura, MD, *Dayton, Ohio*

ABSTRACT

A 23-year-old man with a gunshot injury to the abdomen and cardiac arrest requiring emergency department thoracotomy had a transection of the distal inferior vena cava (IVC) and small bowel injury. Because of persistent hemorrhagic shock, the IVC was ligated. During the next 3 days, he developed worsening bilateral leg edema. He was taken back for reanastomosis of his small bowel and reconstruction of the IVC using autologous femoral vein harvested from the right leg. We think that patients requiring ligation of the vena cava with worsening leg edema can benefit from a staged reconstruction of the IVC. (*J Vasc Surg Cases and Innovative Techniques* 2017;3:136-8.)

Penetrating injuries of the inferior vena cava (IVC) carry a high mortality.¹⁻⁵ In a hemodynamically unstable patient, ligation of the vena cava often becomes necessary as a lifesaving measure. We describe a delayed reconstruction of the IVC using autologous femoral vein after stabilization of the patient. This case demonstrates the value of working with the trauma team in successful resuscitation of severe shock, acidosis, and hypothermia and in control of abdominal contamination before a venous bypass. The patient has consented to this case presentation.

CASE REPORT

A 23-year-old man arrived in the trauma bay with severe hypotension after a gunshot injury to the abdomen. During emergency department resuscitation, the patient arrested, requiring thoracotomy and aortic cross-clamping. The patient was placed on massive transfusion protocol and transported to the operating room for exploration, with findings of a transected distal IVC involving both origins of the common iliac veins. His aorta and iliac arteries were intact. Because of his persistent hemorrhagic shock, the IVC and both iliac veins were ligated (*Fig 1*). A segment of small bowel was also injured and treated with resection, leaving the bowel in discontinuity as the abdomen was left open, and the patient was transferred to the surgical

intensive care unit. The patient received 9 units of packed cells, 8 units of fresh frozen plasma, 1 pack of platelets, and 1 unit of cryoprecipitate. During the next 3 days, his acidosis and coagulopathy were corrected, and the patient developed isolated lower extremity edema. The trauma and vascular surgery teams planned a combined reanastomosis of his bowel and venous bypass. Because of his younger age and associated bowel injury, we harvested the right femoral vein, between the deep and popliteal veins, and created a bifurcated bypass (*Fig 2*). The patient was discharged home on clopidogrel and graded compression stockings. His venous duplex ultrasound study at 2 weeks showed a patent bypass. At 1-month follow-up, his incisions were healed and he had no residual leg edema.

DISCUSSION

IVC injuries are rare and more often the result of penetrating trauma, occurring in approximately 0.02% of gunshot wounds to the abdomen.^{2,6} Mortality of IVC injuries is quoted in most series to be around 50%.^{1,2} Factors associated with increased mortality are hypotension on arrival to the emergency department, associated major vascular injury, and level of IVC injury, with proximal injuries carrying the highest mortality (suprahepatic).^{1,7,8}

The management of traumatic IVC injuries is largely dependent on the location of injury and degree of injury. Similar to our patient, damage control strategies in the setting of coagulopathy, hemorrhage, and acidosis have been described.^{9,10} Based on multiple large series dealing with IVC injuries, management options for less severe infrahepatic IVC injuries include lateral repair, end-to-end anastomosis, vein patch, and vein or synthetic grafting.^{2-5,11}

A variety of conduits have been employed for major vascular reconstructions.¹² In the absence of intra-abdominal contamination, ringed polytetrafluoroethylene is often used for vascular reconstruction,¹³ whereas in a contaminated setting, femoral vein offers an excellent conduit.¹⁴⁻¹⁶ Femoral vein provides a durable, long-segment, large-caliber vein for reconstruction. Several

From the Department of Surgery, Wright State University Boonshoft School of Medicine.

Author conflict of interest: none.

Presented at the Fortieth Annual Meeting of the Midwestern Vascular Surgical Society, Columbus, Ohio, September 8-10, 2016.

Correspondence: Nathan M. Droz, MD, Wright State University Department of Surgery, 128 E Apple St, Ste 7000, Dayton, OH 45409 (e-mail: nathandroz824@gmail.com).

The editors and reviewers of this article have no relevant financial relationships to disclose per the Journal policy that requires reviewers to decline review of any manuscript for which they may have a conflict of interest.

2468-4287

© 2017 The Authors. Published by Elsevier Inc. on behalf of Society for Vascular Surgery. This is an open access article under the CC BY-NC-ND license (<http://creativecommons.org/licenses/by-nc-nd/4.0/>).

<http://dx.doi.org/10.1016/j.jvs.2017.03.005>

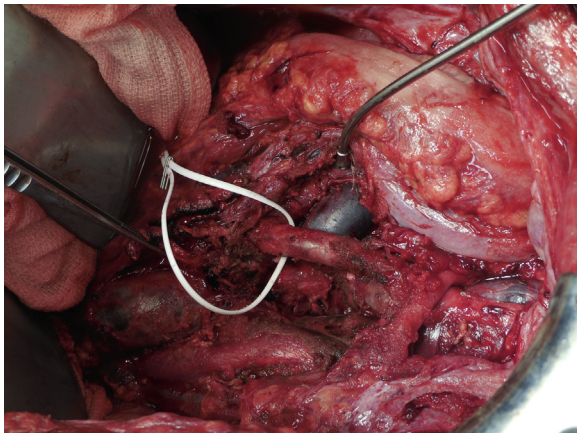


Fig 1. Ligated inferior vena cava (IVC) and origins of the common iliac veins.

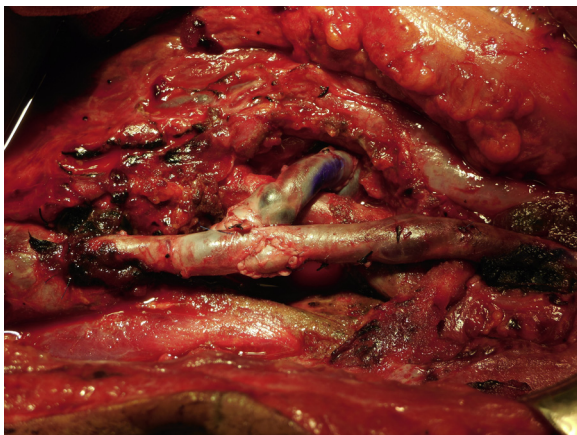


Fig 2. Bifurcated bypass using harvested femoral vein in the thigh.

studies have documented minimal lower extremity venous comorbidities when the vein is harvested between the deep and popliteal veins.^{14,16,17}

In our case, the trauma service had ligated both the IVC and bilateral iliac veins as a damage control maneuver. The patient subsequently developed early, progressive lower extremity edema. Based on the early progressive edema, at a planned second-look laparotomy after a completed resuscitation, we opted to perform the venous reconstruction. The ease of exposure and controlled contamination facilitated a successful reconstruction. Although it is not necessary in all patients, an attempt at reconstruction can be considered in patients developing rapidly progressive lower extremity edema.

There are no published case series or reports on a staged approach to reconstruction of the IVC after emergency ligation. There are studies showing an absence of leg edema after IVC ligation.^{6,12} However, in our institution, we do see patients presenting to the clinic after

emergency IVC ligation with worsening leg edema, many several years after ligation, when reconstruction may be hazardous because of extensive collateral vein development and a scarred retroperitoneum.

In our institution, traumatic IVC injuries are rare. We have performed only one other reconstruction in 4 years. It is still our practice to monitor patients after IVC ligation for progressive edema and not to perform early reconstruction. Guidelines are difficult to develop on a single case report. This case report simply illustrates one alternative approach for postligation patients who develop early progressive edema.

CONCLUSIONS

We think that a staged approach to reconstruction of the IVC can be considered, particularly when there are early signs of progressive leg edema. The opportunity to approach a major venous bypass when the patient is stable and the dissection of the site of injury is uncomplicated gives us better options for reconstruction.

REFERENCES

1. Kuehne J, Frankhouse J, Modrall G, Golshani S, Aziz I, Demetriades D, et al. Determinants of survival after inferior vena cava trauma. *Am Surg* 1999;65:976-81.
2. Buckman RF, Pathak AS, Badellino MM, Bradley KM. Injuries of the inferior vena cava. *Surg Clin North Am* 2001;81:1431-47.
3. Navsaria PH, de Bruyn P, Nicol AJ. Penetrating abdominal vena cava injuries. *Eur J Vasc Endovasc Surg* 2005;30:499-503.
4. Burch JM, Feliciano DV, Mattox KL, Edelman M. Injuries of the inferior vena cava. *Am J Surg* 1988;156:548-52.
5. Degiannis E, Velmahos GC, Levy RD, Souter I, Benn CA, Saadia R. Penetrating injuries of the abdominal inferior vena cava. *Ann R Coll Surg Engl* 1996;78:485-9.
6. Sullivan PS, Dente CJ, Patel S, Carmichael M, Srinivasan JK, Wyrzykowski AD, et al. Outcome of ligation of the inferior vena cava in the modern era. *Am J Surg* 2010;199:500-6.
7. Rosengart MR, Smith DR, Melton SM, May AK, Rue LW. Prognostic factors in patients with inferior vena cava injuries. *Am Surg* 1999;65:849-55; discussion: 855-6.
8. Huerta S, Bui TD, Nguyen TH, Banimahd FN, Porral D, Dolich MO. Predictors of mortality and management of patients with traumatic inferior vena cava injuries. *Am Surg* 2006;72:290-6.
9. Lamb CM, MacGoey P, Navarro AP, Brooks AJ. Damage control surgery in the era of damage control resuscitation. *Br J Anaesth* 2014;113:242-9.
10. Aucar JA, Hirshberg A. Damage control for vascular injuries. *Surg Clin* 1997;77:853-62.
11. Agarwal N, Shah PM, Clauss RH, Reynolds BM, Stahl WM. Experience with 115 civilian venous injuries. *J Trauma* 1982;22:827-32.
12. Pulitanó C, Crawford M, Ho P, Gallagher J, Joseph D, Stephen M, et al. The use of biological grafts for reconstruction of the inferior vena cava is a safe and valid alternative: results in 32 patients in a single institution. *HPB (Oxford)* 2013;15:628-32.

13. Quinones-Baldrich WJ, Farley S. Techniques for inferior vena cava resection and reconstruction for retroperitoneal tumor excision. *J Vasc Surg Venous Lymphat Disord* 2013;1:84-9.
14. Sadaghianloo N, Durand M, Benizri EI, Declémy S, Jean-Baptiste E, Hassen-Khodja R. Customized femoral vein grafts for inferior vena cava reconstruction. *J Vasc Surg Venous Lymphat Disord* 2014;2:200-3.
15. Brahmanandam S, Clair D, Bena J, Sarac T. Adjunctive use of the superficial femoral vein for vascular reconstructions. *J Vasc Surg* 2012;55:1355-62.
16. Hagino RT, Bengtson TD, Fosdick DA, Valentine RJ, Clagett GP. Venous reconstructions using the superficial femoral-popliteal vein. *J Vasc Surg* 1997;26:829-37.
17. Wells JK, Hagino RT, Bargmann KM, Jackson MR, Valentine RJ, Kakish HB, et al. Venous morbidity after superficial femoral-popliteal vein harvest. *J Vasc Surg* 1999;29:282-9; discussion: 289-91.

Submitted Dec 8, 2016; accepted Mar 31, 2017.