



Case report

ARDS from miliary tuberculosis successfully treated with ECMO

Edda Vesteynsdottir^a, Gunnar Myrdal^b, Kristinn O. Sverrisson^a, Sigurbjorg J. Skarphedinsdottir^a, Olafur Gudlaugsson^c, Sigurbergur Karason^{a,d,*}

^a Landspítali University Hospital, Department of Anaesthesia and Intensive Care, Hringbraut, 101, Reykjavík, Iceland

^b Landspítali University Hospital, Department of Cardiothoracic Surgery, Hringbraut, 101, Reykjavík, Iceland

^c Landspítali University Hospital, Department of Infectious Diseases, Fossvogi, 108, Reykjavík, Iceland

^d University of Iceland, Faculty of Medicine, Vatnsmyrarveggi 16, 101, Reykjavík, Iceland



ARTICLE INFO

Keywords:

Acute respiratory distress syndrome (ARDS)

Tuberculosis

Extracorporeal membrane oxygenation (ECMO)

Critical care

Antitubercular agents

ABSTRACT

Tuberculosis is a rare cause of *acute respiratory distress syndrome* (ARDS) and mortality rates are high in tuberculosis patients that need treatment with mechanical ventilation. Experience of the use of *extracorporeal membrane oxygenation* (ECMO) in such circumstances is scarce. We report the case of an 18 year old man where prolonged therapy (50 days) with *extracorporeal membrane oxygenation* (ECMO) allowed extensive lung damage from miliary tuberculosis to heal. The case reflects how challenging the diagnosis of tuberculosis may be and how difficult it is to reach adequate blood levels of anti-tuberculosis drugs while on ECMO. It's also an example of how indications for ECMO have been expanding the last years and that long term ECMO therapy is possible without serious complications.

1. Introduction

Tuberculosis remains an important global health issue causing considerable morbidity and mortality. The development of *acute respiratory distress syndrome* (ARDS) is however rare [1] and most often seen in disseminated disease (*miliary tuberculosis*) [2,3]. Mortality rates for patients with tuberculosis who require mechanical ventilation are high (60–70%) [3–5], higher than for any other cause of ARDS [1]. Experience with the use of *extracorporeal membrane oxygenation* (ECMO) in this setting is limited, with only a handful of case-reports published [6]. We present a case of miliary tuberculosis where prolonged ECMO therapy was successful but both diagnosis and treatment of the infection challenging.

2. Case presentation

A previously healthy 18 year old male was admitted to hospital with a few days history of fever and shortness of breath. Chest X-ray showed bilateral interstitial infiltrates and empirical therapy for presumed community-acquired pneumonia was started. A more thorough history taking revealed symptoms of weight loss, lethargy and swallowing difficulties of three months duration. The patient was in hypoxic respiratory failure and therefore intubated within a few hours of

admission. A *computed tomography* (CT) scan showed widespread nodular infiltrates and signs of an abscess in the mediastinum (Fig. 1). Later CT scans confirmed leakage of contrast medium from the oesophagus to the mediastinum but endoscopy did not reveal any obvious pathology.

The patient was septic on admission and needed high-dose vasopressors. Hemodynamic instability resolved within few days but the respiratory failure did not. The patient received lung-protective mechanical ventilation for 18 days, with intermittent prone positioning. Initial cultures from bronchoalveolar lavage and viral polymerase chain reaction (PCR) assays were negative. Ziehl-Neelsen staining did not reveal acid-fast bacilli on repeated samples of tracheal aspirates. Interferon- γ release assay (IGRA) for tuberculosis was indeterminate. An extensive work-up regarding infectious, malignant and immunological causes was negative. Antibiotic therapy was expanded and the patient received empirical corticosteroids and immunoglobulins. At last transbronchial biopsies were taken with fiberoptic bronchoscopy guidance. Shortly after that intervention the patient developed bilateral tension pneumothoraces, pneumopericardium and subcutaneous emphysema (Fig. 2). Despite prompt drainage of both pleura, oxygenation of the patient became critical and *veno-venous ECMO* therapy was started.

Microscopy of transbronchial biopsies revealed acid-fast bacilli and tuberculosis treatment was initiated with *rifampicin*, *isoniazide*, *ethambutol* and *pyrazinamide*. The diagnosis of miliary tuberculosis was later

* Corresponding author. Department of Anaesthesia and Intensive Care, Landspítali University Hospital Hringbraut, 101, Reykjavík Iceland.

E-mail addresses: eddave@landspitali.is (E. Vesteynsdottir), myrdal@landspitali.is (G. Myrdal), kristsv@landspitali.is (K.O. Sverrisson), sigskarp@landspitali.is (S.J. Skarphedinsdottir), olafgudl@landspitali.is (O. Gudlaugsson), skarason@landspitali.is (S. Karason).

<https://doi.org/10.1016/j.rmcr.2019.01.005>

Received 22 August 2018; Received in revised form 4 January 2019; Accepted 4 January 2019

2213-0071/© 2019 The Authors. Published by Elsevier Ltd. This is an open access article under the CC BY-NC-ND license (<http://creativecommons.org/licenses/by-nc-nd/4.0/>).

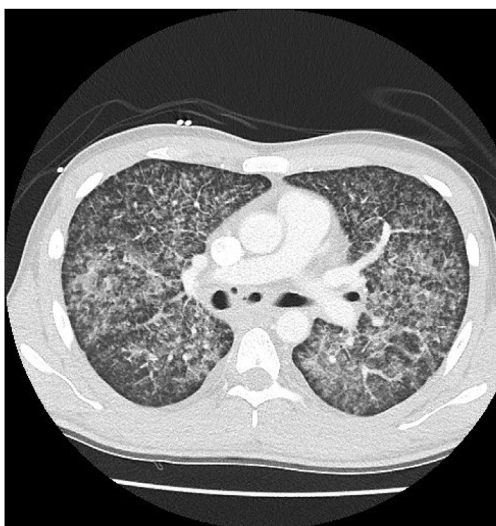


Fig. 1. A CT scan the day after admission showing multiple nodular infiltrates. Mediastinal abscess not visible in this slide.

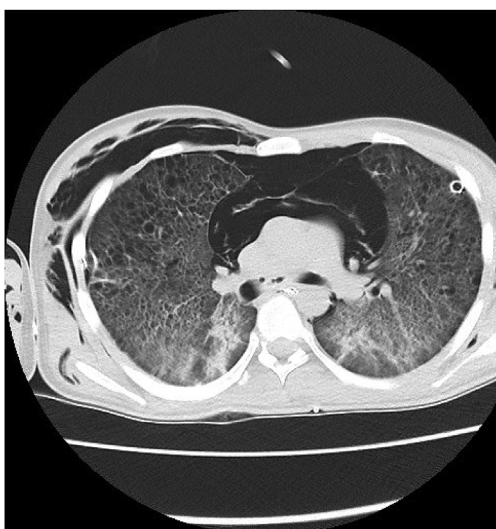


Fig. 2. A CT scan after 18 days in the ICU. The patient developed bilateral pneumothoraces, pneumopericardium and pneumomediastinum after a transbronchial biopsy. Bilateral pleural tubes in-situ.

confirmed (26 days after admission) when growth of *Mycobacterium tuberculosis* was detected in samples taken at admission. The bacteria grew in tracheal aspirate, urine and cerebrospinal fluid. Additionally, granulomas were seen in a bone marrow aspirate, liver and lung biopsies. The bacteria was found to be susceptible to all first-line anti-tuberculosis agents. The patient's dysphagia and mediastinal abscess were probably related to tuberculosis in the mediastinum. During the ECMO treatment the patient's lungs developed multiple bullae and he had persistent pneumothoraces where the lungs did not expand despite patent pleural tubes (Fig. 3).

Serum levels of anti-tuberculosis agents were monitored and levels of both isoniazid and rifampicin were repeatedly subtherapeutic despite escalating doses and a change to intravenous administration. After multiple negative samples, acid-fast bacilli were seen in tracheal aspirates on two occasions, four weeks after the start of treatment. During the VV-ECMO treatment, a multi-resistant *Pseudomonas aeruginosa* and *Stenotrophomonas maltophilia* were repeatedly cultured from tracheal aspirates. These bacteria were successfully eradicated with a combination therapy of inhaled *colistin* and *tobramycin* along with intravenous

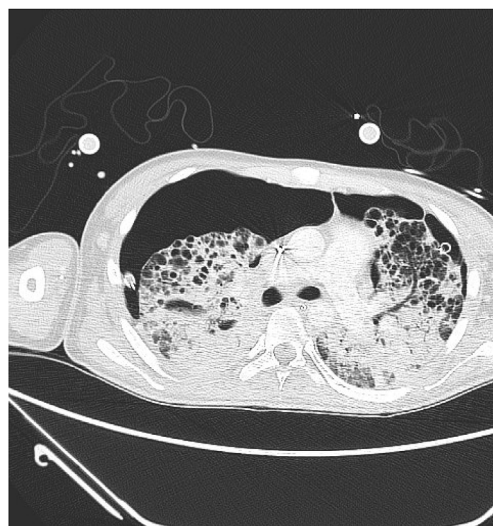


Fig. 3. A CT scan after two weeks on VV-ECMO. Both lungs show numerous bullae and there were persistent bilateral pneumothoraces despite pleural tubes in-situ.

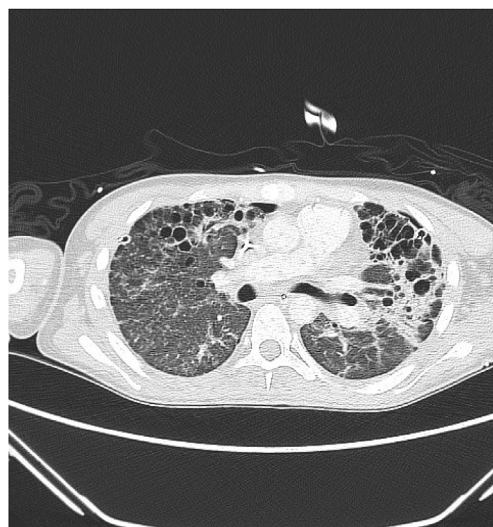


Fig. 4. A CT scan after 46 days on ECMO. Both lungs have expanded with functional lung tissue visible again. This correlated with improvement clinically.

amikacin, *meropenem* and *ceftazidime/avibactam*. As with the anti-tuberculosis agents, serum levels of *amikacin* were low.

After 45 days on ECMO the patient started to show signs of recovery with increasing lung compliance and re-expansion of the lungs (Fig. 4). He was successfully weaned from ECMO after 50 days. Complications during the ECMO run were thrombocytopenia, minor bleedings from puncture sites and sensory symptoms in lower limbs. The patient stayed a total of 76 days in the ICU. After three months of rehabilitation he was back at home and had resumed previous activities, including sports.

3. Discussion

The use of ECMO in ARDS has been increasing rapidly in recent years [7] and indications may be expanding. We have described successful use of ECMO in miliary tuberculosis, even though the patient had two relative contraindications for ECMO (mechanical ventilation with a high FiO_2 (0.75–1.0) for 18 days and an unknown diagnosis at the time) [8]. The lack of data on the use of ECMO for tuberculosis made prognostication difficult. Since the patient was young, without

co-morbidities and with a single-organ failure, the therapy was continued, even though no signs of recovery were discernible for weeks. Technological advances have made longer ECMO runs possible without complications and studies have shown equivalent outcome for patients with short and extended runs [9].

Tuberculosis is a rare cause of ARDS, even in high burden regions [2,10]. ARDS is most often seen in the disseminated form of the disease (*miliary*) [2,3] which only 1–2% of all tuberculosis patients exhibit [11,12]. Published case-series of miliary tuberculosis have shown that 3–10% of these patients develop ARDS [11,13]. The clinical picture tends to be with prodromal symptoms (fever, anorexia) for weeks prior to a rapid deterioration [2,3] and this might help to differentiate ARDS from tuberculosis from other causes of ARDS.

The diagnosis of miliary tuberculosis can be challenging when the infection has caused the development of ARDS. The classical miliary pattern may be absent on a chest X-ray in 50% of patients [12] although computed tomography scans have a higher sensitivity. Waiting for positive cultures (2–6 weeks) is not practical in these critically ill patients. Rates of positive microscopy for acid-fast bacilli in sputum samples have been low (32%–36%) in case series of miliary tuberculosis [11,13]. The yield of microscopy was similar on samples obtained with the aid of bronchoscopy (31%) but the diagnosis of tuberculosis was rapidly obtained in 79% of patients with the addition of transbronchial biopsies during bronchoscopy [14]. Current guidelines recommend fiberoptic bronchoscopy in sputum negative patients with suspected miliary tuberculosis, and that sampling should include bronchial brushings and/or transbronchial biopsy, especially in critically ill patients [15]. Newer molecular methods (PCR) on bronchoalveolar lavage have shown 60–80% sensitivity for tuberculosis in smear-negative patients [16,17] and may be an alternative to transbronchial biopsies where available. Transbronchial biopsies are not without risks in this patient population as demonstrated in our case.

Successful eradication of tuberculosis is dependent on adequate blood levels of anti-tuberculosis drugs [1]. The first-line agents (apart from rifampicin) are generally only available as oral preparations and thus dependent on adequate absorption from the gastrointestinal tract, which cannot be relied on in the critically ill. We did not reach therapeutic targets for two agents during the ECMO therapy. Sub-therapeutic levels of these drugs while on ECMO have been reported before [18]. The ECMO circuit increases the volume of distribution for drugs and there is evidence for substantial sequestration of drugs in the circuits [19]. There is a general lack of guidelines on optimal drug dosing for patients on ECMO.

The development of pneumothorax is not uncommon in tuberculosis and the management of this during ECMO can be challenging, as pleural tube placement is frequently accompanied by bleeding. Current guidelines [8] from the Extracorporeal Life Support Organization (ELSO) recommend drainage with continuous suction for symptomatic pneumothorax (> 50% of hemithorax, enlarging or with hemodynamic compromise). Inspiratory pressure on the ventilator should be kept low or even at zero until air leaks have sealed. Managing patients with ARDS on ECMO without a ventilator is an emerging approach [20,21] that may be useful in cases like this but further studies are needed.

4. Conclusions

We have reported a case where prolonged ECMO therapy allowed extensive lung injury from miliary tuberculosis to heal, with a good outcome for the patient. Both diagnosis and treatment of tuberculosis is complex in the intensive care setting.

Conflicts of interest

The authors have no conflicts of interest to declare.

Informed consent

Written informed consent was obtained from the patient and his family.

Acknowledgements

Gratitude to Jonas Lindholm from the ECMO Center at Karolinska University Hospital, Stockholm, Sweden, for advice on treatment of the patient.

References

- [1] A. Otu, M. Hashmi, A. Mukhtar, et al., The critically ill patient with tuberculosis in intensive care: clinical presentations, management and infection control, *J. Crit. Care* 45 (2018) 184–196.
- [2] R. Agarwal, D. Gupta, A.N. Aggarwal, et al., Experience with ARDS caused by tuberculosis in a respiratory intensive care unit, *Intensive Care Med.* 31 (2005) 1284–1287.
- [3] Y.J. Kim, K.M. Pack, E. Jeong, et al., Pulmonary tuberculosis with acute respiratory failure, *Eur. Respir. J.* 32 (2008) 1625–1630.
- [4] D.R. Silva, D.M. Menegotto, L.F. Schulz, et al., Mortality among patients with tuberculosis requiring intensive care: a retrospective cohort study, *BMC Infect. Dis.* 10 (2010) 54.
- [5] K. Lee, J.H. Kim, J.H. Lee, et al., Acute respiratory distress syndrome caused by miliary tuberculosis: a multicentre survey in South Korea, *Int. J. Tubercul. Lung Dis.* 15 (2011) 1099–1103.
- [6] N. Omote, Y. Kondoh, H. Taniguchi, et al., Acute respiratory distress syndrome due to severe pulmonary tuberculosis treated with extracorporeal membrane oxygenation: a case report and review of the literature, *Resp. Med. Case Rep.* 19 (2016) 31–33.
- [7] ECLS Registry Report - International Summary 2017, Extracorporeal Life Support Organization, Ann Arbor, MI, USA, January 2017 <https://www.elseo.org/Registry/Statistics/InternationalSummary.aspx>, Accessed date: 15 June 2018.
- [8] ELSO Guidelines for Adult Respiratory Failure, Extracorporeal Life Support Organization, Ann Arbor, MI, USA, August 2017 <https://www.elseo.org/Portals/0/ELSO%20Guidelines%20For%20Adult%20Respiratory%20Failure%201.4.pdf>, Version 1.4, Accessed date: 15 June 2018.
- [9] J. Menaker, R.P. Rabinowitz, A. Tabatabai, et al., Veno-venous extracorporeal membrane oxygenation for respiratory failure: how long is too long? *ASAIO J.* (2018), <https://doi.org/10.1097/MAT.0000000000000791> Mar 28.
- [10] P.V. Muthu, S. Dhooira, A.N. Aggarwal, et al., Acute respiratory distress syndrome due to tuberculosis in a respiratory ICU over a 16-year period, *Crit. Care Med.* 45 (2017) e1087–1090.
- [11] A. Mert, F. Arslan, T. Kuyucu, et al., Miliary tuberculosis – epidemiological and clinical analysis of large case series from moderate to low tuberculosis endemic country, *Medicine* 96 (2017) 5.
- [12] K.S. Sharma, A. Mohan, A. Sharma, et al., Miliary tuberculosis: new insights into an old disease, *Lancet Infect. Dis.* 5 (2005) 415–430.
- [13] S.F. Hussain, M. Irfan, M. Abbasi, et al., Clinical characteristics of 110 miliary tuberculosis patients from a low HIV prevalence country, *Int. J. Tubercul. Lung Dis.* 8 (2004) 493–499.
- [14] P.A. Willcox, P.D. Potgieter, E.D. Bateman, et al., Rapid diagnosis of sputum negative miliary tuberculosis using the flexible fiberoptic bronchoscope, *Thorax* 41 (1986) 681–684.
- [15] D.M. Lewinsohn, M.K. Leonard, P.A. LoBue, et al., Official American thoracic society/infectious diseases society of America/centers for disease control and prevention clinical practice guidelines: diagnosis of tuberculosis in adults and children, *Clin. Infect. Dis.* 64 (2017) 111–115.
- [16] P. Le Palud, V. Cattoir, B. Malbrun, et al., Retrospective observational study of diagnostic accuracy of the Xpert® MTB/RIF assay on fiberoptic bronchoscopy sampling for early diagnosis of smear negative or sputum-scarce patients with suspected tuberculosis, *BMC Pulm. Med.* 14 (2014) 137.
- [17] Y. Mok, T.Y. Tan, H.S. Wong, et al., Do we need transbronchial lung biopsy if we have bronchoalveolar lavage Xpert® MTB/RIF? *Int. J. Tubercul. Lung Dis.* 5 (2016) 619–624.
- [18] H.S. Kim, E.S. Lee, Y.J. Cho, Insufficient serum levels of antituberculosis agents during venovenous extracorporeal membrane oxygenation therapy for acute respiratory distress syndrome in a patient with miliary tuberculosis, *ASAIO J.* 60 (2014) 484–486.
- [19] K. Shekar, J.A. Roberts, C.I. McDonald, et al., Sequestration of drugs in the circuit may lead to therapeutic failure during extracorporeal membrane oxygenation, *Crit. Care* 16 (2012) R194.
- [20] C. Kurihara, J.M. Walter, B.D. Singer, et al., Extracorporeal membrane oxygenation can successfully support patients with severe acute respiratory distress syndrome in lieu of mechanical ventilation, *Crit. Care Med.* 48 (2018) e1070–e1073.
- [21] M.M. Hoepfer, O. Wiesner, J. Hadem, et al., Extracorporeal membrane oxygenation instead of invasive mechanical ventilation in patients with acute respiratory distress syndrome, *Intensive Care Med.* 39 (2013) 2056–2057.