

Review article

Aortic and Cerebral Aneurysms: Link with Genetic Predisposition, Risk Factors, and Aortopathies

Luka Švitek *¹, Nora Pušeljić *¹, Željka Breškić Ćurić², Kristina Selthofer-Relatić^{3,4}

*first authors

¹ Faculty of Medicine Osijek, Josip Juraj Strossmayer University of Osijek, Croatia² Department of Internal Medicine, General Hospital Vinkovci, Croatia³ Department of Cardiovascular Diseases, University Hospital Centre Osijek, Croatia⁴ Department of Internal Medicine, General Medicine and History of Medicine, Faculty of Medicine, Josip Juraj Strossmayer University of Osijek, CroatiaCorresponding author: Kristina Selthofer-Relatić, selthofer.relati@gmail.com

Abstract

Routine cardiology practice includes diagnostic algorithms for thoracic aortic aneurysm detection at varying degrees of clinical significance. Standard procedures for evaluation and follow up involve screening for standard atherosclerotic risk factors, including hypertension, dyslipidemia, diabetes mellitus, obesity, smoking history and family history without genetic testing, as well as cardiac imaging techniques, such as echocardiography, computed tomography or magnetic resonance imaging. According to the latest reports, thoracic aortic aneurysms can present concomitantly with intracranial aneurysms, although the exact etiopathogenic mechanisms are not yet known. There is evidence that connects these two conditions with genetic predisposition, risk factors, and aortopathies. Routine practice does not include screening for other aneurysm locations. This review will highlight existing knowledge in this area and the need for further investigations.

(Švitek L, Pušeljić N, Breškić Ćurić Ž, Selthofer-Relatić K. Aortic and Cerebral Aneurysms: Link with Genetic Predisposition, Risk Factors, and Aortopathies. SEEMEDJ 2019; 3(1); 29-41)

Received: March 24, 2019; revised version accepted: May 13, 2019; published: May 31, 2019

KEYWORDS: atherosclerosis, aortic aneurysm, genetics, inflammation, intracranial aneurysm

Introduction

An aneurysm is defined as a focal dilatation of the arterial wall. The cause and pathogenesis of aneurysms remain unknown. The initial arterial dilatation appears to be caused in part by degeneration of a portion of the arterial wall, often medial elastin, followed by smooth muscle. In recent years, there has been greater evidence regarding the concomitant incidence of intracranial aneurysms (IAs) and aortic aneurysms (AAs). The prevalence of unruptured IAs in the general population is estimated to be 3.2%. The prevalence of AAs, both thoracic aortic aneurysms (TAAs) and abdominal aortic aneurysms (AAAs), is around 1%–2% in the general population. The prevalence is higher in older populations at approximately 10% (1, 2).

The precise mechanisms of initiation, enlargement, or rupture of IAs, TAAs, and AAAs remain unknown. Biomechanical factors play fundamental roles in aneurysmatic development. An assessment of rupture potential should include geometry (shape and thickness), mechanical properties (anisotropy and strength), and applied loads (hemodynamic and perivascular), without primarily relying on maximum dimension. Early loss of elastin and subsequent loss of smooth muscle, with collagen structure change controlled by cellular responses as a result of hemodynamic and intramural stresses, can initiate thinning of the arterial wall and cause enlargement (3).

Congenital conditions, such as bicuspid aortic valve (BAV) and coarctation of the aorta (CoA), frequently occur with dilated aortic roots with a predisposition for aortic or cervical dissection. IAs are also more prevalent in patients with BAV or CoA, implying that IAs and aortic pathologies share a common developmental defect. The tunica media of both arteries has the same embryological origin, neural crest cells (NCCs), and a similar structure of cross-linked elastin and collagen (4, 5).

Another important and proposed pathway for aneurysm formation involves endothelial dysfunction and/or injury,

inflammation, vascular smooth muscle cell (SMC) response, extracellular matrix remodeling, vessel wall ageing, and degeneration with end-stage death (6). These processes are common with atherosclerosis etiopathogenesis to a degree, but their relationship with IAs and AAs is still unknown. The most recent epidemiological, clinical, and biological evidence suggests that atherosclerosis and IAs/TAAs are more distinct than traditionally thought (7).

This review will focus on the concomitant incidence of IAs and TAAs, their etiopathogenesis, risk factors, genetic predisposition, and aortopathies.

Artery – anatomy, histology, physiology and pathophysiology

Arteries are the main conductive blood vessels that deliver blood from the heart to all parts of the body. The arterial wall consists of three layers: a) intima – innermost layer, consisting of endothelial cells attached to a basement membrane composed of type IV collagen and laminin; b) media – middle layer, built from SMCs embedded in extracellular matrix composed of elastin, collagen, and proteoglycans; and c) adventitia – the outermost layer, consisting of fibroblasts and type I collagen with admixed elastin. The largest arteries contain the vasa vasorum, a network of small vessels that supply large blood vessels (3). The cells and matrix of each layer are built to provide a structural and functional support to blood vessel walls (6).

The main difference in the structure of systemic arterial vasculature is the composition of the tunica media. According to structure, arteries can be divided into elastic and muscular arteries. The common carotid artery is an elastic artery, while intracranial arteries are muscular arteries. The absence of an external elastic lamina makes intracranial arteries more vulnerable to aneurysmatic formation and rupture compared to other muscular arteries. Each arterial site may possess a different degree of durability and vulnerability as a result of

variance in pathophysiological signals, such as pressure increase (8).

Although it may occur in any blood vessel, the most common aneurysms according to location are aneurysms of the brain (Circle of Willis), TAAs, and AAAs (3). Also, arterial bifurcations are locus minoris resistentiae for cerebral aneurysm formations because of hemodynamic stress resulting from oscillations in blood flow (8). According to shape, aneurysms can be classified as saccular or fusiform aneurysms. The pathogenesis of aneurysm formation has not yet been clarified, but it is assumed that initial dilatation is first caused by elastin degeneration in the media, followed by smooth muscle degeneration (3).

Embryology

The vascular system starts its development early in the third week of gestation when the first blood islands first appear in the umbilical vesicle. Blood islands are composed of mesodermal cells that are induced by fibroblast growth factor (FGF2) to differentiate into hemangioblasts, which are then stimulated by vascular endothelial growth factor (VEGF), so they become endothelial cells and bind into the first blood vessels. This is the process of angiogenesis (9). Another way in which blood vessels develop is vasculogenesis, which can best be explained as sprouting from pre-existing ones. The earliest formed primitive blood vessel is the dorsal aorta, which soon after becomes surrounded by SMCs originating from the splanchnic mesoderm (10). Slightly later in development, primary SMCs derived from the splanchnic mesoderm are gradually replaced by a secondary population of SMCs originating from NCCs (11-13). The thoracic aorta almost fully replaces its primary SMCs with neural crest-derived SMCs (11). Conversely, the abdominal aorta retains its mesodermal-derived SMCs. SMCs derived from NCCs tend to produce a higher amount of elastin but at the same time express lower contractility function compared to those of mesodermal origin (14). Unique responses of NCCs to various cytokines and growth factors are firm evidence of the different

embryonic origins of the thoracic and abdominal aortas. Neural crest-derived SMCs from the thoracic aorta show increased DNA synthesis and collagen production by transforming growth factor- β 1 (TGF) as well as enhanced proliferation, along with synthetic activity, when stimulated by homocysteine. Contrary to that, mesodermal SMCs show no response to either of these (7, 8). Further support for these findings includes studies showing a causative link between the loss of signaling through TGF- β receptors I and II and development of familial TAAs and dissection (15-17). The proposed underlying cause for this kind of smooth muscle distribution in the aortic wall is that these neural crest-derived SMCs can better endure the higher pulse pressure in the thoracic aorta by laying down more elastic lamellae during development and growth (10).

The embryological link between the ascending aorta and the intracranial arteries lies precisely in the neural crest origin of SMCs. The cerebrovascular structures of the face and forebrain are derived from pericytes and the musculo-connective wall of arteries from NCCs (18). Malposition or malfunction during the perturbation of these cells (neurocristopathy) could be a plausible cause for the simultaneous occurrence of AAs and IAs (19). Considering the different embryological origins of SMCs, Shin et al. showed a site-specific relationship between aneurysms of the aorta and intracranial arteries. Ascending aortic aneurysms occur more commonly with aneurysms of the anterior and middle cerebral arteries, in contrast to AAAs, which occur more often with internal carotid artery aneurysms (20). Besides the development of vascular structures, NCCs play an important role in the development of head structures, skin melanocytes, a great part of the peripheral nervous system, some endocrine cells, and other structures (21, 22). Waldo et al. have contributed to the knowledge about the importance of NCCs in the septation of the truncus arteriosus (12). Co-occurrence of pathologies, such as a BAV (23), CoA (24), aortic root dilatation, cystic medial wall degeneration, and cervical arterial dissection (23) all fall into the category of neurocristopathy phenotypes (23).

24). Studies have also shown higher incidence of IAs in neurocristopathy diseases, such as neurofibromatosis type 1 (25), and diseases that are reminiscent of neurocristopathies, such as Moyamoya disease, fibromuscular dysplasia, and cervical dissection (26). Through these types of head, neck, and heart pathologies, the importance of the participation of NCCs in vascular remodeling is emphasized.

Genetic predisposition

Given the knowledge of the common embryonic origin, numerous studies have focused their genetic research on diseases related to neurocristopathy phenotype (Table 1, Figure 1).

Table 1. Gene mutations and clinical presentation on IAs², TAAs³ and AAAs⁴

MUTATIONS	CLINICAL REPERCUSSION	MOLECULAR LEVEL
Mutations in the genes encoding the TGFBR1 and TGFBR2 receptors	Loeys-Dietz syndrome	TGF- β^2 pathway
SMAD3 gene	Aneurysm osteoarthritis syndrome	TGF- β^1 pathway (a gene encoding a downstream signaling mediator TGF- β via the TGFBR1 and TGFBR2 receptors)
COL3A1 gene	Ehlers-Danlos syndrome type IV	TGF- β^1 pathway (a gene for the collagen type III pro α -1 chain)
PKD1 gene (85%), PKD2 gene (15%)	Autosomal dominant polycystic kidney disease	Polycystin-1 and polycystin-2, when healthy, likely work together to help regulate cell growth and division (proliferation), cell movement (migration), and interactions with other cells
3p24-25 and 5q for gene TGFBR2 and CSPG2 gene	Possible loci for IAs ³ and TAAs ⁴	TGF- β^1 pathway, pathology of the arterial wall
4q32-34	Effect on aneurysms of the abdominal aorta and intracranial vessels	
11q24	Significant role in all 3 sites of aneurysm formation	
19q	Effect on aneurysms of the abdominal aorta and intracranial vessels	
9p21, 2q33	Found in patients with IAs ² and AAAs ⁵	
18q11 and 15q21	Strong connection of IAs ² and TAAs ³ with AAAs ⁴	

² Transforming Growth Factor β

³ Intracranial Aneurysms

⁴ Thoracic Aortic Aneurysms

⁵ Abdominal Aortic Aneurysms

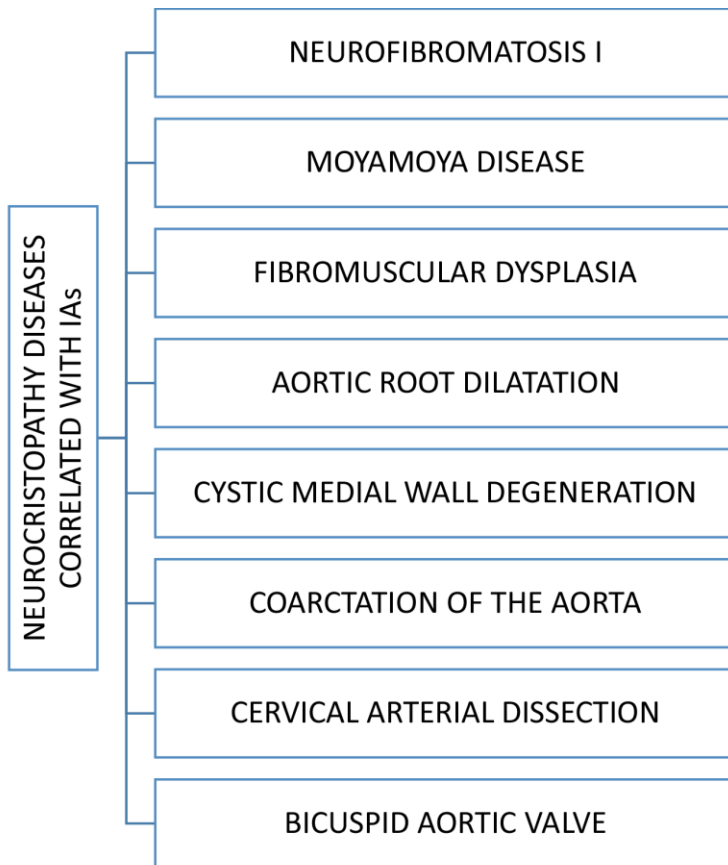


Figure 1. Correlation of IAs with neurocristopathy diseases

Pathology in the septation of heart outflow tracts, such as BAV, CoA, and dilated aortic root, was shown to co-occur with cerebral aneurysms (24, 27, 28). As evidence for the same pathological origin, a study done by Rosenquist et al. showed impaired initiation of elastogenesis in the great vessel walls after the ablation of NCCs (29).

Considering the existing knowledge in embryology about the importance of TGF- β signaling in the development of arterial walls, it is easy to understand that diseases with defects in the TGF- β pathway show a tendency of aneurysm development in multiple vascular beds. Loeys-Dietz syndrome (mutations in genes encoding the TGFBR1 and TGFBR2 receptors) (30), aneurysm-osteoarthritis syndrome (mutations in SMAD3, a gene encoding a downstream signaling mediator TGF- β via the TGFBR1 and TGFBR2 receptors) (31, 32), and Ehlers-Danlos syndrome type IV (mutations in the gene for the collagen type III

pro- α -1 chain [COL3A1]) are prone to forming both TAAs and IAs (33). Nurmonen et al. showed a higher occurrence of multiple IAs in patients with autosomal dominant polycystic kidney disease. Likewise, in terms of age of occurrence of aneurysmal subarachnoid hemorrhage, in people with IAs it occurs 10 years earlier than in the general population (34). A study of 669 patients with fibromuscular dysplasia showed a significantly higher prevalence of IAs (35).

Linkage studies of the entire genome carried out on predefined loci for three sites of aneurysm formation (intracranial, abdominal, and thoracic aorta) found five overlapping chromosomal regions at 3p24-25, 4q32-34, 5q, 11q24 and 19q. 3p24-25 and 5q for the CSPG2 gene are possible loci for IAs and TAAs. 3p24-25 is the locus for the TGFBR2 gene, which was already mentioned in relation to diseases affecting TGF- β signaling, while CSPG2 seems to have an effect on the pathology of the arterial wall as well. For the other regions, there is no known candidate gene yet, but 11q24 seems to have a significant role in all three sites of

aneurysm formation, while 4q32–34 and 19q have an effect on aneurysms of the abdominal aorta and intracranial vessels (36).

In 2016, a mega-analysis of four previously published aneurysm cohort studies was performed (two intracerebral aneurysm cohort studies from the Netherlands and Finland, an AAA cohort study from the Netherlands, and a TAA cohort study from the United States). It detected a single nucleotide polymorphism at four loci (9p21, 2q33, and two chromosomal regions, 18q11 and 15q21) which showed a strong connection between IAs and TAAs with AAAs (37). In a study by Shin et al., while searching for evidence of innate aortopathy in patients with IAs, the scientists noticed that short stature was common among the respondents (24). The aforementioned NCCs have a number of roles outside the development of the vascular system, including a role in the development of the pituitary, which can have an effect on the growth of bone and cartilage (21, 38). Further research on other potential, unknown causes could highlight this problem and provide new insights in this area.

Atherosclerosis

Atherosclerosis correlates with arterial aneurysmatic occurrence. It is still unknown if it is a causal relationship, or if they share common risk factors (39). Most studies agree that atherosclerosis is mainly correlated with AAAs, but not with TAAs and IAs (3, 39-41). There is a shared genetic background for both AAAs and atherosclerosis (39, 42, 43), as well as common risk factors, including hypertension, obesity, smoking, HDL, family history, and thrombosis (2, 20, 42, 44-51). On the other hand, some markers differ, such as LDL (no correlation with AAAs) and diabetes (negative correlation with AAAs) (42, 50, 51).

There is no conclusive evidence about the correlation between the development of IAs and atherosclerosis. Rouchaud et al. showed that there is no correlation between atherosclerosis and IAs (46). Wang et al. even asserted that atherosclerosis is a protective factor against IA rupture (52), while Hokari et al.

suggested that middle cerebral artery aneurysms positively correlate with hypertension and cerebrovascular disease, which are common comorbidities in patients with atherosclerosis and have a higher incidence in stroke patients (41). Another type of IAs, paraclinoid aneurysms, were also the subject of the same study. Paraclinoid aneurysms are defects of an internal carotid artery wall that are located between the superior part of cavernous sinus and the entrance for the posterior communicating artery (53), detected with three dimensional time-of-flight magnetic resonance angiography (3D TOF MRA) in stroke patients, as well as in healthy adults volunteering for asymptomatic brain disease evaluation (41). The results showed that paraclinoid aneurysms have a lower incidence in stroke patients than in healthy research participants (41). Likewise, paraclinoid aneurysms are more affected by hemodynamic stress and unchangeable risk factors than middle cerebral artery aneurysms (54). These results might not mean that IAs are "immune to atherosclerotic risk factors", but just that they are not equally affected regarding the localization.

Inflammation

Genetics, hemodynamic changes, and environmental factors are the main factors in aneurysm development. In recent years, there has been considerable evidence for inflammation as a leading factor in the pathogenesis of IAs (6, 39, 55).

Initially, in response to hemodynamic stress, development of endothelial dysfunction is followed by an inflammatory reaction. Macrophages release proinflammatory cytokines that lead to recruitment of additional inflammatory cells and release matrix metalloproteinases (MMPs), which cause degradation of the extracellular matrix and activate other proteinases (55). According to a study by Aoki et al., mice with lower expression of monocyte chemoattractant protein-1 (MCP-1) and decreased accumulation of macrophages had a lower risk of developing cerebral aneurysms (56). Likewise, according to another

study by Aoki et al., the application of MMP inhibitor in rats reduced the progression of IAs (57).

MMPs cause apoptosis of SMCs, which are mostly concentrated in the media, leading to the thinning of this layer. Tumor necrosis factor- α (TNF- α) modulates SMCs by inhibiting collagen synthesis, which is a predisposition for aneurysm formation, progression, and rupture (55). T cells, mast cells, and cytokines also participate in inflammation and aneurysm formation (8). TNF- α and interleukin-6 (IL-6) are the best explored cytokines involved in the development of inflammation and aneurysm formation. Complement activation has been found in patients with IAs, but it is still necessary to explain how it contributes to aneurysm formation (58).

According to a study by Shikata et al., intestinal microbiota in mice can affect the formation of IAs by modulating inflammation

through depletion of macrophage infiltration and lowering of inflammatory cytokine levels in blood vessel walls (59).

Understanding all aspects of the role that inflammation plays in the formation of aneurysms is essential because there are many sites that can potentially present target sites for pharmacological treatment of aneurysms. Some agents were studied for inhibiting aneurysm development, such as statins, aspirin, and inhibitor of phosphodiesterase-4 (Ibutilast), but their role in the treatment has not yet been conclusively proved (6).

Aorthopathy

According to recent evidence, there are correlations between IAs and AAs, especially TAAs, which are based on an aorthopathy of a different cause (Figure 2) (4, 5, 20, 46, 47, 60, 61).

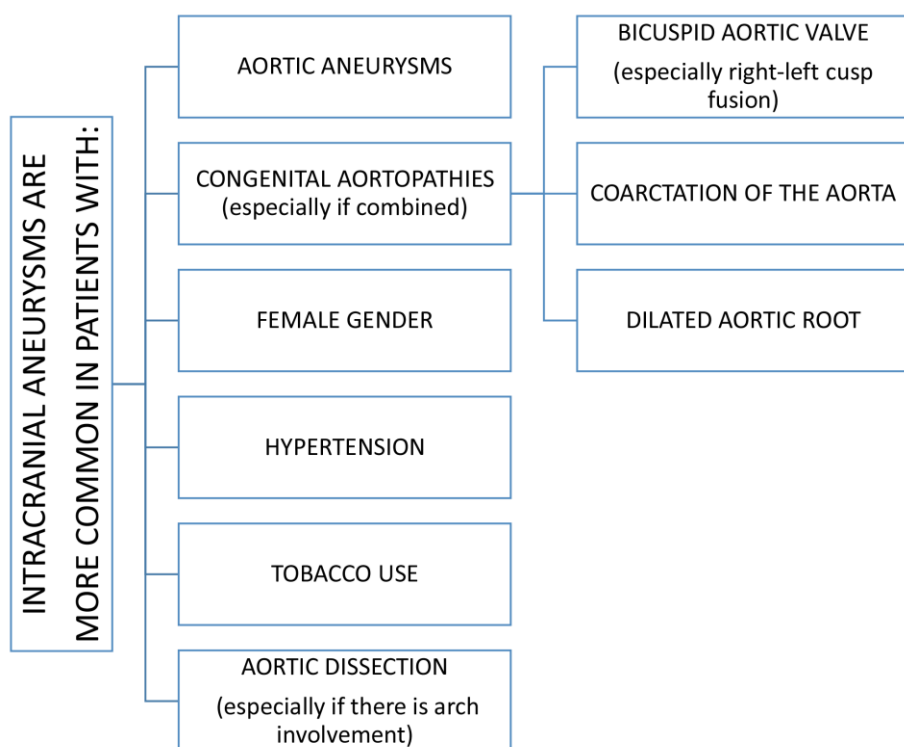


Figure 2. Algorithm for relation of IAs with risk factors and aortopathies

Regarding the prevalence of IAs, studies have shown similarities in groups of patients already known to suffer from AAs (4, 5, 20, 46). Rouchaud et al. conducted a study on 1081 patients with AAs and found the prevalence of IAs to be 11.8% (46). Likewise, Shin et al. carried out a study on 611 patients with AAs and showed the prevalence of IAs to be 11.6% (20). In addition, Jung et al. searched for IAs in patients with dissecting AAs, and the prevalence was 13% (4). Furthermore, research by Kuzmik et al. conducted on 212 patients with TAAs showed a prevalence of 9.0% for IAs (60). These results show a much greater prevalence of IAs in patients with AAs, with the rate of IAs four times higher in patients who also have AAs (4, 20, 46) than in the general population.

TAAs and IAs do not correlate with atherosclerotic risk factors (2, 20, 45-49). Research by Rouchaud et al. showed that coronary artery disease and hyperlipidemia actually lowered the odds of IAs (46). Multiple aneurysms in patients with IAs occur in 15–45% (5, 62, 63) of cases, which may suggest that another underlying cause increases susceptibility to aneurysms.

Another study by Shin et al. focused on congenital aortopathy. They identified the presence of BAV and CoA (5), already known conditions that are connected with greater prevalence of IAs (64-66). These are conditions that are usually associated with a dilated aortic root (5). The study showed that a group of people older than 55 who had large IAs (more than 7 mm in diameter), multiple aneurysms, or ruptured aneurysms had a significantly higher prevalence of dilated aortic roots (5). Another group in this study consisted of patients without the high-risk factors mentioned for the first group (5). The second group had a significantly higher percentage of cerebrovascular risk factors, such as hypertension, diabetes mellitus, and hyperlipidemia, as well as strokes (5). Similarly, a study by Egbe et al. conducted on 678 patients with BAV showed an IA prevalence of 7.7% (66). In this study, the prevalence of IAs in patients with both BAV and CoA was 12.9% (66). In addition, the presence of right-left cusp fusion in patients with BAV was found to be a significant

risk factor for developing IAs (66). A study by Schievnik et al. conducted on patients with BAV found that 9.8% of patients had IAs (65). In a study of 117 patients with CoA, Curtis et al. found the prevalence of IAs to be 10.3% (48). A similar study by Connolly et al. conducted on 100 patients with CoA determined that 10.0% of patients had IAs (64).

Aortic dissection is another condition that has been studied to evaluate its co-occurrence with IAs. As mentioned above, a study by Rouchaud et al. conducted on 71 patients found the prevalence of IAs to be 13% in patients with dissections (4). That is about four times higher than in the general population (4). These patients had hypertension and a history of cerebrovascular disease in numbers significantly higher than in the control group (4). This study found a significant correlation between the presence of IAs and the arch involvement seen in aortic dissection (4).

An additional important variable with influence on IA formation in patients with AAs is gender (4, 5, 20, 46). A few studies have shown that women are more prone to aneurysms compared to men (20, 46, 66), but this finding requires further research.

Conclusion

According to available data in the areas of genetics, pathophysiologic findings, risk factors, and aortopathies, there are strong relationships and predispositions for concomitant aneurysmatic formation in different loci. The embryological link between the ascending aorta and the intracranial arteries lies in the origin of SMCs or NCCs. At the developmental level, the septation of heart outflow tracts, such as a BAV, CoA, and dilated aortic root, is in direct relation with IAs as a result of impaired initiation of elastogenesis. Atherosclerosis is not a unique risk factor for IAs and TAAs, but is directly related to AAAs as well.

There are still many unanswered questions in this area in regard to the following: a) genetic predisposition; b) structural and mechanical properties: the extensive

differences in histology and pathophysiology, the cause of different shapes of IAs (saccular) and TAAs (fusiform), and difference between vessel wall structures; c) epidemiological risk factors between these three conditions (IAs, TAAs, and AAAs); d) gender differences; e) the impact of ageing; f) the need for further research and gene detection.

Co-occurrence of aortic and cerebral aneurysms exists in multiple conditions. It is not

likely that a single genetic disorder will be found to explain the co-occurrence of both aneurysm sites. When it comes to explaining this complex dual pathology, the most probable pathophysiological explanation is that several levels of genetic defects, plus a multifactorial environmental effect, result in arterial wall weakening and the formation of aneurysms in multiple locations.

References

1. Svensjo S, Bjorck M, Gurtelschmid M, Djavani Gidlund K, Hellberg A, Wanhainen A. Low prevalence of abdominal aortic aneurysm among 65-year-old Swedish men indicates a change in the epidemiology of the disease. *Circulation*. 2011;124(10):1118-23.
2. Vlak MH, Algra A, Brandenburg R, Rinkel GJ. Prevalence of unruptured intracranial aneurysms, with emphasis on sex, age, comorbidity, country, and time period: a systematic review and meta-analysis. *The Lancet Neurology*. 2011;10(7):626-36.
3. Humphrey JD, Taylor CA. Intracranial and abdominal aortic aneurysms: similarities, differences, and need for a new class of computational models. *Annual review of biomedical engineering*. 2008;10:221-46.
4. Jung WS, Kim JH, Ahn SJ, Song SW, Kim BM, Seo KD, et al. Prevalence of Intracranial Aneurysms in Patients with Aortic Dissection. *AJNR American journal of neuroradiology*. 2017;38(11):2089-93.
5. Shin YW, Jung KH, Kim JM, Cho YD, Lee ST, Chu K, et al. Echocardiographic evidence of innate aortopathy in the human intracranial aneurysm. *PloS one*. 2014;9(6):e100569.
6. Chalouhi N, Ali MS, Jabbour PM, Tjoumakaris SI, Gonzalez LF, Rosenwasser RH, et al. Biology of intracranial aneurysms: role of inflammation. *Journal of cerebral blood flow and metabolism : official journal of the International Society of Cerebral Blood Flow and Metabolism*. 2012;32(9):1659-76.
7. Toghiani BJ, Saratzis A, Bown MJ. Abdominal aortic aneurysm-an independent disease to atherosclerosis? *Cardiovascular pathology : the official journal of the Society for Cardiovascular Pathology*. 2017;27:71-5.
8. Jung KH. New Pathophysiological Considerations on Cerebral Aneurysms. *Neurointervention*. 2018;13(2):73-83.
9. Sadler TW, Kostovic-Knezevic L, Bradamante Z, Svajger A. *Langmanova medicinska embriologija : prijevod americkog izdanja*. Zagreb: Skolska knjiga; 1996.
10. Kuivaniemi H, Ryer EJ, Elmore JR, Tromp G. Understanding the pathogenesis of abdominal aortic aneurysms. *Expert review of cardiovascular therapy*. 2015;13(9):975-87.
11. Wiegrefe C, Christ B, Huang R, Scaal M. Remodeling of aortic smooth muscle during avian embryonic development. *Developmental*

- dynamics : an official publication of the American Association of Anatomists. 2009;238(3):624-31.
12. Kirby ML, Gale TF, Stewart DE. Neural crest cells contribute to normal aorticopulmonary septation. *Science (New York, NY)*. 1983;220(4601):1059-61.
 13. Le Lievre CS, Le Douarin NM. Mesenchymal derivatives of the neural crest: analysis of chimaeric quail and chick embryos. *Journal of embryology and experimental morphology*. 1975;34(1):125-54.
 14. Jung K-H. New Pathophysiological Considerations on Cerebral Aneurysms. *Neurointervention*. 2018;13(2):73-83.
 15. Pannu H, Fadulu VT, Chang J, Lafont A, Hasham SN, Sparks E, et al. Mutations in transforming growth factor-beta receptor type II cause familial thoracic aortic aneurysms and dissections. *Circulation*. 2005;112(4):513-20.
 16. Matyas G, Arnold E, Carrel T, Baumgartner D, Boileau C, Berger W, et al. Identification and in silico analyses of novel TGFBR1 and TGFBR2 mutations in Marfan syndrome-related disorders. *Human mutation*. 2006;27(8):760-9.
 17. Hasham SN, Willing MC, Guo DC, Muilenburg A, He R, Tran VT, et al. Mapping a locus for familial thoracic aortic aneurysms and dissections (TAAD2) to 3p24-25. *Circulation*. 2003;107(25):3184-90.
 18. Etchevers HC, Vincent C, Le Douarin NM, Couly GF. The cephalic neural crest provides pericytes and smooth muscle cells to all blood vessels of the face and forebrain. *Development (Cambridge, England)*. 2001;128(7):1059-68.
 19. Rouchaud A, Brandt MD, Rydberg AM, Kadirvel R, Flemming K, Kallmes DF, et al. Prevalence of Intracranial Aneurysms in Patients with Aortic Aneurysms. 2016;37(9):1664-8.
 20. Shin YW, Jung KH, Moon J, Lee ST, Lee SK, Chu K, et al. Site-Specific Relationship Between Intracranial Aneurysm and Aortic Aneurysm. *Stroke*. 2015;46(7):1993-6.
 21. Dupin E, Sommer L. Neural crest progenitors and stem cells: From early development to adulthood 2012. 83-95 p.
 22. Noden D, Poelmann R, Gittenberger-de Groot AC. Cell origins and tissue boundaries during outflow tract development 1995. 69-75 p.
 23. Schievink Wouter I, Mokri B. Familial Aorto-Cervicocephalic Arterial Dissections and Congenitally Bicuspid Aortic Valve. *Stroke*. 1995;26(10):1935-40.
 24. Shin Y-W, Jung K-H, Kim J-M, Cho YD, Lee S-T, Chu K, et al. Echocardiographic evidence of innate aortopathy in the human intracranial aneurysm. *PLoS one*. 2014;9(6):e100569-e.
 25. Schievink W, Riedinger M, Maya M. Frequency of incidental intracranial aneurysms in neurofibromatosis type 1 2005. 45-8 p.
 26. Southerland AM, Meschia JF, Worrall BB. Shared associations of nonatherosclerotic, large-vessel, cerebrovascular arteriopathies: considering intracranial aneurysms, cervical artery dissection, moyamoya disease and fibromuscular dysplasia. 2013;26(1):13-28.
 27. Connolly HM, Huston J, Brown RD, Warnes CA, Ammash NM, Tajik AJ. Intracranial Aneurysms in Patients With Coarctation of the Aorta: A

- Prospective Magnetic Resonance Angiographic Study of 100 Patients. Mayo Clinic Proceedings. 2003;78(12):1491-9.
28. Schievink WI, Raissi SS, Maya MM, Velebir A. Screening for intracranial aneurysms in patients with bicuspid aortic valve. *Neurology*. 2010;74(18):1430.
 29. Rosenquist TH, Beall AC, Modis L, Fishman R. Impaired elastic matrix development in the great arteries after ablation of the cardiac neural crest. *The Anatomical record*. 1990;226(3):347-59.
 30. Loeys BL, Schwarze U, Holm T, Callewaert BL, Thomas GH, Pannu H, et al. Aneurysm syndromes caused by mutations in the TGF-beta receptor. *The New England journal of medicine*. 2006;355(8):788-98.
 31. van de Laar IM, van der Linde D, Oei EH, Bos PK, Bessems JH, Bierma-Zeinstra SM, et al. Phenotypic spectrum of the SMAD3-related aneurysms-osteoarthritis syndrome. *Journal of medical genetics*. 2012;49(1):47-57.
 32. van de Laar IMBH, Oldenburg RA, Pals G, Roos-Hesselink JW, de Graaf BM, Verhagen JMA, et al. Mutations in SMAD3 cause a syndromic form of aortic aneurysms and dissections with early-onset osteoarthritis. *Nature Genetics*. 2011;43:121.
 33. Schievink W. Cerebrovascular Involvement in Ehlers-Danlos Syndrome 2004. 231-6 p.
 34. Nurmonen HJ, Huttunen T, Huttunen J, Kurki MI, Helin K, Koivisto T, et al. Polycystic kidney disease among 4,436 intracranial aneurysm patients from a defined population. *Neurology*. 2017;89(18):1852-9.
 35. Lather HD, Gornik HL, Olin JW, Gu X, Heidt ST, Kim ESH, et al. Prevalence of Intracranial Aneurysm in Women With Fibromuscular Dysplasia: A Report From the US Registry for Fibromuscular Dysplasia. *JAMA neurology*. 2017;74(9):1081-7.
 36. Ruigrok YM, Elias R, Wijmenga C, Rinkel GJ. A comparison of genetic chromosomal loci for intracranial, thoracic aortic, and abdominal aortic aneurysms in search of common genetic risk factors. *Cardiovascular pathology : the official journal of the Society for Cardiovascular Pathology*. 2008;17(1):40-7.
 37. van 't Hof FNG, Ruigrok YM, Lee CH, Ripke S, Anderson G, de Andrade M, et al. Shared Genetic Risk Factors of Intracranial, Abdominal, and Thoracic Aneurysms. *Journal of the American Heart Association*. 2016;5(7):e002603.
 38. Etchevers H, Vincent C, Couly G. Neural Crest and Pituitary Development. 2001. p. 180.
 39. Golledge J, Norman PE. Atherosclerosis and abdominal aortic aneurysm: cause, response, or common risk factors? *Arteriosclerosis, thrombosis, and vascular biology*. 2010;30(6):1075-7.
 40. Agmon Y, Khandheria BK, Meissner I, Schwartz GL, Sicks JD, Fought AJ, et al. Is aortic dilatation an atherosclerosis-related process? Clinical, laboratory, and transesophageal echocardiographic correlates of thoracic aortic dimensions in the population with implications for thoracic aortic aneurysm formation. *Journal of the American College of Cardiology*. 2003;42(6):1076-83.
 41. Hokari M, Isobe M, Imai T, Chiba Y, Iwamoto N, Isu T. The impact of atherosclerotic factors on cerebral

- aneurysm is location dependent: aneurysms in stroke patients and healthy controls. *Journal of stroke and cerebrovascular diseases : the official journal of National Stroke Association*. 2014;23(9):2301-7.
42. Golledge J, Muller J, Daugherty A, Norman P. Abdominal aortic aneurysm: pathogenesis and implications for management. *Arteriosclerosis, thrombosis, and vascular biology*. 2006;26(12):2605-13.
 43. Helgadottir A, Thorleifsson G, Magnusson KP, Gretarsdottir S, Steinthorsdottir V, Manolescu A, et al. The same sequence variant on 9p21 associates with myocardial infarction, abdominal aortic aneurysm and intracranial aneurysm. *Nature genetics*. 2008;40(2):217-24.
 44. Norman PE, Powell JT. Site specificity of aneurysmal disease. *Circulation*. 2010;121(4):560-8.
 45. Rinkel GJ, Djibuti M, Algra A, van Gijn J. Prevalence and risk of rupture of intracranial aneurysms: a systematic review. *Stroke*. 1998;29(1):251-6.
 46. Rouchaud A, Brandt MD, Rydberg AM, Kadirvel R, Flemming K, Kallmes DF, et al. Prevalence of Intracranial Aneurysms in Patients with Aortic Aneurysms. *AJNR American journal of neuroradiology*. 2016;37(9):1664-8.
 47. Southerland AM, Meschia JF, Worrall BB. Shared associations of nonatherosclerotic, large-vessel, cerebrovascular arteriopathies: considering intracranial aneurysms, cervical artery dissection, moyamoya disease and fibromuscular dysplasia. *Current opinion in neurology*. 2013;26(1):13-28.
 48. Curtis SL, Bradley M, Wilde P, Aw J, Chakrabarti S, Hamilton M, et al. Results of screening for intracranial aneurysms in patients with coarctation of the aorta. *AJNR American journal of neuroradiology*. 2012;33(6):1182-6.
 49. Golledge J, Tsao PS, Dalman RL, Norman PE. Circulating markers of abdominal aortic aneurysm presence and progression. *Circulation*. 2008;118(23):2382-92.
 50. Golledge J, Biros E, Cooper M, Warrington N, Palmer LJ, Norman PE. Apolipoprotein E genotype is associated with serum C-reactive protein but not abdominal aortic aneurysm. *Atherosclerosis*. 2010;209(2):487-91.
 51. Golledge J, van Bockxmeer F, Jamrozik K, McCann M, Norman PE. Association between serum lipoproteins and abdominal aortic aneurysm. *The American journal of cardiology*. 2010;105(10):1480-4.
 52. Wang GX, Zhang D, Wang ZP, Yang LQ, Yang H, Li W. Risk factors for ruptured intracranial aneurysms. *The Indian journal of medical research*. 2018;147(1):51-7.
 53. De Jesus O, Sekhar LN, Riedel CJ. Clinoid and paraclinoid aneurysms: surgical anatomy, operative techniques, and outcome. *Surgical neurology*. 1999;51(5):477-87; discussion 87-8.
 54. Indo M, Oya S, Tanaka M, Matsui T. High incidence of ICA anterior wall aneurysms in patients with an anomalous origin of the ophthalmic artery: possible relevance to the pathogenesis of aneurysm formation. *Journal of neurosurgery*. 2014;120(1):93-8.
 55. Chalouhi N, Hoh BL, Hasan D. Review of cerebral aneurysm formation, growth, and rupture. *Stroke*. 2013;44(12):3613-22.

56. Aoki T, Kataoka H, Ishibashi R, Nozaki K, Egashira K, Hashimoto N. Impact of monocyte chemoattractant protein-1 deficiency on cerebral aneurysm formation. *Stroke*. 2009;40(3):942-51.
57. Aoki T, Kataoka H, Morimoto M, Nozaki K, Hashimoto N. Macrophage-derived matrix metalloproteinase-2 and -9 promote the progression of cerebral aneurysms in rats. *Stroke*. 2007;38(1):162-9.
58. Tulamo R, Frosen J, Junnikkala S, Paetau A, Pitkaniemi J, Kangasniemi M, et al. Complement activation associates with saccular cerebral artery aneurysm wall degeneration and rupture. *Neurosurgery*. 2006;59(5):1069-76; discussion 76-7.
59. Shikata F, Shimada K, Sato H, Ikedo T, Kuwabara A, Furukawa H, et al. Potential Influences of Gut Microbiota on the Formation of Intracranial Aneurysm. *Hypertension*. 2019;73(2):491-6.
60. Kuzmik GA, Feldman M, Tranquilli M, Rizzo JA, Johnson M, Elefteriades JA. Concurrent intracranial and thoracic aortic aneurysms. *The American journal of cardiology*. 2010;105(3):417-20.
61. Miyazawa N, Akiyama I, Yamagata Z. Risk factors for the association of intracranial and aortic aneurysms. *Acta neurochirurgica*. 2007;149(3):221-9; discussion 9.
62. Nehls DG, Flom RA, Carter LP, Spetzler RF. Multiple intracranial aneurysms: determining the site of rupture. *Journal of neurosurgery*. 1985;63(3):342-8.
63. Rinne J, Hernesniemi J, Puranen M, Saari T. Multiple intracranial aneurysms in a defined population: prospective angiographic and clinical study. *Neurosurgery*. 1994;35(5):803-8.
64. Connolly HM, Huston J, 3rd, Brown RD, Jr., Warnes CA, Ammass NM, Tajik AJ. Intracranial aneurysms in patients with coarctation of the aorta: a prospective magnetic resonance angiographic study of 100 patients. *Mayo Clinic proceedings*. 2003;78(12):1491-9.
65. Schievink WI, Raissi SS, Maya MM, Velebir A. Screening for intracranial aneurysms in patients with bicuspid aortic valve. *Neurology*. 2010;74(18):1430-3.
66. Egbe AC, Padang R, Brown RD, Khan AR, Luis SA, Huston J, 3rd, et al. Prevalence and predictors of intracranial aneurysms in patients with bicuspid aortic valve. *Heart*. 2017;103(19):1508-14.