

## The role of multimodality imaging in clinical decision-making of the heart team in complex aortic root reconstruction due to endocarditis

 Dubravka Šušnjar<sup>1,\*</sup>,

 Sandra Jakšić Jurinjak<sup>1</sup>,

 Boris Starčević<sup>1,2</sup>,

 Josip Varvodić<sup>1</sup>,

 Davor Barić<sup>1</sup>,

 Daniel Unić<sup>1</sup>,

 Robert Blažeković<sup>1</sup>,

 Igor Rudež<sup>1,2</sup>

<sup>1</sup>University Hospital Dubrava  
Zagreb, Croatia

<sup>2</sup>University of Zagreb School  
of Medicine, Zagreb, Croatia

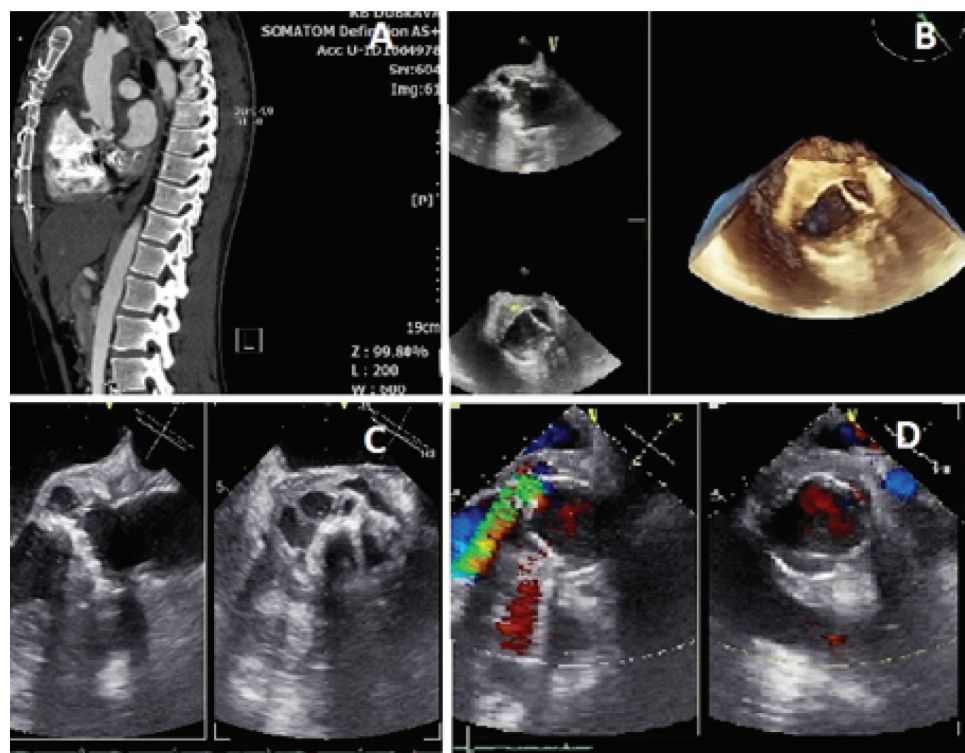
**KEYWORDS:** aortic root reconstruction, aortic valve insufficiency, endocarditis.

**CITATION:** *Cardiol Croat.* 2019;14(3-4):78-9. | <https://doi.org/10.15836/ccar2019.78>

**\*ADDRESS FOR CORRESPONDENCE:** Dubravka Šušnjar, Klinička bolnica Dubrava, Av. Gojka Šuška 6, HR-10000, Zagreb, Croatia. / Phone: +385-99-290-4019 / E-mail: [dubravka.susnjar@gmail.com](mailto:dubravka.susnjar@gmail.com)

**ORCID:** Dubravka Šušnjar, <https://orcid.org/0000-0002-9644-9739> • Sandra Jakšić Jurinjak, <https://orcid.org/0000-0002-7349-6137> • Boris Starčević, <https://orcid.org/0000-0002-3090-2772> • Josip Varvodić, <https://orcid.org/0000-0001-6602-699X> • Davor Barić, <https://orcid.org/0000-0001-5955-0275> • Daniel Unić, <https://orcid.org/0000-0003-2740-4067> • Robert Blažeković, <https://orcid.org/0000-0001-7125-361X> • Igor Rudež, <https://orcid.org/0000-0002-7735-6721>

**Case report:** 29-year-old male underwent aortic root reconstruction with root remodeling technique and external ring annuloplasty (Corneo Extra Aortic Ring A 29, Gelweave graft 30 mm) in 2015 due to bicuspid aortic valve with significant aortic regurgitation and aortic root dilatation. In 2017 due to pseudoaneurysm of aortic root and severe aortic regurgitation, the patient was reoperated and mechanical aortic valve was implanted (Carbomedics Mechanical A 25) with patch plastic of the pseudoaneurysm. A year later he was admitted again, now due to fever and high inflammatory markers. Multimodality imaging, transthoracic echocardiography, transesophageal echocardiography, MSCT aortography and abdominal CT described aortic /perivalvular root abscess with significant paravalvular leak in terms of hemodynamically significant regurgitation with high flow velocity over the mechanical valve, peak velocity > 4 m/s. TEE (2D+3D) showed the septate hyperechogenic formation with hypoechogenic cavities which seemed to touch a part of trigonum, approximately 15 mm thick, extending from annulus ascending to the entire visible part of the aortic root, ascending more than 4 cm. It appeared to affect > 50% of the annulus, with visible paraannular leak and massive aortic regurgitation. Previously implanted patch plastic on aortic root was hypermobile depending on heart cycle. Left ventricle showed normal contractility. MSCT of thorax and aortography confirmed the finding (**Figure 1**). The patient



**FIGURE 1.** A MSCT aortography showing complex aortic root abscess, B 3D TEE of aortic root showing patch plastic protruding into aortic lumina, C, D multiplane transoesophageal echocardiography showing paraannular aortic abscess with paraannular regurgitant jet.

RECEIVED:  
February 28, 2019

ACCEPTED:  
March 24, 2019



