

PENETRATING ORBITOCRANIAL INJURY

Marisa Klančnik¹, Petar Ivanišević¹, Slaven Lupi-Ferandin², Ante Sučić¹, Vlatko Ledenko³,
Mladen Lešin⁴, Marina Krnić Martinić¹ and Ljubica Kuščić-Juretić⁵

¹University of Split, Split University Hospital Center, Department of Otorhinolaryngology, Split, Croatia;

²University of Split, Split University Hospital Center, Department of Maxillofacial Surgery, Split, Croatia;

³University of Split, Split University Hospital Center, Department of Neurosurgery, Split, Croatia;

⁴University of Split, Split University Hospital Center, Department of Ophthalmology, Split, Croatia;

⁵University of Split, Split University Hospital Center, Department of Nuclear Medicine, Split, Croatia

SUMMARY – A case of a 37-year-old female patient is presented. The patient was admitted to the Surgical Emergency Unit after accidental fall on a metal rod when she had sustained stab injury of the right orbit with penetration into the right frontal brain lobe. Multi-slice computed tomography (MSCT) showed penetrating injury and fracture of the right orbital roof without eyeball damage and endocranial impressed bone fragments into the right frontal brain lobe. Urgent surgical intervention was performed by a maxillofacial surgeon and neurosurgeon, including reposition of bone fragments of the orbital roof and cranioplasty. Reconstruction of Tenon's capsule of the right eyeball was performed by an ophthalmologist. From the intraoperative wound swab of the orbit, *Bacillus cereus* was isolated, therefore the patient was administered ciprofloxacin and rifampicin as recommended by an infectious disease (ID) specialist. Follow up brain MSCT at 15 days and magnetic resonance imaging of the brain at 25 days showed brain edema in the right frontal area and signs of local brain abscess. Intravenous administration of the ciprofloxacin and metronidazole antibiotics with corticosteroids for edema suppression were ordered by the ID physician. Fourteen weeks after this therapy, brain MSCT showed complete abscess regression and no neurologic deficit with only mild psychomotor changes.

Key words: *Case reports; Head injuries, penetrating; Eye injuries, penetrating; Orbit; Brain edema*

Introduction

Penetrating orbitocranial injuries are very rare in the civilian population and account for only 0.4% of all head injuries but with a high mortality rate¹⁻³. These injuries are also present in war. In a large series of 351 head injuries in the Vietnam War, orbital penetration was noted in 0.6% of cases⁴. In 1999 in Udampur, 60 patients with missile injuries of the head were admitted to the Command Hospital (Northern Command); orbitocranial/faciocranial injuries with penetration were found in 25% of patients⁵.

Penetrating orbital injuries can cause heavy brain damages *via* orbital roof, superior orbital fissure and optical nerve³. Intracranial complications can lead to temporary or permanent neurologic deficits and vascular complications such as hemorrhage, thrombosis, or occlusion^{2,3}. Laceration of the eyeball, retrobulbar hematoma, proptosis and damage to the optic nerve with visual impairment can occur. The most common complication is infection, which mostly appears subsequently³.

Penetrating injuries caused by high velocity objects, following a trajectory perpendicular to the orbital wall, result in direct bone fractures. Vertically directed objects may pierce the orbital roof and cause damage to the frontal lobe. Horizontally directed penetrating objects may cause ethmoid bone or posterior orbital wall fractures. The most frequent pattern of injury (68%)

Correspondence to: *Petar Ivanišević, MD*, University of Split, Split University Hospital Center, Department of Otorhinolaryngology, Spinčićeva 1, HR-21000 Split, Croatia
E-mail: pivanisevic@kbsplit.hr

Received April 13, 2017, accepted November 21, 2017

involves the cavernous sinus, temporal lobe, and brainstem. In low velocity injuries, when the penetrating object hits the orbit at a small angle, the object follows a path along the wall of the orbit. Penetrating objects, entering the orbit close to the horizontal plane, tend to follow the orbital funnel towards the apex⁶.

A case of a 37-year-old female patient is presented, who had fallen on a metal rod and sustained injury of the right orbit with penetration into the right frontal brain lobe.

Case Report

After accidental fall on a metal rod in the field, the 37-year-old female patient had sustained orbital and intracranial penetrating wound. The wire, a concrete wall wire mesh, was 8 mm in diameter and the patient had taken it out immediately. The patient did not lose consciousness, but vomited twice.

Initial multi-slice computed tomography (MSCT) performed at another medical institution showed penetrating wound of the right orbital roof without affection of the right bulb, and endocranial impressed bone fragments into the right frontal brain lobe with pneumocephalus and minimum hemorrhage (Figs. 1 and 2). There were no signs of brain edema, but proptosis, ptosis and leakage of the cerebrospinal fluid from conjunctival lesion were observed.

Upon arrival to the Surgical Emergency Unit, Split University Hospital Center, the patient was conscious, contacted easily, carried out orders without any sign of lateralization, and Glasgow coma scale score was 15. There was significant but localized edema of both right eyelids, less pronounced in the left periorbital area, and painful terminal neck flexion with correct x-ray of the neck spine (Fig. 3). Follow up MSCT of the brain, obtained at the Split University Hospital Center, showed stationary finding without any signs of intracranial complication.

The care of the patient was interdisciplinary. An ophthalmologist performed debridement of conjunctiva laceration and reconstruction of Tenon's capsule of the right eye bulb. A neurosurgeon and maxillofacial surgeon performed supraorbital right-side 'key hole' craniotomy, through which bone fragments of the orbital roof were replaced and fixed (Fig. 4). Defect of the dura was closed by Tachosil and fibrin glue. Cranioplasty was performed by titanium net.

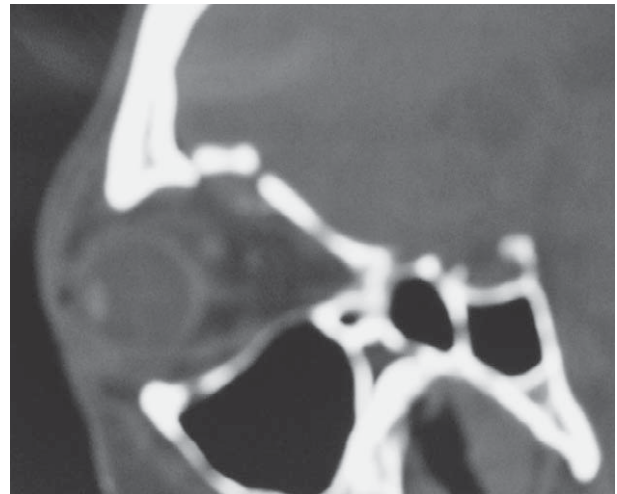


Fig. 1. Computed tomography of the brain (anteroposterior projection) showing perforating wound of the right orbital roof without affection of the right bulb, and endocranial impressed bone fragments into the right frontal brain lobe.

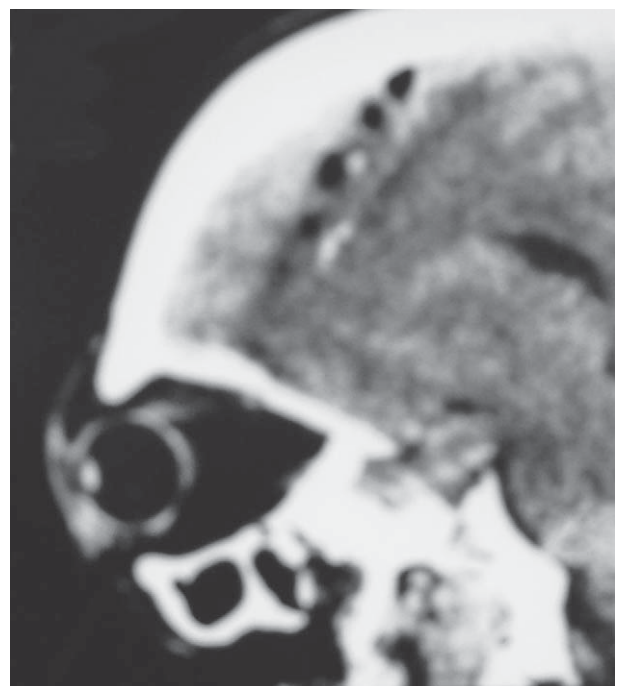


Fig. 2. Computed tomography of the brain (lateral projection) showing frontal brain lobe with pneumocephalus and minimum hemorrhage.

Bacillus cereus was isolated in the intraoperative microbiological sample of the orbit area and the patient was administered oral therapy with a combination of ciprofloxacin 2x500 mg and rifampicin 2x300 mg.

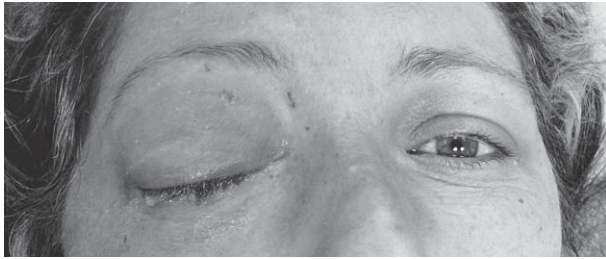

Fig. 3. Patient at the Surgical Emergency Unit. Significant edema of both right eyelids was localized, with less pronounced edema of the left periorbital area.

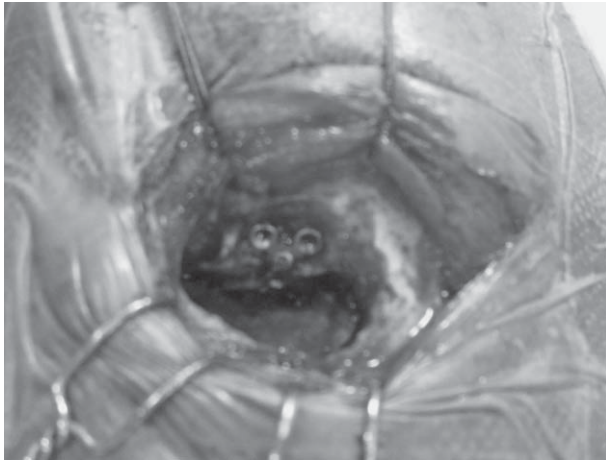


Fig. 4. The neurosurgeon and maxillofacial surgeon performed supraorbital right side 'key hole' craniotomy, through which bone fragments of the orbital roof were replaced and fixed.

Postoperatively, the patient was subfebrile (37.4 °C), her general condition was good, she was fully conscious, without character changes, and with normal cardiobronchial and somatic status. Edema of the right eyelid was localized, and there was ptosis of the upper right eyelid and protrusion of the right bulb. Postoperative wound healing was neat.

Follow up magnetic resonance imaging (MRI) of the brain was performed at 14 weeks of oral antibiotic therapy. In the right frontal lobe around the penetrating canal, extensive edema was found. Within it there was an abscess of 20x14 mm in size with a ring edged opacification and compressive effect on the right frontal horn. Supraorbitally, along with the bone defect, a smaller epidural abscess of 14 mm in diameter was seen.

Laboratory testing showed elevated erythrocyte sedimentation rate (ESR; 50 mm/3.6 ks) and C-reactive

protein (CRP; 40.5 mg/L), while other findings were normal.

Intravenous therapy, a combination of ciprofloxacin 2x400 mg and metronidazole 3x500 mg, with anti-edema therapy with dexamethasone 2x4 mg was introduced. Drug dosage was gradually decreased and anti-edema therapy was discontinued after 21 days.

Five weeks after intravenous antibiotic therapy, brain MRI showed stationary abscess on the right side, frontally around the perforated canal, and regression of epidural accumulation.

Inflammatory parameters were normalized (ESR 17 mm/3.6 ks, CRP 0.8 mg/L), intravenous therapy was discontinued, and oral therapy with a combination of ciprofloxacin 3x500 mg and metronidazole 3x500 mg was administered.

Brain MRI showed small regression of the intracerebral abscess and partial gliosis nine weeks after antibiotic therapy. Fourteen weeks after antibiotic therapy, MSCT was performed again and showed complete regression of intracerebral abscess with gliosis, no edema but still visible edema of the orbit and proptosis of the eye bulb. There was exophthalmos on the right and ptosis of the right upper eyelid. Antibiotic therapy was discontinued fourteen weeks later.

Follow up brain MRI at six months after the operation showed normal intracranial finding.

The patient's general condition, somatic and neurologic status were finally normal, after the operation and antibiotic therapy, with only mild psychomotor changes.

Discussion

Our 37-year-old patient had sustained penetrating orbitocranial wound and intracranial injury due to falling on a metal rod. Searching the world's literature we found similar case reports in civilians. Kim *et al.* studied craniofacial injuries in 82 patients from 2002 till 2010. All patients had postoperative complications¹. Miscusi *et al.* describe a case of a 35-year-old patient who fell from the height of 5 meters on an iron fence; she was successfully operated on, with very good results². Singh *et al.* had a 35-year-old patient who fell on wooden sticks and one hour after that, protrusion of the left bulb developed. Apart from mild headache, she did not have any neurologic deficit³. Domenicucci *et al.* report on a case of a young person who had an

accident and was admitted with a plastic cap metal rod, two centimeters perforating into the orbit. After treatment, she had neither neurologic nor ophthalmologic deficit⁷. Chibaro *et al.* retrospectively observed 18 cases and found that results were good if diagnosis and treatment were attempted early⁸.

Reports on wartime research show the severity of orbitocranial wounds. A 12% mortality rate was found among 42 patients with orbitocranial wounds treated during World War II, as reported by Webster *et al.*⁹. Rish *et al.* analyzed a population of 1221 patients with penetrating craniocerebral trauma from the Vietnam War. The incidence of brain abscess was 3% and mortality rate 54%. Of the patients that survived, 82% had significant morbidity¹⁰. In the Desert Storm operation, mortality rate of orbitocranial injuries was approximately 12%¹¹. Janković *et al.* analyzed 14 patients with orbitocranial war injuries treated during the war in Croatia and Bosnia and Herzegovina. One patient died in the hospital, blindness was present in eight patients, light perception positivity and projection positivity were present in four patients, and visual acuity was 0.1 in one patient. Several days after initial treatment, complications such as cerebrospinal fluid leaking, cerebral abscess, meningitis or epilepsy appeared in some patients¹².

In this case report, the patient recovered well, apart from mild psychomotor changes but no neurologic deficit.

Conclusion

Penetrating orbitocranial wound is a life-threatening condition that demands interdisciplinary approach and treatment. After having been operated by a maxillofacial surgeon, an ophthalmologist and a neurosurgeon, our patient recovered very well. Local abscess that occurred subsequently was successfully treated by antibiotic therapy, and apart from mild psychomotor changes, the patient had no neurologic deficit. It

should be noted that such wires should have safety measures such as plastic balls to prevent such injuries.

References

1. Kim SW, Youn SK, Kim JT, Cho SH, Kim YH, Hwang KT. Management of an unusual craniofacial impalement injury by a metallic foreign body. *J Craniofac Surg.* 2012;23(2):140-6. doi: 10.1097/SCS.0b013e31824cdc2b
2. Miscusi M, Arangi P, De Martino L. An unusual case of orbito-frontal rod fence stab injury with good outcome. *Surgery.* 2013;13:31-6. doi: 10.1186/1471-2482-13-31
3. Singh A, Kumar Bhasker S, Kumar Singh B. Transorbital penetrating brain injury with a large foreign body. *J Ophthalmic Vis Reg.* 2013;8:62-5.
4. Misra M, Khan GM, Mohanty AB, Rath S. An unusual orbitocranial foreign body. *Indian J Ophthalmol.* 1992;40:94-5.
5. Singh P, Misra GS, Singh A, Murthy MGK. Missile injuries of brain – an experience in Northern Sector. *Med J Armed Forces India.* 2003;59:290-7. doi: 10.1016/S0377-1237(03)80137-5. Epub 2011 Jul 21
6. Turbin RE, Maxwell DN, Langer PD, Frohman LP, Hubbi B, Wolansky L, *et al.* Patterns of transorbital intracranial injury: a review and comparison of occult and non-occult cases. *Surv Ophthalmol.* 2006;51:449-60. doi: 10.1016/j.survophthal.2006.06.008
7. Domenicucci A, Qasho R, Ciapetta P, Vangelista T, Delfini R. Surgical treatment of penetrating orbitocranial injuries. Case report. *J Neurosurg Sci.* 1999;43:229-34.
8. Chibbaro S, Tacconi L. Orbitocranial injuries caused by penetrating nonmissile foreign bodies. Experience with eighteen patients. *Acta Neurochir.* 2006;148:937-41. doi: 10.1007/s00701-006-0794-5
9. Webster SE, Schneider RC, Lofstrom SE. Observations upon management of orbitocranial wounds. *J Neurosurg.* 1946;3:329-35. doi: 10.3171/jns.1946.3.4.0329
10. Rish BL, Caveness WF, Dillon JD, Kistler JP, Mohr JP, Weiss GH. Analysis of brain abscess after penetrating craniocerebral injuries in Vietnam. *Neurosurgery.* 1981;9:535-41.
11. Shuker ST. Management of transcranial orbital penetrating shrapnel/bullet war injuries. *J Oral Maxillofac Surg.* 2008;66:1927-31. doi: 10.1016/j.joms.2007.08.038
12. Janković S, Buča A, Bušić Z, Žuljan I, Primorac D. Orbitocranial war injuries: report of 14 cases. *Mil Med.* 1998;163:490-3.

Sažetak

ORBITALNO-KRANIJSKA PENETRIRAJUĆA OZLJEDA

M. Klančnik, P. Ivanišević, S. Lupi-Ferandin, A. Sučić, V. Ledenko, M. Lešin, M. Krnić Martinić i Lj. Kuščić-Juretić

Prikazujemo slučaj 37-godišnje bolesnice primljene na hitni kirurški prijam nakon slučajnog pada na metalnu šipku i posljedične ubodne ozljede desne orbite s probojem u desni frontalni režanj mozga. Svijest nije gubila. MSCT je pokazao penetrirajuću ozljedu i frakturu krova desne orbite bez oštećenja očnog bulbosa i endokranijskim imprimatom fragmenata u desni frontalni režanj mozga. Nije bilo znakova edema mozga, ali je bila prisutna proptoza, ptoza i curenje cerebrospinalnog likvora iz lezije konjunktive. Hitan operativni zahvat su izveli maksilofacijalni kirurg i neurokirurg; učinjena je repozicija koštanih fragmenata krova orbite i kranioplastika. Oftalmolog je izveo rekonstrukciju Tenonove kapsule desnog očnog bulbosa. Iz intraoperacijskog obriska rane orbite izoliran je *Bacillus cereus* te su prema preporuci infektologa ordinirani antibiotici ciprofloksacin i rifampicin. Kontrolni MSCT mozga nakon 15 dana i MRI mozga nakon 25 dana su pokazali edem mozga desne frontalne regije i znakove lokalnog apscesa mozga. Infektolog je ordinirao intravensku primjenu antibiotika ciprofloksacin i metronidazol s kortikosteroidima radi suzbijanja edema. Nakon 14 tjedana antibiotske terapije MSCT mozga je pokazao potpunu regresiju apscesa bez okolnog edema, a bolesnica je bila bez neurološkog deficita s blagim psihomotornim promjenama.

Ključne riječi: *Prikazi slučaja; Glava, ozljede, penetrirajuće; Oko, ozljede, penetrirajuće; Orbita; Moždani edem*