

Neuroretinitis caused by *Bartonella henselae*: case report

Sofia Simões Ferreira¹, Andreia Ribeiro¹, Filipe Neves², Isabel Pinto Pais¹, Teresa Torres¹, Dália Meira², Marta Vila Real³

Cat scratch disease is an infectious disease caused by Bartonella henselae characterized by regional lymphadenopathy and fever. Although it may involve other organs, ocular involvement is rare (5%-10%) and may manifest as neuroretinitis. We present a case of an 11-year-old patient admitted to the emergency department because of vision loss on the right eye, detected on a vision screening test. Ophthalmological evaluation showed disc swelling, peripapillary microhaemorrhages and macular oedema with lipid-rich exudates, suggestive of the macular star pattern. Serological studies revealed elevated titre of antibodies to Bartonella henselae. The patient was treated with rifampicin and doxycycline, with optimal response. Neuroretinitis is an uncommon manifestation of Bartonella henselae infection and should be suspected in any patient presenting loss of visual acuity, along with the finding of disc swelling, macular star exudates, and a history of contact with cats. Most patients recover most or all of their pre-infection visual function, however, a small subset of patients with particularly severe neuroretinitis may be left with optic sequelae. There are no randomized trials on the effectiveness of treatment but antibiotic therapy with rifampicin and doxycycline seems to shorten the course of the disease and hasten visual recovery.

Key words: BARTONELLA HENSELAE; CAT SCRATCH DISEASE; RETINITIS; PAEDIATRICS; VISUAL ACUITY; OPTIC DISC

INTRODUCTION

Cat scratch disease is caused by *Bartonella henselae*, a gram-negative bacterium, for which cats are the main reservoir (1). About 5%-10% of patients present less common manifestations of *Bartonella henselae* infection, such as neuroretinitis, Parinaud oculoglandular syndrome and chorioretinitis (2).

Neuroretinitis presents with bilateral or unilateral decreased visual acuity or blindness, afferent pupillary defect, disc swelling with extension to the peripapillary and macular area, and associated visual field abnormalities. Reabsorption of the serous macular oedema leads to precipitation of the lipid-rich component of the exudates into the outer plexiform layer of the retina, producing a typical macular star (2-4).

CASE REPORT

The clinical case refers to an 11-year-old Caucasian boy, without relevant personal or family history, no recent trips and up-to-date vaccinations. He was admitted to the emergency

department because of vision loss on the right eye, detected on a vision screening test at a primary health care unit.

He had no fever, eye pain, headache, running nose, cough or symptoms suggestive of focal neurological deficit. There was a history of fever and ear pain two weeks prior to admission to the emergency department and cat scratches incurred one month prior to the admission date.

Physical examination showed linear abrasions on the right lower limb and left upper limb and no palpable lymphade-

¹ Paediatrics Department, Centro Hospitalar de Vila Nova de Gaia e Espinho, Vila Nova de Gaia, Portugal

² Ophthalmology Department, Centro Hospitalar de Vila Nova de Gaia e Espinho, Vila Nova de Gaia e Espinho, Portugal

³ Neuroscience Unit for Children and Adolescents, Paediatrics Department, Centro Hospitalar de Vila Nova de Gaia e Espinho, Vila Nova de Gaia e Espinho, Portugal

Correspondence to:

Sofia Simões Ferreira, MD, Paediatrics Department, Centro Hospitalar de Vila Nova de Gaia e Espinho, Rua Doutor Francisco Sá Carneiro, 4400-129 Vila Nova de Gaia, Portugal, E-mail: sofiaferreira20@gmail.com

Primljeno/Received: 30. 7. 2018., Prihvaćeno/Accepted: 5. 9. 2018.

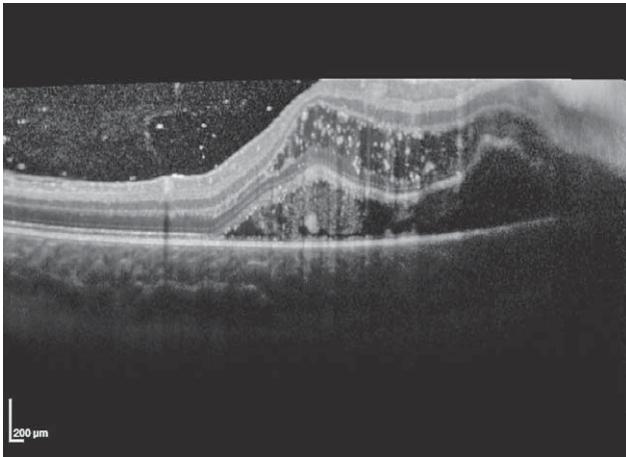


FIGURE 1. Optic neuritis and macular oedema in Spectral Domain Optical Coherence Tomography (SD-OCT).

nopathies. There were no other findings revealed by physical or neurological examination.

The patient presented unilateral diminished visual function (right eye visual acuity: 20/100; left eye visual acuity: 20/20). Complete ophthalmological evaluation revealed typical features of neuroretinitis; fundus examination showed focal inflammation of the optic nerve with disc swelling and peripapillary microhaemorrhages; macular oedema with lipid-rich exudates, suggestive of the macular star pattern were also reported.

Blood analysis showed an increase in the erythrocyte sedimentation rate (30 mm/h) but no leukocytosis, neutrophilia or elevation of C-reactive protein. Biochemistry, proteinogram, coagulation, immunological, antinuclear antibodies, and rheumatoid factor studies were normal. Serological studies were also obtained. Cranial computed tomography was normal. Cerebrospinal fluid (CSF) showed pleocytosis (leukocyte 19/ μ L, 100% mononuclear) and oligoclonal bands, revealing a systemic inflammatory response. Protein and glucose were normal. Bacteriological aspects and testing for virus and *Bartonella henselae* by polymerase chain reaction (PCR) remained in progress. In order to obtain a more accurate evaluation of the severity of optic neuritis and macular oedema, Spectral Domain-Optical Coherence Tomography (SD-OCT) was performed. Disc swelling and the sub- and intra-retinal fluid in the macular area were analysed in detail (Figure 1).

The patient was admitted to the Department of Paediatrics with the most likely diagnosis of neuroretinitis associated with *Bartonella henselae* infection, and started treatment with oral doxycycline 100 mg/12 hours and rifampicin 300 mg/12 hours.

Serological studies (herpes simplex virus 1 and 2, Epstein-Barr, cytomegalovirus, *Treponema pallidum*, measles, *Myc-*

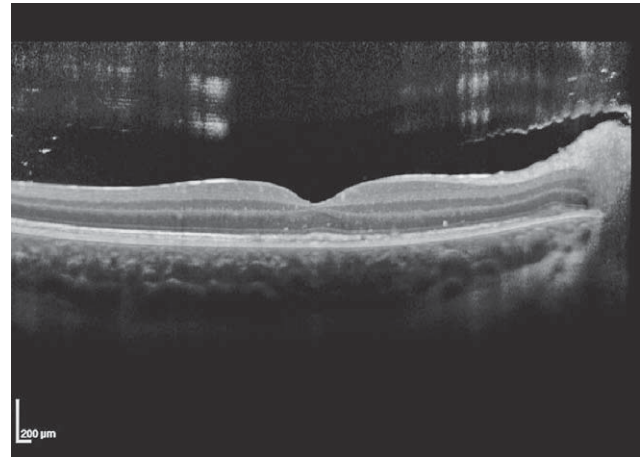


FIGURE 2. Improvement of optic neuritis and macular oedema in Spectral Domain Optical Coherence Tomography (SD-OCT) at discharge.

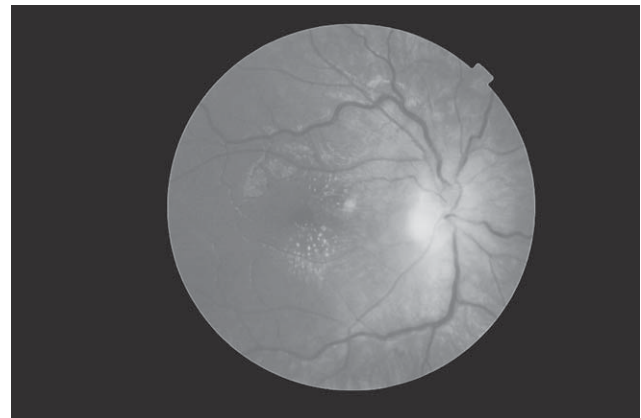


FIGURE 3. Macular lipid deposits on funduscopy examination.

plasma pneumoniae, *Chlamydia pneumoniae*, *Leptospira*, *Rickettsia conorii*, *Coxiella burnetii*, *Borrelia burgdorferi*, and toxoplasma) were negative, except for antibody titre to *Bartonella henselae* (indirect immunofluorescence): IgM negative and IgG positive (2048) and to Parvovirus: IgM positive and IgG positive (75). PCR in CSF for *Bartonella henselae*, Parvovirus, Enterovirus, herpes simplex virus 1 and 2, human herpesvirus 6 and 7, varicella-zoster, toxoplasma, influenza, Epstein-Barr, cytomegalovirus and *Mycoplasma pneumoniae* was negative. Bacterial cultures of the blood and CSF were negative. The Mantoux test and interferon- γ release assays were also negative. Cranial magnetic resonance imaging was normal except for a focal signal strengthening in the optic disc.

The patient remained afebrile and clinically stable. The patient was discharged on day six of admission. At that time, ophthalmological evaluation showed improvement in visual function (right eye visual acuity: 20/50; left eye visual acuity: 20/20), as well as major reduction of the optic disc oedema and associated macular oedema. SD-OCT images

showed clear decrease in both sub- and intra-retinal fluid (Figure 2). Funduscopy revealed macular lipid deposits, inferiorly to the fovea (Figure 3).

One week after discharge, visual function recovered completely, along with resolution of the disc swelling and macular oedema. Given the clinical improvement, it was decided to suspend rifampicin and complete four weeks of doxycycline.

Serology was repeated four weeks after admission: *Bartonella henselae* IgM negative/IgG positive (4097) and Parvovirus IgM negative/IgG positive (60).

DISCUSSION

Neuroretinitis is uncommon and usually occurs a few weeks after typical systemic manifestations, but can occur even without these manifestations (2). Serological tests (indirect immunofluorescence or ELISA) are the most cost-effective and widely used complementary diagnostic tests (5, 6). Determination of IgM has less sensitivity than IgG with both techniques (2).

In this case, although IgM was persistently negative, significant elevation of IgG antibodies to *Bartonella henselae* by indirect immunofluorescence suggested infection by *Bartonella henselae*. Regarding Parvovirus, IgM was positive on first serology. IgG was also positive, but with low titre. However, after four weeks, IgM was negative and IgG positive, but with even lower titre. Thus, there was no seroconversion. It was probably a false-positive or cross reaction.

Optimal therapy for neuroretinitis remains unknown, however, the majority of authors recommend to initiate antibiotic therapy, as it seems to promote resolution of neuroretinitis (2, 7, 8). Although there are no controlled studies on the effectiveness of treatment, it is recommended that a combination of doxycycline 200 mg daily and rifampicin 600 mg daily be administered for four to six weeks (2, 7, 8). Corticoid therapy is controversial since there are no controlled trials examining its efficacy, however, most authors do not recommend this treatment (2, 7). Corticoid therapy may have a role in patients with severe or persistent optic neuropathy.

In conclusion, neuroretinitis by *Bartonella henselae* should be suspected in any patient that manifests loss of visual

acuity together with the finding of disc swelling, macular star exudates and a history of contact with cats (9). Most patients recover most or all of their pre-infection visual function. Macular exudates may take months to resolve, nevertheless, patients may be left with subnormal contrast sensitivity and abnormal visual evoked potentials (3,7). Additionally, a small subset of patients with particularly severe neuroretinitis may be left with optic disc pallor, abnormal colour vision, and an afferent pupillary defect (3, 7). Thus, they should be managed in conjunction with close monitoring by an ophthalmologist.

Abbreviations:

CSF – Cerebrospinal fluid

PCR – polymerase chain reaction

SD-OCT – Spectral Domain-Optical Coherence Tomography

REFERENCES

1. Nelson CA, Saha S, Mead PS. Cat-scratch disease in the United States, 2005-2013. *Emerg Infect Dis*. 2016;22:1741-6. doi:10.3201/eid2210.160115
2. Pérez J, Munita J, Araoz R, et al. Neuro-retinitis asociada a enfermedad por arañazo de gato: presentación de dos casos y revisión de la literatura. *Rev Chil Infect*. (in Spanish) 2010;27:417-22. doi:10.4067/S0716-10182010000600008
3. Wade NK, Levi L, Jones MR, Bhisitkul R, Fine L, Cunningham ET. Optic disk edema associated with peripapillary serous retinal detachment: an early sign of systemic *Bartonella henselae* infection. *Am J Ophthalmol*. 2000;130:327-34. doi:10.1016/S0002-9394(00)00599-7
4. Ormerod LD, Dailey JP. Ocular manifestations of cat-scratch disease. *Curr Opin Ophthalmol*. 1999;10:209-16. doi:10.1097/00055735-199906000-00010
5. Metzcor-Cotter E, Kletter Y, Avidor B, et al. Long-term serological analysis and clinical follow-up of patients with cat scratch disease. *Clin Infect Dis*. 2003;37:1149-54. doi:10.1086/378738
6. Mehmet U. Evaluation of cat scratch disease cases reported from Turkey between 1996 and 2013. *Cent Eur J Public Heal*. 2015;23:170-5. doi:10.1016/j.pediatrneurol.2009.11.004
7. Reed JB, Scales DK, Wong MT, Lattuada CP, Dolan MJ, Schwab IR. *Bartonella henselae* neuroretinitis in cat scratch disease diagnosis, management, and sequelae. *Ophthalmol Microbiol Am Uveitis Soc Assoc Ophthalmic Pathol*. 1998;105:459-66. doi:10.1016/S0161-6420(98)93028-7
8. Durá Traveá T, Yoldi Petri ME, Lavilla Oiz A, Molins Castiella T. Neuroretinitis asociada a la enfermedad por arañazo de gato. *An Pediatr*. 2010;72:290-1. doi:10.1016/j.anpedi.2009.12.005 (in Spanish)
9. Durá-Travé T, Yoldi-Petri ME, Gallinas-Victoriano F, Lavilla-Oiz A, Bove-Guri M. Neuroretinitis caused by *Bartonella henselae* (cat-scratch disease) in a 13-year-old girl. *Int J Pediatr*. 2010;2010:763105. doi:10.1155/2010/763105

SAŽETAK

Neuroretinitis uzrokovan bakterijom *Bartonella henselae*: prikaz slučaja

Sofia Simões Ferreira, Andreia Ribeiro, Filipe Neves, Isabel Pinto Pais, Teresa Torres, Dália Meira, Marta Vila Real

Bolest mačjeg ogreba je zarazna bolest uzrokovana bakterijom Bartonella henselae, a obilježena je regionalnom limfadenopatijom i vrućicom. Iako i drugi organi mogu biti zahvaćeni, oči su rijetko zahvaćene (5% - 10%), što se može manifestirati kao neuroretinitis. Prikazujemo slučaj 11-godišnjeg dječaka primljenog na hitni odjel zbog gubitka vida na desnom oku, što je otkriveno probirnim testiranjem vida. Oftalmološki pregled pokazao je otok diska, peripapilarna mikrokrvarenja i edem makule s eksudatima bogatim lipidima, što je ukazivalo na zvjezdastu makulu. Serološki testovi pokazali su povišeni titar protutijela na Bartonella henselae. Bolesnik je liječen rifampicinom i doksiciklinom, uz optimalan terapijski odgovor. Neuroretinitis je rijetka manifestacija infekcije bakterijom Bartonella henselae i na njega treba posumnjati u svakog bolesnika u kojega se uz gubitak vidne oštrine utvrdi oticanje diska, zvjezdasti eksudati makule te kontakt s mačkama u anamnezi. Kod većine bolesnika predinfekcijska vidna funkcija oporavi se u većoj mjeri ili potpuno, međutim, u manjeg broja bolesnika s naročito teškim neuroretinitisom mogu ostati posljedice u funkciji vida. Nema randomiziranih istraživanja učinkovitosti liječenja, no čini se da antibiotska terapija rifampicinom i doksiciklinom skraćuje tijek bolesti i ubrzava oporavak vida.

Ključne riječi: *BARTONELLA HENSELAE*; BOLEST MAČJEG OGREBA; NEURORETINITIS; PEDIJARIJA; VIDNA OŠTRINA; OPTIČKI DISK