

Atypical congenital cartilaginous rest of the neck in a one-year-old female patient

Zlatko Kljajić¹, Željka Roje², Katarina Vilović³, Petar Ivanišević¹, Petra Smoje¹

Cartilaginous rests of the neck are rarely described congenital anomaly for which there is no definite name in the literature, and is often misdiagnosed as congenital lateral cysts and/or neck fistulas. The authors present a case of a one-year old girl monitored from birth due to nodular formations on the neck, in order to highlight the importance and span of differential diagnosis of congenital malformations of the lateral neck region and the role of ultrasonography in differential diagnosis since the surgical treatment plan depends on it. Clinical examination revealed a formation of 2x1 cm, well differentiated from the surface, on the right side of the neck in region II/III. On the left side in region II/III, there was a smaller formation of 2-3 mm in diameter. Sonography of the neck did not reveal any fistulae or cysts. On surgical excision in general anaesthesia, the cartilaginous core was found and excised without any problems.

Key words: congenital cartilaginous rests of the neck, tumour, wattles, child, Croatia

INTRODUCTION

Congenital cartilaginous rests of the neck (wattles) are very rare, probably branchiogenic malformations. These lesions are more often seen in males (1). Clinically, these lesions are always present at birth, and classically occur along the lower half or one-third of the anterior aspect of the sternocleidomastoid muscle (2). They are thought to originate either from the second branchial arch or from auricular tissues (3). Six protuberances, now known as the 'hillocks of His', have been found in branchial arches of human embryos. These hillocks or tubercles – three in the first arch and three in the second arch – are first identifiable during the sixth week of embryogenesis surrounding the first branchial cleft, which is the space or groove between the first and second arches. Growth and morphological change within these arches occur until a definitive auricular form is evident between the eighth and ninth week of development (4). One meaning of the 'wattle' is a fleshy appendage beneath the throat, and it is also a term used for pendulous skin tags (5).

Ultrasound of the neck is necessary to exclude fistulae or cysts. A high incidence of associated anomalies mandates meticulous physical examination and ultrasound of the genitourinary tract. It has also been associated with other malformations such as microtia, stenosis of the external ear canal, and branchiogenic fistulae (6). Goldenhar, Treacher-Collins syndromes may include cervical or preauricular rem-

nants (1). Townes-Brocks, Wolf-Hischhorn and Delleman syndromes can also be associated with congenital cartilaginous rests of the neck (6).

If diagnosis is uncertain, excision and histological diagnosis is essential (7). Surgical removal is simple and usually undertaken for cosmetic reasons (1). Less than 50 cases have been reported in medical literature to date (8).

The aim of this case report is to stress the importance of differential diagnosis of congenital lateral neck region formation and the role of echosonography in differential diagnosis before deciding on the extension of surgical treatment.

CASE REPORT

A one-year-old Caucasian girl was referred to the ENT office for evaluation of exophytic skin-coloured bilateral nodules of the neck. This was present since her birth, without any

¹ Clinical Department for Otorhinolaryngology, Split University Hospital Centre, Split, Croatia

² Dr Željka Roje Private ENT Practice, Split, Croatia

³ Clinical Department for Pathology, Split University Hospital Centre, Split, Croatia

Correspondence to:

Zlatko Kljajić, MD, Clinical Department for Otorhinolaryngology, Split University Hospital Centre, Spinčićeva 1, HR-21000 Split, Croatia, e-mail: kljajiczlatko1@gmail.com

Primljeno/Received: 21. 7. 2017., Prihvaćeno/Accepted: 12. 2. 2018.

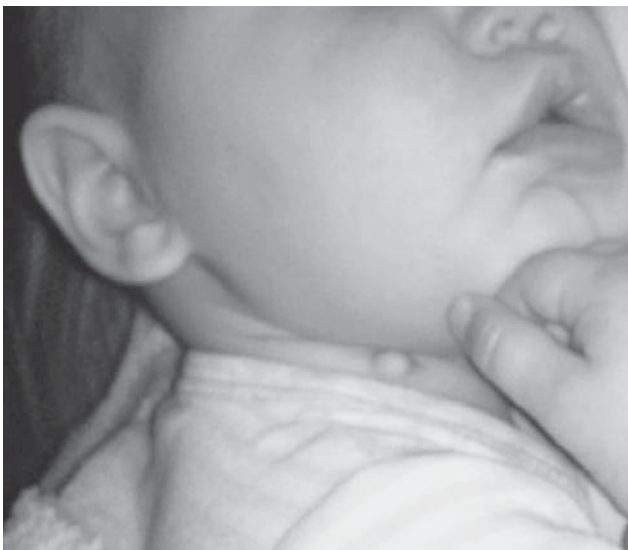

FIGURE 1. Atypical congenital cartilaginous rest on the right side of the neck.

complications (Figure 1). No other congenital malformations or minor anomalies were found, while her family history revealed no comparable skin lesions.

On the right side of the neck in region II/III, there was a formation, 2x1 cm, well differentiated from the surface. On the left side of the neck in region II/III, there was a smaller formation, 2-3 mm in diameter. Ultrasound of the neck did not reveal any fistulae or cysts. There was no contact with other neck structures. The formation was above the platysma level.

Surgical excision of the macroscopic described skin change was performed in general anaesthesia, together with subcutaneous tissue and undercurrent cartilage, and was referred for histopathologic analysis. The wounds healed without any complications. Histologic examination confirmed ectopic cartilaginous tissue with the following report: The skin area is 2x1x1 cm with polypous change in the colour of surrounding skin 1x0.7 cm and two pieces of hard brown-white tissue of 0.7 and 0.3 cm in diameter. Microscopically, all pieces had regular epidermis on the surface; within the dermis, there was very scarce lymphocytic inflammatory infiltrate and skin adnexa. In the central part of all three pieces, ectopic-cartilage tissue was seen, with histologically normal structure of 0.1x0.4x1 cm (Figure 2).

DISCUSSION

Congenital cartilaginous rests of the neck may be unilateral or bilateral (2). Wattles are often pedunculated over or near the sternocleidomastoid muscle. Parents are looking for treatment primarily for cosmetic reasons because infections are very rare. *Blattner et al.* also describe a case of a 12-year-

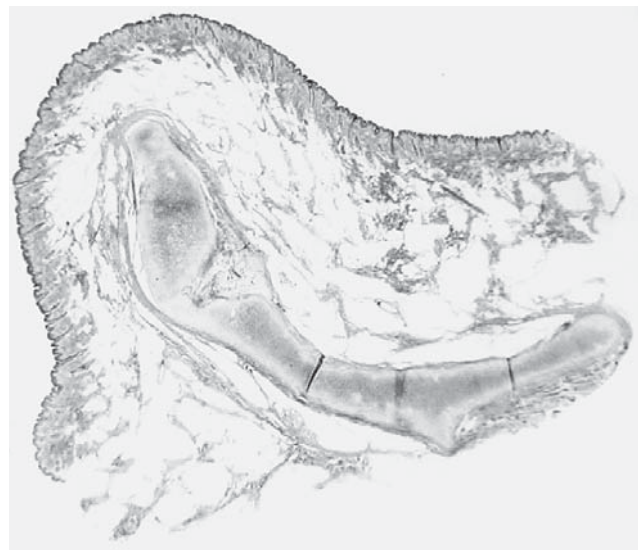


FIGURE 2. Histologic examination confirmed ectopic cartilaginous tissue (HE, X40).

-old boy with 'skin tag' overlying the inferior portion of the anterior triangle of the neck at the insertion of the sternocleidomastoid muscle. Shave biopsy was performed and histologic examination confirmed ectopic cartilaginous tissue under the epidermis with normal adnexal structures (6). On the contrary to this case we do not recommend shave excision because it may leave the cartilage exposed, with subsequent complications (8,9). In a 6-year-old boy, a slow-growing swelling on the right side of the neck was present from birth. Examination revealed a firm, mobile mass that measured two cm across the subcutaneous plane, overlying the lower third of the sternocleidomastoid muscle. Histology showed it to be normal skin overlying a core of cartilage in the subcutaneous fat (2).

After ultrasonography examination to exclude cysts or fistulae, the surgeon can speculate about intervention. Taking into consideration that these operations are performed on children, endotracheal anaesthesia should be done, especially because of the necessary excision depth. The operations are performed at a relatively young age because little children often scratch themselves, so injuries and infections are likely to happen.

Differential diagnosis includes sentinel tags associated with branchial sinuses or fistulae, simple skin tags, and benign papillomas. Ultrasound of the neck is necessary to exclude fistulae or cysts.

CONCLUSION

In differential diagnosis of congenital lateral neck region formation, it is important to think about congenital cartilaginous rests of the neck. Ultrasonography of the neck is nec-

essary to exclude fistulae or cysts, and to plan the extension of surgery. 'Shave' surgery is forbidden because of cartilaginous core, which stays in place exposed and prone to complications.

NOVČANA POTPORA/FUNDING

Nema/None

ETIČKO ODOBRENJE/ETHICAL APPROVAL

Nije potrebno/None

SUKOB INTERESA/CONFLICT OF INTEREST

Autori su popunili *the Unified Competing Interest form* na www.icmje.org/coi_disclosure.pdf (dostupno na zahtjev) obrazac i izjavljuju: nemaju potporu niti jedne organizacije za objavljeni rad; nemaju financijsku potporu niti jedne organizacije koja bi mogla imati interes za objavu ovog rada u posljednje 3 godine; nemaju drugih veza ili aktivnosti koje bi mogle utjecati na objavljeni rad./All authors have completed the *Unified Competing Interest form* at www.icmje.org/coi_disclosure.pdf (available on request from the corresponding author) and declare: no support from any organization for the submitted work; no financial relationships with any organizations that might have an interest in the submitted work in the previous 3 years; no other relationships or activities that could appear to have influenced the submitted work.

REFERENCES

1. Dayal D, Menon P. Bilateral cervical chondrocutaneous branchial remnants. *Indian Pediatr.* 2008;45:221.
2. Rai S, Manohar C. Pathologic quiz case: subcutaneous nodule in the neck. Congenital cartilaginous rest. *Arch Pathol Lab Med.* 2003;127:438-9. doi: 10.1043/1543-2165(2003)127<e438:PQCSNI>2.0.CO;2
3. Nasser HA, Iskandarani F, Berjaoui T, Fleifel S. A case report of bilateral cervical chondrocutaneous remnants with review of the literature. *J Pediatr Surg.* 2011;46:998-1000. doi: 10.1016/j.jpedsurg.2011.01.015
4. Cox TC, Camci ED, Vora S, Luquetti DV, Turner EE. The genetics of auricular development and malformation: new findings in model systems driving future directions for microtia research. *Eur J Med Genet.* 2014;57:394-401. doi: 10.1016/j.ejmg.2014.05.003. Epub 2014 May 29.
5. Clarke JA. Are wattles of auricular or branchial origin? *Br J Plast Surg.* 1976;29:238-44.
6. Blattner CM, Ross F, Bohlke A, Young IJ. Congenital cartilaginous rest of the neck in a boy. *Dermatol Online J.* 2016;22:16.
7. Ali SA, Tahir SM, Somro AG, Memon AS, Shaikh NA. Cervical auricle: a rare congenital anomaly in a one year old girl. *RMJ.* 2010;35:104-5.
8. Vaughan TK, Sperling LC. Diagnosis and surgical treatment of congenital cartilaginous rests of the neck. *Arch Dermatol.* 1991;127:1309-10.
9. Bendet E. A wattle (cervical accessory tragus). *Otolaryngol Head Neck Surg.* 1999;121:508-9.

SAŽETAK

Atipična razvojna malformacija škržnog luka u jednogodišnje djevojčice

Zlatko Kljajić, Željka Roje, Katarina Vilović, Petar Ivanišević, Petra Smoje

Škržni ostatak u vratu je rijetko opisana prirođena anomalija za koju nema utvrđenog imena u literaturi, a često se pogrešno dijagnosticira kao prirođena lateralna cista i/ili vratna fistula. Autori opisuju slučaj jednogodišnje djevojčice koja je praćena od rođenja zbog čvornatih tvorbi na vratu kako bi upozorili na važnost i širinu diferencijalne dijagnostike prirođenih malformacija lateralne regije vrata kao i na ulogu ultrazvuka u diferencijalnoj dijagnostici, jer kirurško liječenje ovisi o tome. Kliničkim pregledom nađena je tvorba veličine 2x1 cm, dobro diferencirana od površine, na desnoj strani vrata u II./III. regiji. Ultrazvuk vrata nije otkrio nikakve fistule ili ciste. Kirurškom incizijom nađena je hrskavična srž tvorbe koja je kirurški odstranjena u općoj anesteziji bez ikakvih problema.

Ključne riječi: prirođeni škržni ostatak u vratu, tumor, podvoljak, dijete, Hrvatska