

IMMUNOHISTOCHEMICAL EXPRESSION OF BROTHER OF THE REGULATOR OF IMPRINTED SITES (BORIS) IN TESTICULAR GERM CELL TUMORS

ANA MESIĆ¹, IVANA MILOŠEVIĆ², VIBOR MILUNOVIĆ³, MILAN MILOŠEVIĆ⁴,
MONIKA ULAMEC^{5,6,7} and BOŽO KRUŠLIN^{5,6,7}

¹Institute of Emergency Medicine, Krapina-Zagorje County, Krapina, ²University of Zagreb, School of Medicine, Zagreb, ³Merkur University Hospital, Department of Hematology, Zagreb, ⁴University of Zagreb, School of Medicine, Andrija Štampar School of Public Health, Zagreb, ⁵Sestre milosrdnice University Hospital Centre, Ljudevit Jurak Department of Pathology and Cytology, Zagreb, ⁶University of Zagreb, School of Medicine, Department of Pathology, Zagreb and ⁷Scientific Center of Excellence for Regenerative and Reproductive Medicine, Zagreb, Croatia

Brother of the Regulator of Imprinted Sites (BORIS) has a role in intracellular signalization and is important in epigenetic mechanism control, such as methylation/demethylation of DNA and histones. BORIS may deregulate some tumor suppressor genes. Immunohistochemical expression of BORIS was found in different tumors, some of them showing correlation with poor prognosis. The aim of this study was to determine immunohistochemical expression of BORIS in pure seminomas and different components of testicular mixed germ cell tumors (MGCT). In this study, immunohistochemical expression of BORIS in testicular germ cell tumors (TGCT) was analyzed. Staining intensity and percentage of positive staining cells were used to evaluate the level of expression. Tumor samples from 44 patients were analyzed; 26 pure seminomas and 18 MGCT. In MGCTs, seminoma component was found in 4, yolk sac in 7, teratoma in 11 and embryonal carcinoma in 13 samples. Expression of BORIS was strong in 80.8% of seminoma cases and in 76.9% of embryonal carcinoma component, 71.4% of yolk sac, 63.6% of teratoma component and 25% of seminomatous component of MGCT. In MGCT, positive correlation was found between BORIS expression in teratomatous component and presence of yolk sac component ($r=0.574$, $p<0.02$). Negative correlation was also observed between BORIS expression in teratomatous component and T stage ($r=-0.559$, $p<0.02$). Positive correlation was found between BORIS expression in embryonal carcinoma component and T stage ($r=0.471$, $p<0.04$). There was no correlation of BORIS expression among different tumor components. These results show the potential role of determining BORIS expression and its possible contribution to improving the diagnosis and treatment of TGCTs.

Key words: BORIS, testicular germ cell tumors, immunohistochemistry, biomarkers

Address for correspondence: Prof. Božo Krušlin, MD, PhD
Ljudevit Jurak Department of Pathology and Cytology
Sestre milosrdnice University Hospital Centre
Vinogradska c. 29
10 000 Zagreb, Croatia
Phone: 3851 3787 177; fax: 3851 3787 244
e-mail: bozo.kruslin@kbcsm.hr

INTRODUCTION

Testicular germ cell tumors (TGCT) account for more than 98% of all testicular tumors, being most common in young male adults (1). An increased incidence in TGCTs has been recorded over the last 40 years, especially in western European countries, with Republic of Croatia and Republic of Slovenia having the highest increase in Europe (1-3).

Somatic mutations that lead to the development of germ cell tumors include mutations in more than one gene; nonseminomas are typically hypotriploid, whereas seminomas are usually hypertriploid. Isochromosome 12p is the most common alteration, which can be found in 80% of seminoma and nonseminoma cases (4,5). Loss of heterozygosity of CDKN2A and RB1 found in nonseminomas could play a role in higher malignant potential compared to seminomas (6,7).

Germ cells, during the early stages of their development (*in utero*), undergo a phase of generalized DNA demethylation (8). Most TGCTs develop from germ cell neoplasia *in situ* (GCNIS), previously known as intratubular germ cell neoplasia (2,5,9). In comparison to normal spermatogonia, GCNIS genome remains unmethylated in adult testis (10).

Brother of the Regulator of Imprinted Sites (BORIS) is the paralogue of CCCTC-binding factor (CTCF), a highly conserved protein with functions including regulation of transcription and genomic imprinting. BORIS is specifically expressed in the embryo, skin, germ cells, and cancer. It acts as an antagonist to CTCF in normal and cancer cells by binding to the same target sequences. Epigenetic mechanisms such as methylation/demethylation of DNA and modification of histones are very important in BORIS function. The result of BORIS transcription is a protein homologous to the multifunctional transcriptional regulator CTCF (11-13). In other cell types, BORIS may be expressed only due to its abnormal activation, which is a result of DNA demethylation, knockout of CTCF and absence of functional p53 tumor suppressor (11,13-16).

Immunohistochemical expression of BORIS has been proven in some tumor types, e.g., laryngeal, esophageal, hepatocellular and breast carcinoma (12,13,17,18). However, currently there are no studies on immunohistochemical expression of BORIS in testicular tumors.

Despite the fact that the cure rate of TGCTs is about 95%, some tumors are cisplatin-resistant and long-term side effects occur as a result of treatment (2,19,20). Therefore, it is important to additionally investigate TGCT, its pathogenesis, as well as diagnostic and treatment possibilities.

OBJECTIVE

The aim of this study was to determine immunohistochemical expression of BORIS in pure seminomas and different components of mixed germ cell tumors (MGCT).

MATERIALS AND METHODS

MATERIALS

Material from 55 patients diagnosed with TGCT was retrieved from the Ljudevit Jurak Department of Pathology and Cytology, Sestre milosrdnice University Hospital Centre tumor registry. Orchidectomy specimens were

from 44 patients treated in our institution during the period from 2000 to 2014 and 11 consultation cases from other institutions. Each patient included in the study was assigned a unique number, whereas the real identity was only known to the researchers. Retrieval of archival tissue was conducted under institutional review board approval. All cases were reevaluated by two pathologists (M.U. and B.K.) and met the WHO criteria for diagnosis. One to twelve blocks were available *per* case, one to three representative blocks of each case, with different tumor components selected for immunohistochemical study. Tissue microarray blocks were made based on marked areas, which was done by a pathologist.

METHODS

Specimens were fixed in 10% buffered formaldehyde, dehydrated in ascending series of alcohol, embedded in paraffin, cut at 5 μ m, deparaffinized in xylol, and routinely stained with hematoxylin and eosin (H-E).

Histologic analysis

All slides were analyzed under low magnification (x40 and x100), and specific tumor components were marked and used for microarray analysis. Two pathologists (M.U. and B.K.) analyzed slides independently. A joint review board resolved all disagreements.

Immunohistochemical analysis

Rabbit polyclonal antibody BORIS (dilution 1:50, Santa Cruz biotechnology, Heidelberg, Germany) was used for immunohistochemical staining. Indirect ABC technique, LSAB method for visualization system on DakoTechMate TM automated immunostainer using Microwave Streptavidin Immuno Peroxidase was used for immunohistochemical staining. Breast cancer tissue was used as positive control for BORIS.

After immunohistochemical staining, the material was completely analyzed. The reaction was examined on 1000 cells under high magnification (x400) in so-called hot spots (highest reaction intensity). Hot spot areas were chosen under low power field. Staining intensity (SI) was semiquantitatively analyzed and graded on a 0-3 scale and expressed as 0, no reaction; 1, weak reaction; 2, moderate reaction; and 3, strong reaction. The percentage of positive staining cells (PPC) was graded on a 0-3 scale as follows: 0, no reactive cells; 1, <10% positive cells; 2, 10%-50% positive cells; and 3, >50% positive cells. For each sample, PPC and SI scores were multiplied to give the immunohistochemical staining index (ISI), which was labeled as follows: 0=zero, 1-4=

low, and 5-9=high. All samples were examined independently by three observers (I.M., A.M. and M.U.) and any differences were resolved by joint review.

Statistical analysis

Nonparametric test was used on statistical analysis due to the small number of patients. Kendal tau_b correlation coefficient was used to assess correlation of BORIS expression (in both seminomas and different MGCT components) with age, T stage and tumor size, as well as correlation of BORIS expression among different components of MGCTs. Absolute coefficient value ≥ 0.600 was considered a measure of strong correlation. All analyses were performed with IBM SPSS Statistics, version 21.0 (www.spss.com). The level of significance was set at $p < 0.05$ in all cases.

RESULTS

Tumor samples from 55 patients were analyzed. T stage was known for 44 patients, of which 32 tumors were T1, 10 were T2 and 2 were T3. Eleven samples representing consultation cases for which the T stage was unknown were excluded from further statistical analysis. Patient age ranged from 19 to 58 (median 34.0); 25 tumors were in the 19-35 age group and 19 tumors in the 35-60 age group. Results are shown in Table 1 and Figure 1.

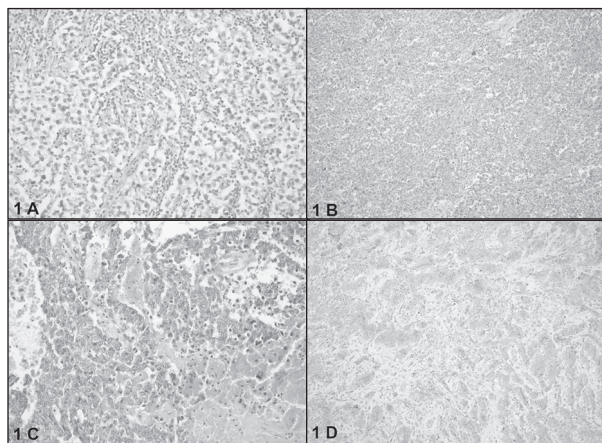


Fig. 1. (A) Microscopic appearance of pure seminoma (HE, x100); (B) immunohistochemical positive BORIS staining (x200); (C) microscopic appearance of mixed germ cell tumors, embryonal carcinoma component (HE, x100); (D) immunohistochemical positive BORIS staining (x200).

Table 1.
 Immunohistochemical expression of BORIS in different components of MGCTs

ISI	Seminoma % (n=26)	MGCT-S % (n=4)	MGCT-YS % (n=7)	MGCT-T % (n=11)	MGCT-EC % (n=13)
0	0 (0)	0 (0)	0 (0)	0 (0)	0 (0)
1	19.2 (5)	75 (3)	28.6 (2)	36.4 (4)	23.1 (3)
2	80.8 (21)	25.0 (1)	71.4 (5)	63.6 (7)	76.9 (10)

ISI, immunohistochemical staining index, MGCT-S mixed germ cell tumor – seminomatous component; MGCT-YS mixed germ cell tumor – yolk sac component; MGCT-T mixed germ cell tumor – teratomatous component; MGCT-EC mixed germ cell tumor – embryonal carcinoma component

Out of 44 samples, there were 26 pure seminomas and 18 mixed germ cell tumors (MGCT). Out of 18 MGCTs, seminomatous component was found in 4, yolk sac component in 7, teratoma component in 11 and embryonal carcinoma in 13 samples.

Expression of BORIS was found in both seminomas and MGCTs. Positive staining cells showed cytoplasmic staining; nuclear staining was not found. Of the seminomas analyzed, BORIS expression was strong in 80.8% of cases, whereas in the seminomatous component of MGCTs it was strong in only one case (25%). Strong expression of BORIS was found in 76.9% of embryonal carcinoma component, 71.4% of yolk sac component, and 63.6% of teratomatous component. Low expression of BORIS was found in the remaining percentage of MGCT components.

Statistical analysis showed a significant positive correlation between age and T stage in the group of pure seminomas ($\tau_b = 0.402$, $p < 0.02$). In the group of non-seminomas, there was a statistically significant positive correlation between BORIS expression in teratomatous component and presence of yolk sac component ($\tau_b = 0.574$, $p < 0.02$). Furthermore, there was a statistically significant negative correlation between BORIS expression in teratomatous component and T stage ($\tau_b = 0.559$, $p < 0.02$). On the other hand, a statistically significant positive correlation was found between BORIS expression in embryonal carcinoma component and T stage ($\tau_b = 0.471$, $p < 0.04$). There was no statistically significant correlation between BORIS expression and tumor size in any group and no correlation of BORIS expression in different tumor components.

DISCUSSION

Despite many new findings in the field of germ cell testicular tumors during the last 10 years, the histopathologic diagnosis of different components of the tumor and TNM stage still plays the most important role in prognosis and therapy.

BORIS is detected in early stages of spermatogenesis, whereas in later stages, it is silenced due to reactivation of CTCF. In human testicular dissected tissue from the same male, the localization of BORIS was nuclear in spermatocytes but cytoplasmic in spermatogonia. In the nucleus, BORIS regulates gene expression, and in the cytoplasm, BORIS binds to RNA and associates with actively translating ribosomes (21-23). BORIS knock-out mice have defective spermatogenesis, small testes and increased cell death (11,21). In our study, BORIS expression was always placed in the cytoplasm of the tumor cells and it was found in all components of TGCT. Both groups analyzed (seminomas and MGCTs) showed BORIS expression. The possible explanation for BORIS expression in both types of TGCTs and all components of MGCTs is that BORIS expression is present during spermatogenesis and that the embryonal carcinoma cell represents a pluripotent testicular tumor containing stem cell that can differentiate into embryonic and extraembryonic tissues.

The lack of useful serum markers for seminoma and embryonal carcinoma is constantly present in disease diagnosing and monitoring. This obstacle has been significantly overcome by the discovery of serum miRNA. Combined AFP/hCG and miRNA test have led to increased sensitivity to up to 98%, independently of age and histologic tumor type (24).

To find appropriate markers for TGCT, it is important to understand the origin of the germ cell tumors, in which epigenetics has a huge role; in the future, epigenetic silencing of aberrantly demethylated epigenetic mediators may prove useful in the treatment of TGCTs. Epigenetic mechanisms such as methylation/demethylation of DNA and modification of histones are very important in BORIS function and it is considered to be a new oncogene, which is reactivated in cancer. BORIS may inhibit *c-myc*, induce the expression of *TSP5* oncogene, and deregulate tumor suppressor genes such as *CTCF2* and *Rb2/p* (8).

Overexpression of BORIS was found to correlate with hypomethylation of its promoter in primary testicular cancer patients, as shown in the study on cell lines (11,25). Other methods were also used to determine BORIS expression in many different tumors, e.g., head and neck squamous cell carcinoma, carcinomas of breast, lung, kidney, bladder, prostate, ovary, endometrium, cervix, colon, as well as in melanoma and leukemic cell lines (11,12,17,26-28). Partial demethylation of BORIS promoter was detected in ovarian, colon and lung cancer, and in leukemic cell lines (27). Colorectal cancer samples and colorectal cancer cell lines showed differential BORIS expression and different responses to BORIS alteration (29).

A recent study of BORIS expression in laryngeal squamous cell carcinomas found positive correlation between the expression of BORIS in laryngeal cancer cells and patient age under 59 years, as well as lower tumor differentiation and lethal outcome within 5 years of surgical procedure (17). Similarly, positive correlation was also found between BORIS expression in esophageal cancer cells and lethal outcome within 5 years (independently of T stage) and lymph node affection in early stage (12). A recent study on hepatocellular carcinoma reports on association between BORIS expression and tumor size, differentiation grade, satellite lesions, and recurrence (18). BORIS expression was found in prostatic cancer cells but not in benign prostatic hyperplasia. BORIS expression showed positive correlation with Gleason score, T stage and androgen receptor level. According to this, it was concluded that BORIS expression could indicate more aggressive prostate cancer behavior (30). Recently, association between BORIS expression and poorer prognosis in lung cancer has been reported, suggesting that BORIS could be used in lung cancer immunotherapy (31).

Similarly, our study also showed positive correlation between BORIS expression in embryonal component of MGCTs and T stage. Interestingly, there was negative correlation between BORIS expression in teratomatous component of MGCTs and T stage.

CONCLUSION

In conclusion, it is important to stress out incomplete understanding of the pathogenetic mechanisms of TGCT development, with current focus being on the role of epigenetic modification. DNA hypomethylation is one of the pathogenetic mechanisms for TGCT development, which is also involved in abnormal BORIS activation. BORIS activation may also be a result of tumor-suppressor *p53* absence and it is known that *p53* silencing can cause complete cisplatin resistance (32).

In our study, BORIS expression was confirmed in both pure seminomas and MGCTs, with pure seminomas having the highest expression of BORIS, which differed to some extent compared to seminomatous component of MGCTs. The expression of BORIS in various TGCTs and their different components may indicate its role in TGCT development. The role of BORIS in the pathogenesis, developmental capacity and differentiation of TGCTs into their various subtypes still remains largely unknown.

R E F E R E N C E S

1. Trabert B, Chen J, Devesa SS, Bray F, McGlynn KA. International patterns and trends in testicular cancer incidence, overall and by histologic subtype, 1973-2007. *Andrology* 2015; 3: 4-12.
2. Litchfield K, Shipley J, Turnbull C. Common variants identified in genome-wide association studies of testicular germ cell tumour: an update, biological insights and clinical application. *Andrology* 2015; 3: 34-46.
3. Sincic N, Kulis T, Znaor A, Bray F. Time trends in testicular cancer in Croatia 1983-2007: rapid increases in incidence, no declines in mortality. *Cancer Epidemiol* 2012; 36: 11-5.
4. Gilbert D, Rapley E, Shipley J. Testicular germ cell tumours: predisposition genes and the male germ cell niche. *Nat Rev Cancer* 2011; 11: 278-88.
5. Moch H, Cubilla AL, Humphrey PA, Reuter VE, Ulbright TM. The 2016 WHO Classification of Tumours of the Urinary System and Male Genital Organs – Part A: Renal, Penile, and Testicular Tumours. *Eur Urol* 2016; 70: 93-105.
6. Vladušić T, Hrašćan R, Krušlin B *et al.* Histological groups of human postpubertal testicular germ cell tumours harbour different genetic alterations. *Anticancer Res* 2014; 34 : 4005-12.
7. Vladusic T, Hrascan R, Pecina-Slaus N *et al.* Loss of heterozygosity of CDKN2A (p16INK4a) and RB1 tumor suppressor genes in testicular germ cell tumors. *Radiol Oncol* 2010; 44: 168-73.
8. Nettersheim D, Jostes S, Sharma R *et al.* BMP Inhibition in Seminomas Initiates Acquisition of Pluripotency *via* NO-DAL Signaling Resulting in Reprogramming to an Embryonal Carcinoma. Kwiatkowski DJ, editor. *PLoS Genet* 2015; 11: e1005415.
9. Reuter VE. Origins and molecular biology of testicular germ cell tumors. *Mod Pathol* 2005;18 Suppl 2: S51-60.
10. Almstrup K, Nielsen JE, Mlynarska O *et al.* Carcinoma *in situ* testis displays permissive chromatin modifications similar to immature foetal germ cells. *Br J Cancer* 2010; 103: 1269-76.
11. Martin-Kleiner I. BORIS in human cancers – a review. *Eur J Cancer* 2012; 48: 929-35.
12. Okabayashi K, Fujita T, Miyazaki J *et al.* Cancer-testis antigen BORIS is a novel prognostic marker for patients with esophageal cancer. *Cancer Sci* 2012; 103: 1617-24.
13. D'Arcy V, Pore N, Docquier F *et al.* BORIS, a paralogue of the transcription factor, CTCF, is aberrantly expressed in breast tumours. *Br J Cancer* 2008; 98: 571-9.
14. Loukinov DI, Pugacheva E, Vatolin S *et al.* BORIS, a novel male germ-line-specific protein associated with epigenetic reprogramming events, shares the same 11-zinc-finger domain with CTCF, the insulator protein involved in reading imprinting marks in the soma. *Proc Natl Acad Sci U S A* 2002; 99: 6806-11.
15. Klenova EM, Morse HC, Ohlsson R, Lobanenko V V. The novel BORIS + CTCF gene family is uniquely involved in the epigenetics of normal biology and cancer. *Semin Cancer Biol* 2002; 12: 399-414.
16. Recillas-Targa F, De La Rosa-Velázquez IA, Soto-Reyes E, Benítez-Bribiesca L. Epigenetic boundaries of tumour suppressor gene promoters: the CTCF connection and its role in carcinogenesis. *J Cell Mol Med* 2006; 10: 554-68.
17. Novak Kujundžić R, Grbeša I, Ivkić M *et al.* Possible prognostic value of BORIS transcript variants ratio in laryngeal squamous cell carcinomas – a pilot study. *Pathol Oncol Res* 2014; 20: 687-95.
18. Zhao R, Chen K, Zhou J *et al.* The prognostic role of BORIS and SOCS3 in human hepatocellular carcinoma. *Medicine (Baltimore)* 2017; 96 :e6420.
19. Ehrlich Y, Margel D, Lubin MA, Baniel J. Advances in the treatment of testicular cancer. *Transl Androl Urol* 2015; 4: 381-90.
20. Feldman DR. Update in germ cell tumours. *Curr Opin Oncol* 2015; 27: 177-84.
21. Nguyen P, Bar-Sela G, Sun L *et al.* BAT3 and SET1A form a complex with CTCFL/BORIS to modulate H3K4 histone dimethylation and gene expression. *Mol Cell Biol* 2008; 28: 6720-9.
22. Campbell AE, Martinez SR, Miranda JL. Molecular architecture of CTCFL. *Biochem Biophys Res Commun* 2010; 396: 648-50.
23. Ogunkolade BW, Jones TA, Aarum J *et al.* BORIS/CTCFL is an RNA-binding protein that associates with polysomes. *BMC Cell Biol* 2013; 14: 52.
24. Looijenga LHJ, Stoop H, Biermann K. Testicular cancer: biology and biomarkers. *Virchows Arch* 2014; 464: 301-13.
25. Hoffmann MJ, Müller M, Engers R, Schulz WA. Epigenetic control of CTCFL/BORIS and OCT4 expression in urogenital malignancies. *Biochem Pharmacol* 2006; 72: 1577-88.
26. Link PA, Zhang W, Odunsi K, Karpf AR. BORIS/CTCFL mRNA isoform expression and epigenetic regulation in epithelial ovarian cancer. *Cancer Immun* 2013; 13: 1-9.
27. Renaud S, Loukinov D, Alberti L *et al.* BORIS/CTCFL-mediated transcriptional regulation of the hTERT telomerase gene in testicular and ovarian tumor cells. *Nucleic Acids Res* 2011; 39: 862-73.
28. Hong JA, Kang Y, Abdullaev Z *et al.* Reciprocal binding of CTCF and BORIS to the NY-ESO-1 promoter coincides with derepression of this cancer-testis gene in lung cancer cells. *Cancer Res* 2005; 65: 7763-74.
29. Zhang Y, Fang M, Song Y *et al.* Brother of Regulator of Imprinted Sites (BORIS) suppresses apoptosis in colorectal cancer. *Sci Rep* 2017; 7: 40786.
30. Cheema Z, Hari-Gupta Y, Kita G-X *et al.* Expression of the cancer-testis antigen BORIS correlates with prostate cancer. *Prostate* 2014; 74: 164-76.
31. Horibe R, Hirohashi Y, Asano T *et al.* Brother of the regulator of the imprinted site (BORIS) variant subfamily 6 is a novel target of lung cancer stem-like cell immunotherapy. *PLoS One* 2017; 12: 1-14.
32. Gonzalez-Exposito R, Merino M, Aguayo C. Molecular biology of testicular germ cell tumors. *Clin Transl Oncol* 2016; 18: 550-6.

S A Ž E T A K

IMUNOHISTOKEMIJSKA IZRAŽENOST PROTEINA BORIS U TUMORIMA ZAMETNIH STANICA TESTISA

A. MESIĆ¹, I. MILOŠEVIĆ², V. MILUNOVIĆ³, M. MILOŠEVIĆ⁴, M. ULAMEC^{5,6} i B. KRUŠLIN^{5,6}

¹Zavod za hitnu medicinu Krapinsko-zagorske županije, Krapina, ²Sveučilište u Zagrebu, Medicinski fakultet, Zagreb, ³Klinička bolnica Merkur, Zavod za hematologiju, Zagreb, ⁴Sveučilište u Zagrebu, Medicinski fakultet, Škola narodnog zdravlja "Andrija Štampar", Zagreb, ⁵Klinički bolnički centar "Sestre milosrdnice", Zavod za patologiju i citologiju, Zagreb i ⁶Sveučilište u Zagrebu, Medicinski fakultet, Zavod za patologiju, Zagreb, Hrvatska

BORIS (engl. *Brother of the Regulator of Imprinted Sites*) sudjeluje u unutarstaničnoj signalizaciji i kontrolira epigenetske mehanizme kao što su metilacija/demetilacija DNK i histona. Aktivacija BORIS-a dovodi do poremećaja određenih tumorskih supresora. Imunohistokemijska izraženost BORIS-a utvrđena je u različitim tumorima. U nekim tumorima nađena je korelacija s lošijom prognozom. *Cilj* ovoga istraživanja bio je utvrditi imunohistokemijsku izraženost BORIS-a u čistim seminomima i različitim komponentama miješanih tumora zametnih stanica testisa (engl. *mixed germ cell tumors*, MGCT). *Materijal i metode*: Analizirana je imunohistokemijska izraženost BORIS-a u tumorima zametnih stanica testisa (engl. *testicular germ cell tumors*, TGCT), a intenzitet bojenja i postotak reaktivnih stanica korišten je za evaluaciju razine ekspresije. Analizirani su uzorci tumora 44 bolesnika; 26 čistih seminoma i 18 MGCT. Kod MGCT-a komponenta seminoma nađena je u 4, *yolk sac*-a u 7, teratoma u 11 te embrionalnog karcinoma u 13 uzoraka tumora. *Rezultati*: Imunohistokemijska izraženost bila je jaka kod 80,8% čistih seminoma te kod 76,9% komponente embrionalnog karcinoma, 71,4% *yolk sac*-a, 63,6% teratoma i 25% seminomske komponente MGCT-a. Dobivena je pozitivna korelacija izraženosti BORIS-a teratomske komponente i prisutnosti komponente *yolk sac* ($\tau_b=0,574$, $p<0,02$). Također je uočena negativna korelacija izraženosti BORIS-a u teratomu i T stadiju bolesti ($\tau_b=0,559$, $p<0,02$). Između imunohistokemijske izraženosti BORIS-a u embrionalnom karcinomu i T stadiju bolesti dobivena je pozitivna korelacija ($\tau_b=0,471$, $p<0,04$). Povezanost izraženosti BORIS-a u različitim komponentama tumora nije pronađena. *Zaključak*: Ovi rezultati pokazuju potencijalnu važnost određivanja ekspresije BORIS-a te mogući doprinos u poboljšanju dijagnosticiranja i moguće terapije tumora zametnih stanica testisa.

Ključne riječi: BORIS, tumori zametnih stanica testisa, imunohistokemija, biomarkeri