

Leptospirosis – associated hemorrhagic pneumonitis successfully treated by venovenous extracorporeal membrane oxygenation: a case report

Hemoragijski pneumonitis tijekom leptospiroze uspješno liječen venovenskom izvantjelesnom membranskom oksigenacijom: prikaz bolesnika

Marko KUTLEŠA
Branimir GJURAŠIN

University Hospital for Infectious Diseases
“Dr. Fran Mihaljević” Zagreb

Key words

leptospirosis
pneumonitis
extracorporeal venovenous membrane oxygenation

Ključne riječi

leptospiroza
pneumonitis
venovenska izvantjelesna membranska oksigenacija

Primljeno: 2017–11–26

Received: 2017–11–26

Prihvaćeno: 2017–12–19

Accepted: 2017–12–19

Case report

Leptospirosis is an endemic zoonosis of continental parts of Croatia with a seasonal distribution pattern. On some occasions, in the infection's severe form (Weil's disease), acute respiratory distress syndrome with pulmonary hemorrhage can occur. Here we present a case of Weil's disease with multiorgan failure, including hemorrhagic pneumonitis. The patient was successfully treated by veno-venous extracorporeal membrane oxygenation, with standard anticoagulation, without enhancing the risk of bleeding, despite hemorrhagic pneumonitis in leptospirosis.

Prikaz bolesnika

Leptospiroza je endemska zoonoza kontinentalne Hrvatske sa sezonskom distribucijom. Teški oblik bolesti, poznat kao Weilova bolest, može se komplicirati akutnim respiratornim distres sindromom i hemoragijskim pneumonitisom. Prikazujemo bolesnicu s Weilovom bolesti i multiorganskim zatajenjem koje je uključivalo teški hemoragijski pneumonitis. Uspriješno je liječena uz pomoć venovenske izvantjelesne membranske oksigenacije koristeći standardne antikoagulacijske mjere.

Introduction

In continental parts of Croatia leptospirosis is endemic and shows a seasonal distribution pattern. Although pulmonary involvement is not uncommon (in 20 to 70 % of cases in different series), on some occasions in the infection's severe form (Weil's disease), acute respiratory distress syndrome (ARDS) with pulmonary hemorrhage can occur – the frequency of such involvement has been on the rise and is becoming the main cause of death from the disease. Mortality rates for severe lung involvement may be as high as 50 %.

Here we present a case of Weil's disease with multiorgan failure, including hemorrhagic pneumonitis, successfully treated by veno-venous extracorporeal membrane oxygenation (VV-ECMO).

Case report

A 72-year-old female patient without significant comorbidities presented in March 2016 with a five day history of fever, sore throat, malaise, dyspnoea, mild diarrhea and nausea. She came from a rural part of northern Croatia and reported daily contact with bulls. On admission she was icteric, tachydispnoic, febrile, hypoxemic (SpO₂ 77 %), GCS 15. Initial laboratory tests revealed leukocytosis ($14.6 \times 10^9/L$), anemia (hgb 103 g/L), thrombocytopenia ($40 \times 10^9/L$), elevated CRP (293.9 mg/L), procalcitonin (44.6 µg/L), CK (548 U/L), kidney injury (BUN 17.7 mmol/L, creatinine 357 µmol/L) and conjugated hyperbilirubinemia (75 µmol/L). The chest radiograph showed bilateral confluent parenchymal infiltrates (Figure 1). She was admitted to the intensive care unit where empirical antimicrobial therapy consisted of ceftriaxone, flucloxa-

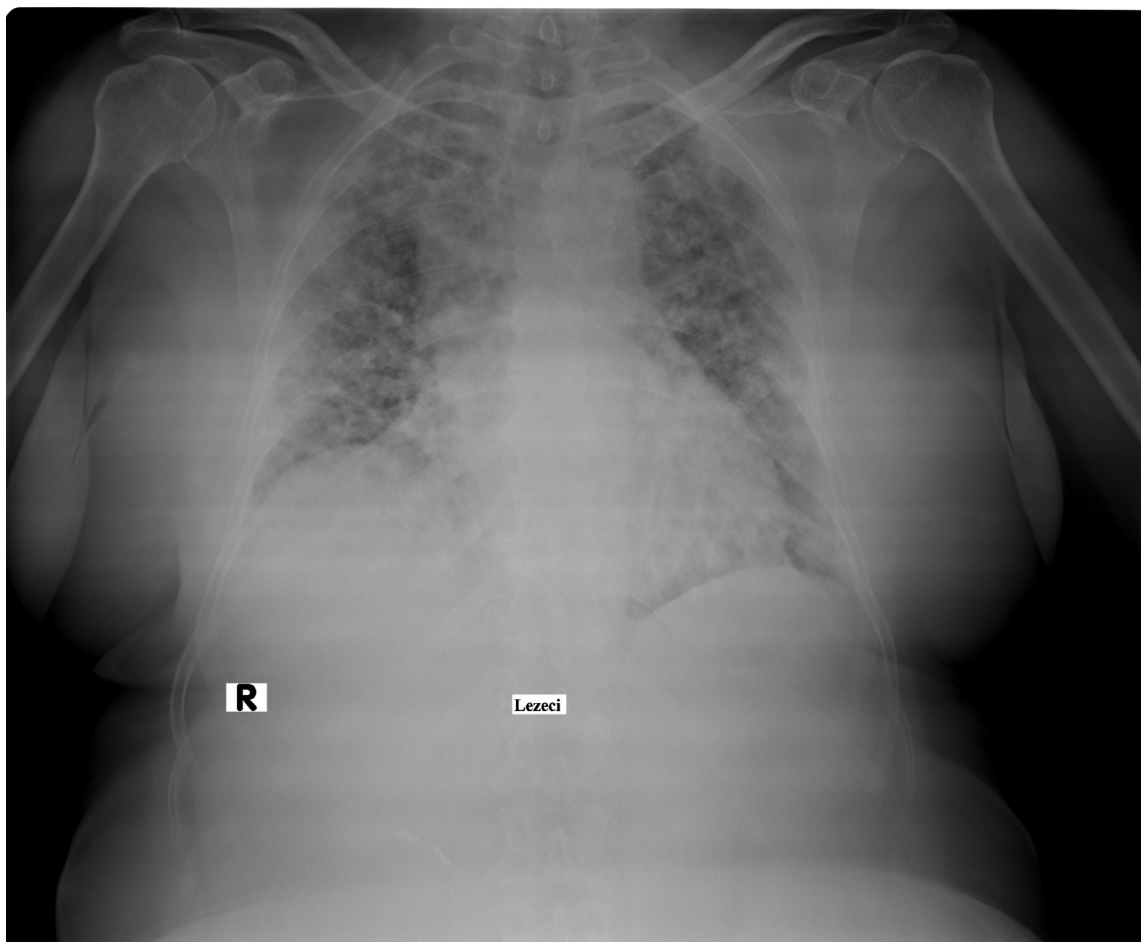


Figure 1. Bilateral confluent parenchymal patchy infiltrates – acute respiratory distress syndrome (ARDS)

Slika 1. Bilateralni konfluirajući infiltrati parenhima – akutni respiratorni distres sindrom (ARDS)

cillin and oseltamivir. Also, she was started on i.v. methylprednisolone. The next morning the patient's condition worsened with a progression of respiratory failure prompting mechanical ventilation (MV). Due to the refractory hypoxemic respiratory failure (pH 7.1, pCO₂ 40 mmHg, pO₂ 47 mmHg, pO₂/FiO₂ 47) necessitating aggressive MV which could not accomplish adequate oxygenation (PEEP 12, FiO₂ 100 %, plateau pressure >30 cm H₂O, oxygenation index 46.8), VV-ECMO was started, as well as continuous renal replacement (CVVHDF). The following day PCR of both serum and urine came positive for *Leptospira* spp and the antimicrobial treatment was de-escalated to ceftriaxone. Subsequently, leptospirosis was also confirmed in paired sera by microscopic agglutination test. The total duration of VV-ECMO, MV, CVVHDF, ceftriaxone and methylprednisolone treatment was 6, 10, 15, 10 and 10 days, respectively. During the remainder of the hospitalization the patient's respiratory, renal and other functions recovered and she was discharged after 6 weeks in good general condition (GOS 5, Karnofsky score 80 %).

Discussion

Leptospirosis can manifest as a severe illness with high morbidity leading to multiple organ dysfunction syndrome. It can present with a wide range of symptoms, mimicking flu, hepatitis, dengue, hanta virus cardiopulmonary syndrome, meningitis, among others, and has a specific treatment; thus, clinical suspicion must remain high and serological and molecular diagnosis should be performed. Given the fact that leptospirosis is endemic throughout the world, a clinician should be familiar in recognizing and treating the infection's severe form which can also be accompanied by ARDS and pulmonary hemorrhage. It should be remembered that not all cases of pulmonary hemorrhage have a vasculitic cause – infectious diseases should be considered in the differential diagnosis because early, adequate, targeted therapy in combination with supportive treatment and, possibly, corticotherapy will improve survival. The most frequent infections causing pulmonary hemorrhage (diffuse alveolar hemorrhage) in immunocompetent patients are influenza, dengue, lep-

tospirosis, malaria, and *S. aureus* pneumonia. In severe presentations, supportive therapies are essential for survival, considering that multiorgan failure is typically completely reversible. As a last resort for treating severe ARDS and pulmonary hemorrhage of any etiology, clinicians may need to use VV-ECMO if mechanical ventilation does not suffice. VV-ECMO is a method of pulmonary support that allows the lung to be relieved of its gaseous exchange function minimizing the degree of lung injury caused by MV with high FiO₂, high tidal volumes and increased airway pressures needed in severe respiratory failure and ARDS, ensuring protective ventilation without further compromising oxygen delivery or acid base balance. The benefits of ECMO use in hemorrhagic pneumonitis and ARDS in leptospirosis are still under evaluation. The importance of careful case selection has become clear. Our patient had no significant comorbidities and was started on VV-ECMO relatively early (on the sixth day of her illness, i.e. the following day after admission). VV-ECMO support was discontinued after six days, and the patient eventually had full recovery.

This case report shows the importance of the fact that VV-ECMO should be considered early as an option in adult patients with severe respiratory failure especially if the underlying cause is infective and therefore ultimately curable. Finally, this case report shows that VV-ECMO can be safely used with standard anticoagulation, without enhancing the risk of bleeding, despite hemorrhagic pneumonitis in leptospirosis.

References

- [1] Bennett JE, Dolin R, Blaser MJ, et al. Mandell, Douglas, and Bennett's principles and practice of infectious diseases. 8. izd. Philadelphia, PA: Elsevier/Saunders; 2015.
- [2] Vinetz JM. Leptospirosis. *Current Opin Infect Dis*. 2001;14(5):527–38.
- [3] Bharti AJ, Nally JE, Ricaldi JN, Mathias MA, Diaz MM. et al. Leptospirosis: a zoonotic disease of global importance. *The Lancet*. 2003;3:757–71.
- [4] vonRanke FM, Zanetti G, Hochegger B, Marchiori E. Infectious diseases causing diffuse alveolar hemorrhage in immunocompetent patients: a state-of-the-art review. *Lung* 2013; 191:9.
- [5] Segura ER, Ganoza CA, Campos K, et al. Clinical spectrum of pulmonary involvement in leptospirosis in a region of endemicity, with quantification of leptospiral burden. *Clin Infect Dis* 2005; 40:343.
- [6] Chen-Yi Liao et al. Acute Respiratory Distress Syndrome Manifested by Leptospirosis Successfully Treated by Extracorporeal Membrane Oxygenation (ECMO). *Intern Med* 2015; 54: 2943–2946.
- [7] D. Arokianathan et al. Leptospirosis: a case report of a patient with pulmonary haemorrhage successfully managed with extra corporeal membrane oxygenation. *J Infect* 2005; 50:158–162.
- [8] Cantwell T et al. Leptospirosis-associated catastrophic respiratory failure supported by extracorporeal membrane oxygenation. *J Artif Organs*. 2017;20(4):371–376.
- [9] Rodrigo C, Lakshitha de Silva N, Goonaratne R, et al. High dose corticosteroids in severe leptospirosis: a systematic review. *Trans R Soc Trop Med Hyg* 2014; 108:743.
- [10] B. Dželalija, A. Medić, I. P. Novosel, S. Sablić: Zoonoze u Republici Hrvatskoj. *Infektol Glas* 2015;35 (2-3):45–51.

