

Images in Infectious Diseases

Slike u infektivnim bolestima

Nocardia brain abscesses

Nokardijski moždani apscesi

Marija Kusulja, Vladimir Krajinović, Klaudija Višković

University Hospital for Infectious Diseases "Fran Mihaljević", Mirogojska cesta 8, Zagreb, Croatia

Primljeno: 2016–10–12

Received: 2016–10–12

Prihvaćeno: 2016–12–17

Accepted: 2016–12–17

Nocardiosis is a rare infection with gram-positive aerobic rods of *Nocardia* genus. Immunocompromised patients are at increased risk; however, one third of patients reported to have this infection are immunocompetent. The finding of *Nocardia* in any human sample is always a pathological finding. It can cause a localized or disseminated

infection of any organ, and can progress despite adequate therapy. It can also recur years after successful treatment. Antimicrobial treatment usually lasts for 3 months in cases of isolated cutaneous infection and 12 months or longer in central nervous system involvement and in immunocompromised patients. In patients not responding to antimicrobial therapy, empyema formation and pulmonary nocardiosis with pericarditis, surgical treatment is frequently necessary.

A 71-year-old male patient presented at the emergency room of the University Hospital Centre Zagreb with twitching of his left arm and left side of face lasting 30 minutes, terminating after intravenous application of 10 mg of diazepam. He complained of having pins and needles in his left arm for the past two months. His previous

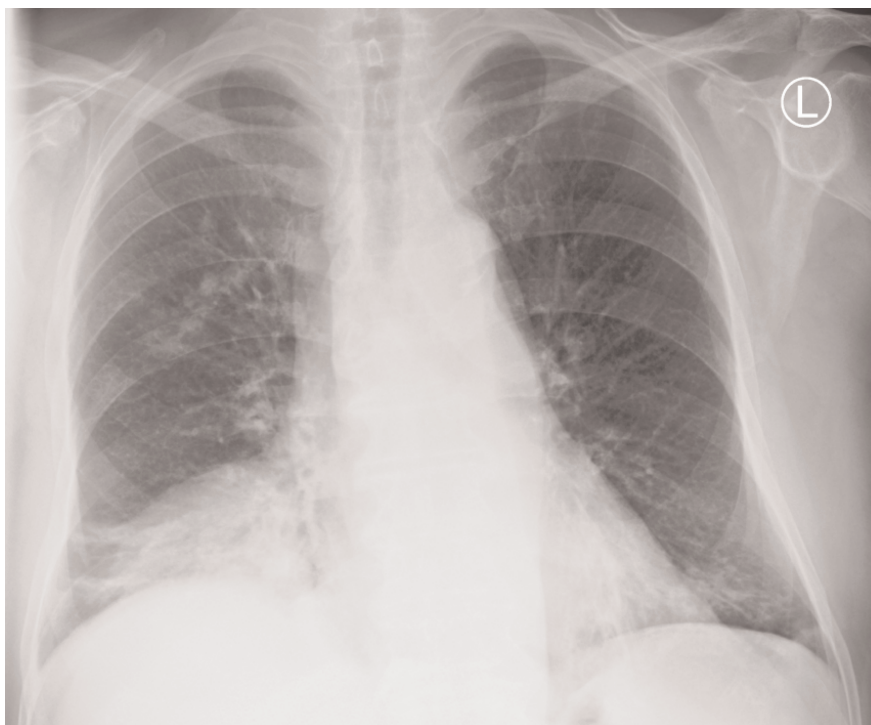

Figure 1. Preoperative antero-posterior chest X-ray image revealed multiple right-sided basal infiltrates which were consistent with asymptomatic pulmonary nocardiosis

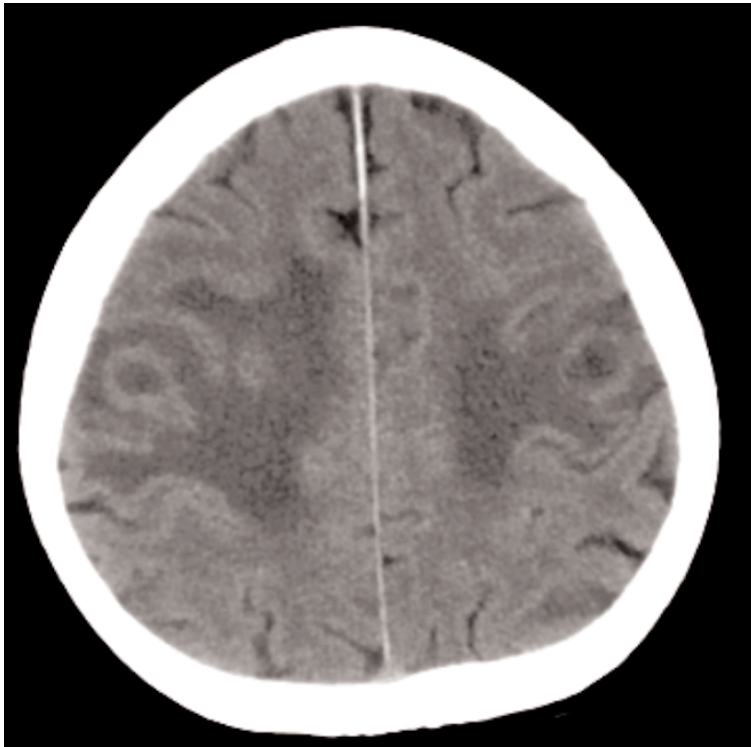


Figure 2. Postcontrast brain multislice computerized tomography (MSCT): bilateral parietal focal lesions measuring 12 mm and 23 mm in diameter with postcontrast right enhancement, surrounded with perifocal edema

medical history included nephrotic syndrome caused by minimal-change disease, for which he had been taking prednisolone for the past 11 years, and iatrogenic diabetes mellitus. He also underwent surgical treatment due to right knee swelling three months earlier. During preoperative work-up chest X-ray was performed and lung infiltrates were discovered (Fig. 1). The patient's blood was cultured, revealing *Nocardia* spp. He was treated with amikacin and thrimetoprim sulfamethoxazole (TMP/SMX) for the next five weeks, continuing peroral TMP/SMX after discharge.

Since the patient complained of neurological symptoms at this most recent admission, a native and postcontrast brain multislice computerized tomography (MSCT) and brain magnetic resonance imaging (MRI) were performed, showing multiple brain abscesses (Fig. 2 and 3). According to this finding, the patient was transferred to the University Hospital for Infectious Diseases (UHID) in Zagreb. His blood cultures once again grew *Nocardia*, this time specified as *N. cyriacigeorgica*, which was resistant to ciprofloxacin, intermediately susceptible to co-amoxi-

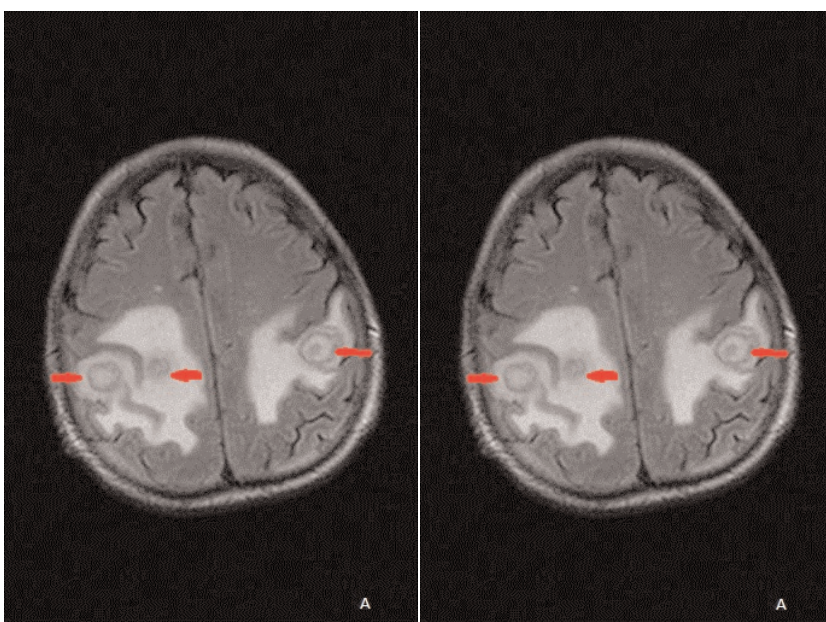


Figure 3. Brain MRI, A-Fluid Attenuation Inversion Recovery (FLAIR) sequence; B-post contrast T1 Weighted Image (WI), revealed multiple focal lesions with post contrast ring enhancement (arrows) and surrounding edema; consistent with abscesses in parietal lobes bilaterally

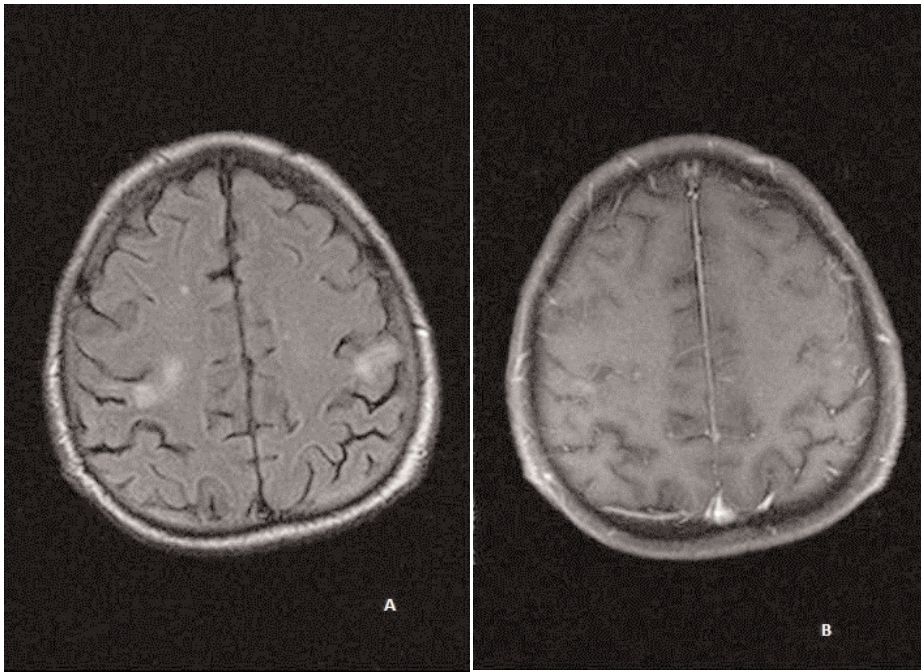


Figure 4. Follow up brain MRI, A-Fluid Attenuation Inversion Recovery (FLAIR) sequence; B-post contrast T1 Weighted Image (WI), showed complete regression of focal lesions and surrounding edema in parietal lobes bilaterally

clav and susceptible to tetracyclines with a MIC of 0.25 mcg/mL. Treatment with TMP/SMX, amikacin and imipenem was started, and after six weeks a neurosurgeon was consulted who saw no indication for surgical intervention. The patient was discharged with recommendation to continue peroral therapy with TMP/SMX and

doxycycline. On 7-month follow-up, the patient was subjectively well, with no complaints except occasional frontal headaches. His follow-up brain MRI showed significant regression of all brain abscesses, as well as the perifocal edema (Fig. 4). Total planned duration of treatment was 2 years.

