

## Necrolytic Migratory Erythema: Complete Healing after Surgical Removal of Pancreatic Carcinoma

**Marija V'lickova-Laskoska, Margareta Balabanova-Stefanova, Irina Arsovska-Bezhoska, Nina Caca-Biljanovska, Dimitri Laskoski**

Department of Dermatology, University of Skopje, Skopje, Republic of Macedonia

### Corresponding author:

Professor Marija V'lickova-Laskoska, MD, PhD  
Department of Dermatology  
University Hospitals and Clinics  
University of Sts. Cyril and Methodius  
Vodnjanska 17  
1000 Skopje  
Macedonia  
[pirinska40@gmail.com](mailto:pirinska40@gmail.com)

Received: February 6, 2018

Accepted: November 15, 2018

**ABSTRACT** Necrolytic migratory erythema is considered an obligatory cutaneous paraneoplastic sign associated with glucagonoma. Glucagonoma syndrome is defined by the presence of an alpha-cell secreting tumor of the pancreas, elevated levels of glucagon, and a characteristic rash called necrolytic migratory erythema. Although necrolytic migratory erythema is a specific finding in glucagonoma syndrome, it may occur in other settings, unassociated with an alpha-cell pancreatic tumor (pseudoglucagonoma syndrome). The rarity of glucagonoma imposes a challenge, with most patients being diagnosed after a long period of treatment for their skin rash. The main prognostic sign of glucagonoma are the subsequent metastases that come late in the course of the disease. Herein, we present a 55-year-old female patient with a 5-year history of unrecognized cutaneous and systemic manifestations of glucagonoma syndrome. Based on the investigations, the diagnosis of glucagonoma syndrome without metastases was established. After surgical removal of pancreatic carcinoma/glucagonoma, complete healing and a long disease-free period was achieved. Appropriate awareness of the characteristics of necrolytic migratory erythema in physicians/dermatologists often leads to an early diagnosis of glucagonoma syndrome and enhances the chances of a favorable outcome.

**KEY WORDS:** necrolytic migratory erythema, glucagonoma, glucagonoma syndrome

### INTRODUCTION

The first association between a cutaneous rash and pancreatic neoplasm was observed in 1942 by Becker *et al.* (1). In 1973 Wilkinson defined the term "necrolytic migratory erythema" to describe the distinctive rash (2). Mallinson *et al.* (3) coined the term "glucagonoma syndrome", a rare paraneoplastic phenomenon in patients with necrolytic migratory erythema, glucagonoma, and weight loss.

Glucagonoma is an extremely rare, slow-growing, frequently malignant neuroendocrine tumor of the alpha-cells of the pancreas, whereby abundant glucagon is secreted. Estimated incidence is 1/20,000,000/year (4). It typically presents with glucagonoma syndrome (GS).

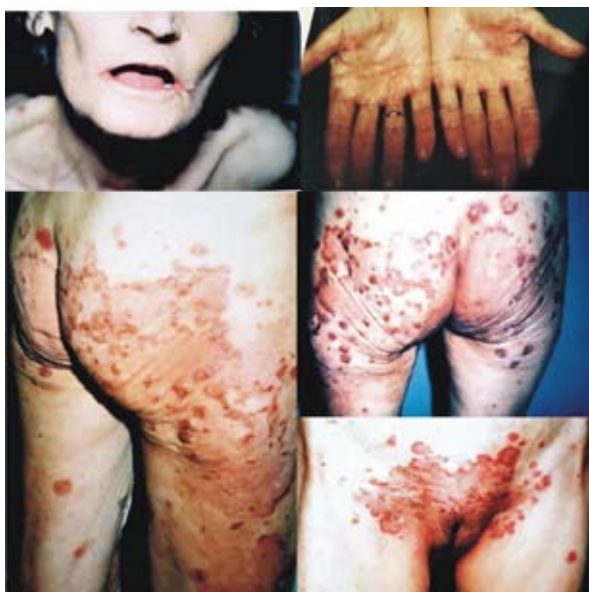Necrolytic migratory erythema (NME) is considered a hallmark clinical sign of glucagonoma syndrome, present in approximately 70% of patients (5).

Considered an obligatory paraneoplastic sign, NME can be observed in the absence of glucagonoma in so called pseudoglucagonoma syndrome (6). In this condition, levels of glucagon are commonly elevated due to another disease of non-pancreatic origin, such as intestinal malabsorption disorders, cirrhosis, inflammatory bowel disease, pancreatitis, and other malignancies (7,8).

Clinically, NME is distinctive, pruritic, bullous dermatosis that evolves over a 2-week period and has a

cyclic course with spontaneous remissions and exacerbations. Individual lesions are pruritic and painful, initially appearing as erythematous vesicles and bullae that evolve into patches or plaques with irregular borders, scaling, and crusting, sometimes with an eczematous and psoriasiform appearance as they fade. Such a clinical aspect can mimic inverse psoriasis, eczema, intertrigo, contact dermatitis, seborrheic dermatitis and even pemphigus (4,9). After the vesicles and bullae rupture, they spread outward with crusting and postinflammatory, residual hyperpigmentation. The distribution may be widespread or isolated to the perioral region, trunk, buttocks, groin, intergluteal region, genital area, lower extremities, palms, or fingers. It preferentially forms in intertriginous areas and pressure points; it can also form in areas of trauma, a response pattern known as "koebnerization". Glossitis, angular cheilitis, and stomatitis are associated mucosal manifestations. Diffuse alopecia and brittle nails can be observed. Skin changes appear early in the course of GS and are reason for seeking medical help for the first time. They are followed by systemic symptoms such as weight loss, diarrhea, diabetes mellitus, neuropsychiatric disorders, anemia, and thrombosis.

We report a case of female patient with a 5-year history of cutaneous rash and systemic symptoms consistent with GS, without liver metastases. She was successfully operated on with a subsequent long disease-free period. This case is an example of the well-



**Figure 1.** Necrolytic migratory erythema: angular cheilitis, glossitis; multiple, annular, circinate, erythematous patches with superficial scaling at the borders involving the thighs, buttocks, palms, perineum, genital area, groin, and lower abdomen.

established association between NME and GS and also emphasizes the importance of early detection of pancreatic carcinoma and prevention of its fatal metastases.

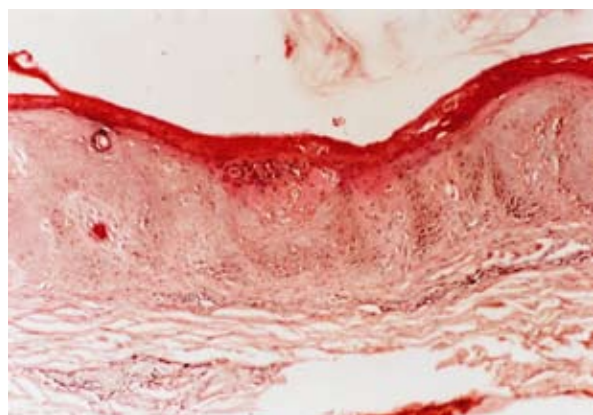
### CASE REPORT

A 55-year-old woman presented to the dermatologist complaining of a erythematous pruritic skin rash of a 5-year duration. The skin rash tended to occur in recurrent crops that later blistered and sloughed while new lesions occurred in another area. She also reported a painful, red, shiny smooth tongue, perioral rhagades, anorexia, insomnia, diarrhea (sporadically), and significant weight loss in the last year. Her family history was negative for endocrine disorders.

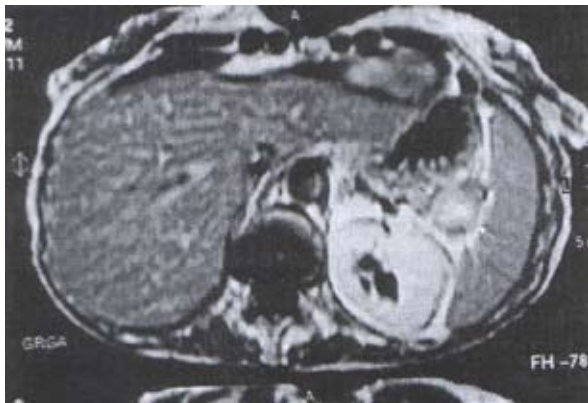Physical examination revealed an annular-circinate, erythematous, scaly rash with areas of hyperpigmentation and skin sloughing, mainly involving the extremities, buttocks, and perineum. The lesions were highly suggestive of NME. Her tongue was atrophic and bright red (glossitis), and cheilitis angularis was visible. Severe cachexia was registered (36 kg/150 cm) (Figure 1).

Skin biopsy from the lesion showed psoriasiform hyperplasia of the epidermis with overlying parakeratosis, slight spongiosis, subcorneal spongiform pustules, and rare necrotic spinous cells. Discrete superficial perivascular infiltrate of lymphocytes and neutrophils was present in the papillary dermis. (Figure 2).

Laboratory investigations had the following results: elevated sedimentation rate (70/100); serum glucose, liver function tests, plasma proteins, enzymes, and electrolytes were all normal, but normochromic-normocytic anemia and hyperglucagone-



**Figure 2.** Histopathology of the skin lesion (hematoxylin and eosin): parakeratosis, psoriasiform epidermis with slight spongiosis, subcorneal spongiform pustules, and rare necrotic spinous cells. Discrete superficial perivascular dermal infiltrate of lymphocytes and neutrophils.



**Figure 3.** MRI of glucagonoma: the coronal T2-weighted image of the abdomen after IV-applied contrast, depicting the tumor mass as a high-intensity abnormality (3.0 cm × 2.5 cm) in the tail of the pancreas, lying at the splenic hilum.

nia were found. Glucagon level assay (EDTA-plasma) in two plasma samples taken during two separate exacerbations of skin rash showed elevated values: 386 ng/L; 290 ng/L; (normal range for adults 70-160 ng/L). Kidney function tests were normal.

Abdominal ultrasound revealed a hypoechoic mass in the tail of the pancreas. Accordingly, contrast-enhanced magnetic resonance imaging (MRI) in T1 and T2 pulse sequences was performed. The coronal T1-weighted magnetic image of the upper abdomen confirmed the presence of a low intensity abnormality in the tail of the pancreas. The coronal T2-weighted image of abdomen, after IV-applied contrast, showed that the described abnormality had a tendency to be hyperintensive. The tumor mass was depicted as a high-intensity abnormality (3.0 cm × 2.5 cm) in the tail of the pancreas, lying at the splenic hilum (Figure 3).

The first pancreatic surgery was unsuccessful, and the patient underwent a second surgery in which the tumor was successfully removed (distal pancreatectomy with splenectomy). Three months after the operation, glucagon levels were reduced to normal (86 ng/L) and the skin rash disappeared. Healing resulted in transitory residual hyperpigmentation. Histopathological examination confirmed the diagnosis of a pancreatic neuroendocrine tumor. During 7-year follow-up the patient has been completely disease-free and in excellent health.

## DISCUSSION

GS is an extremely rare condition with an estimated annual incidence of 1/20,000,000 (4). Consequently, only a few surgeons and physicians will be faced with this peculiar diagnosis. Diagnosis of GS is based on clinical findings that include NME, elevated

serum levels of glucagon, and an underlying islet-cell tumor within the pancreas that is secreting glucagon. All these criteria were fulfilled in the presented case. The major diagnostic criteria of GS are: imaging study confirming presence of pancreatic tumor, elevated glucagon levels, NME, and personal history of multiple endocrine neoplasia typ-1 (MEN) (10).

Histologically, Kheir *et al.* (11) analyzed nine biopsy specimens and distinguished five patterns of morphologic characteristics in NME: epidermal necrosis (vacuolated, pale, and swollen epidermal cells), subcorneal pustules, psoriasiform pattern, angioplasia or vascular dilatation of the papillary dermis, and suppurative folliculitis. Despite attempts to characterize the histopathological features of NME, they still remain nonspecific, and epidermal necrosis of the upper spinous layer is considered the best diagnostic sign. At the same time, its presence includes histologic differential diagnosis such as zinc deficiency (acrodermatitis enteropathica), niacin deficiency (pellagra), and NME (seen in chemotherapy settings) (12). The histopathology in our case was consistent with the above (11). On the other hand, histopathology of glucagonomas does not differ from other neuroendocrine tumors, but tumor cells of glucagonoma still show granulated abundant cytoplasm (13).

The pathogenesis of the disease is mainly due to the elevated level of serum glucagon that induces inflammatory mediators in the skin, which are responsible for epidermal necrosis. The evidence of this theory lies in the fact that surgical removal of glucagonomas or glucagonomas treated with a glucagon antagonist leads to resolution of the skin lesions. This was evident in our patient. Liver diseases can produce the same skin damage because of the decreased capacity of the liver to degrade glucagon. Zinc deficiency, protein deficiency, selective amino acid, or essential fatty acid deficiency may alter the metabolic pathway in the skin independently of glucagonoma, which also leads to clinical manifestation of NME (14).

Glucagonoma tends to grow slowly compared to non-islet cell pancreatic adenocarcinoma. Later in the course of the disease, glucagonoma metastasizes most commonly to the liver, followed by peripancreatic lymph nodes. Metastases are in fact the main negative prognostic factor for glucagonoma (4). Between 50% and 90% of well-differentiated glucagonomas have metastasized by the time of diagnosis (15). Surgical resection of the primary tumor is the definitive treatment for glucagonoma syndrome, although chemotherapeutic agents, somatostatin analogues, and radionuclide therapy are also employed (16).

## CONCLUSION

The observed patient was diagnosed just in time, before metastases occurred. She underwent successful surgery of a carcinoma with a subsequent long disease-free period. In general, most reported cases of glucagonoma are malignant, with many patients presenting with metastatic disease. That is why we believe our case is very instructive and could raise the awareness of the need for prompt recognition of NME, accurate diagnosis, and prevention of metastases of this tumor. In fact, the complete resection of the primary tumor offers the only chance of a cure.

## References:

1. Braverman IM. Cutaneous manifestations of internal malignant tumors by Becker, Kahn and Rothman, June 1942. *Arch Dermatol.* 1982;118:784-98.
2. Wilkinson DS. Necrolytic migratory erythema with carcinoma of the pancreas. *Trans St Johns Hosp Dermatol Soc.* 1973;59:244-50.
3. Mallinson CN, Bloom SR, Warin AP, Salmon PR, Cox B. A glucagonoma syndrome. *Lancet.* 1974;2:1-5.
4. Wei J, Lin S, Wang C, Wu J, Qian Z, Dai C, *et al.* Glucagonoma syndrome: a case report. *Oncol Lett.* 2015;10:1113-6.
5. Eldor R, Glaser B, Fraenkel M, Doviner V, Salmon A, Gross DJ. Glucagonoma and the glucagonoma syndrome - cumulative experience with an elusive endocrine tumour. *Clin Endocrinol (Oxf).* 2011;74:593-8.
6. Echenique-Elizondo M, TuneuVallas A, Elorza Orúe JL, Martínez de Lizarduy I, Ibáñez-Aguirre J. Glucagonoma and pseudoglucagonoma syndrome. *JOP.* 2004;5:179-85.
7. Mullans EA, Cohen PR. Iatrogenic necrolytic migratory erythema: a case report and review of nonglucagonoma-associated necrolytic migratory erythema. *J Am Acad Dermatol.* 1998;38:866-73.
8. Blackford S, Wright S, Roberts DL. Necrolytic migratory erythema without glucagonoma: the role of dietary essential fatty acids. *Br J Dermatol.* 1991;125:460-2.
9. Fang S, Li S, Cai T. Glucagonoma syndrome: a case report with focus on skin disorders. *Onco Targets Ther.* 2014;7:1449-53.
10. Stacpoole PW. The glucagonoma syndrome: clinical features, diagnosis and treatment. *Endocr Rev.* 1981;2:347-61.
11. Kheir SM, Omura EF, Grizzle WE, Herrera GA, Lee I. Histologic variation in the skin lesions of the glucagonoma syndrome. *Am J Surg Pathol.* 1986;10:445-53.
12. Halvorson SA, Gilbert E, Hopkins RS, Liu H, Lopez C, Chu M, *et al.* Putting the pieces together: necrolytic migratory erythema and the glucagonoma syndrome. *J Gen Intern Med.* 2013;28:1525-9.13.
13. Johnson SM, Smoller BR, Lamps LW, Horn TD. Necrolytic migratory erythema as the only presenting sign of a glucagonoma. *J Am Acad Dermatol.* 2003;49:325-8.
14. Tierney EP, Badger J. Etiology and pathogenesis of necrolytic migratory erythema: review of the literature. *Med Gen Med.* 2004;6:4.
15. Ito T, Igarashi H, Jensen RT. Therapy of metastatic pancreatic neuroendocrine tumors (pNETs): recent insights and advances. *J Gastroenterol.* 2012;47:941-60.
16. John AM, Schwartz RA. Glucagonoma syndrome: a review and update on treatment. *J Eur Acad Dermatol Venerol.* 2016;30:2016-22.