

## Glomeruloid Hemangioma as a Late Manifestation of POEMS Syndrome

**Gustavo Moreira Amorim, Celso Sodré, Eduardo Mastrangelo Marinho Falcão, Renata Fernandes Timbó, Tullia Cuzzi, Marcia Ramos-e-Silva**

University Hospital and School of Medicine, Federal University of Rio de Janeiro, Rio de Janeiro, Brazil

### Corresponding author:

Professor Marcia Ramos-e-Silva, MD, PhD

Rua Dona Mariana 143 / C-32

Rio de Janeiro 22280-020

Brazil

[ramos.e.silva@dermato.med.br](mailto:ramos.e.silva@dermato.med.br)

Received: October 26, 2017

Accepted: October 25, 2018

**ABSTRACT** Glomeruloid hemangiomas were first described by Chan in 1990 as a cutaneous marker of POEMS syndrome (Polyneuropathy, Organomegaly, Endocrinopathy, Monoclonal proteinemia, and Skin changes). POEMS syndrome is a multisystem disease with a significant cutaneous involvement. Among its manifestations, hemangiomas are common, observed in up to one third of the patients, and, although specific, the glomeruloid subtype is very rare. The vascular endothelium growth factor (VEGF) is an angiogenic stimulation factor, which also induces increased systemic vascular permeability. Thus, a scenario of overexpression of VEGF can credibly lead to the assumption of an association between cutaneous hemangiomas and systemic manifestations, implying prognostic and therapeutic considerations and reinforcing the importance of dermatological periodical consultations for these patients. We report the case of a patient in whom glomeruloid hemangiomas marked the recurrence of POEMS syndrome, occurring before the systemic symptoms.

**KEY WORDS:** POEMS syndrome, glomeruloid hemangioma, vascular endothelium growth factor, VEGF

### INTRODUCTION

The description of a clinical condition that combines peripheral polyneuropathy and monoclonal gammopathy dates back to 1938, when it was termed osteosclerotic myeloma and Crown-Fukase syndrome. It was only in 1980 that Bardwick established the acronym POEMS, encompassing the main manifestations of the syndrome: 1. Polyneuropathy; 2. Organomegaly; 3. Endocrinopathy; 4. Monoclonal proteinemia, and 5. Skin changes (1-4).

It is considered a rare entity, with under-researched incidence and prevalence. It affects men (2:1) more frequently in the 5th and 6th decade, and most cases are described in Japanese patients (5,6).

Its cause is unknown. Some of the manifestations are associated with tissue and organs infiltra-

tion by monoclonal immunoglobulin, while others seem a consequence of increased cytokine production. Among them, interleukin 1 beta, interleukin 6, tumor necrosis factor-alpha, and vascular endothelial growth factor (VEGF) appear to be especially important (1,2).

To establish the diagnosis of POEMS syndrome, the patient should satisfy both major criteria: polyneuropathy and plasmocyte monoclonal gamopathy associated with at least one minor criterion that includes osteoclastic lesions, Castelman disease, organomegaly (spleen, liver, lymph nodes), volume overload (peripheral edema, ascites, pleural effusion), endocrinopathy (thyroid, adrenals, hypophysis, pancreas, gonads, parathyroid), skin alterations

(hyperpigmentation, plethora, hemangioma, hypertrichosis), and papilledema (1,2). Cutaneous alterations comprise minor criteria but are present very frequently (2), with the most common being: 1. diffuse cutaneous hyperpigmentation (85%), 2. hypertrichosis (78%), and 3. sclerodermiform cutaneous thickening (85%) (5).

About a third of patients with POEMS have cutaneous hemangiomas. The following subtypes have been described: 1. microvenular; 2. *rubi nevus* or red mole; 3. multinucleated cell angiohistiocytes; 4. glomeruloid hemangioma (GH) (5,6).

GH are dome-shaped erythematous-purplish papules, usually multiple, prevalent in the trunk and proximal region of the upper limbs. They were described by Chan *et al.* in 1990 and were even proposed as a cutaneous marker of POEMS syndrome (7,8). Despite being specific for POEMS, they are quite

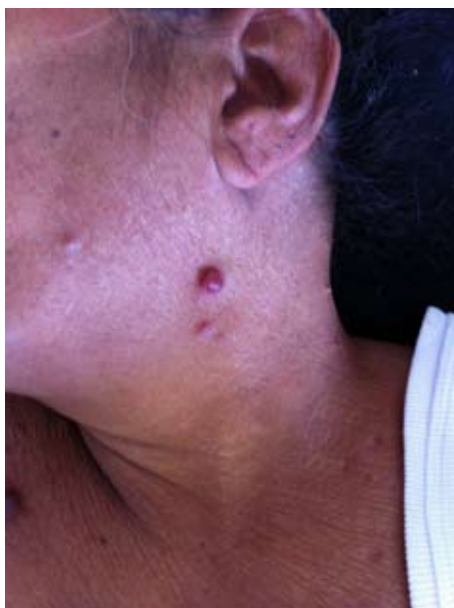rare, occurring in 3% of cases (6). GH can also occur outside POEMS syndrome (9).

We present a case of relapsed POEMS syndrome after control with a bone marrow transplant six years earlier. The first manifestation of the recurrence was the appearance of GHs.

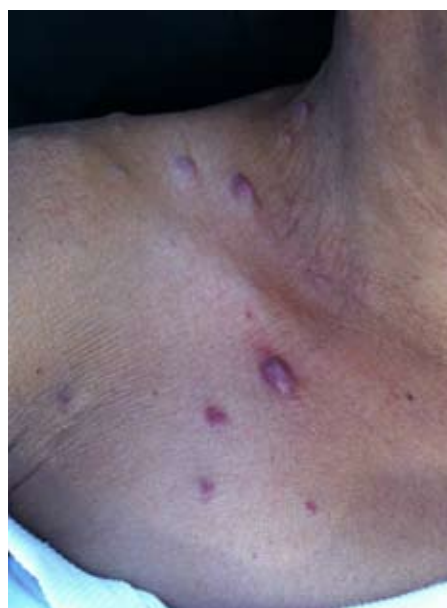### CASE REPORT

A 47-year-old woman, hospitalized due to progressive dyspnea with onset 2 months earlier, reported symptoms at slightest physical efforts. Concurrently, she complained of papular lesions on the trunk, which had appeared 4 months earlier with rapid progression, both in number and size of the lesions.

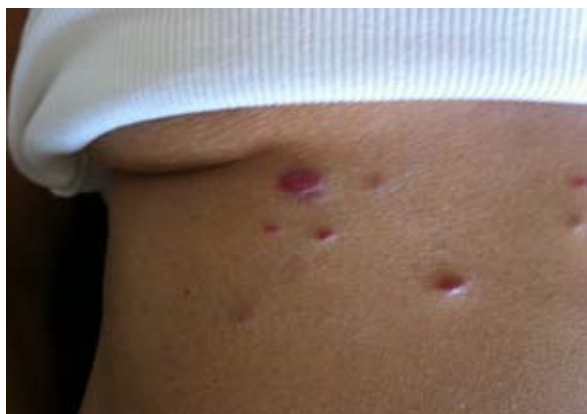The patient was hypertensive and had POEMS syndrome for 11 years, with peripheral neuropathy associated with monoclonal gammopathy, Castle-



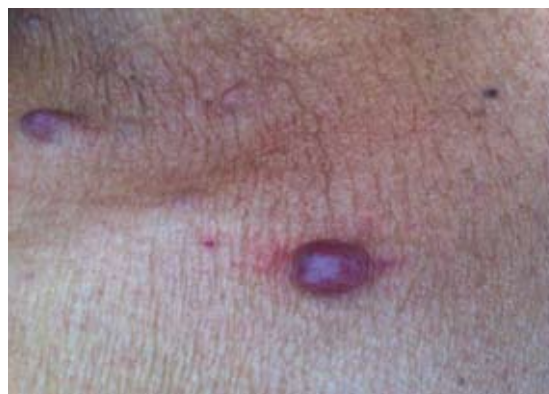**Figure 1A.** Erythematous-purplish papule-nodular lesions on the face and neck.



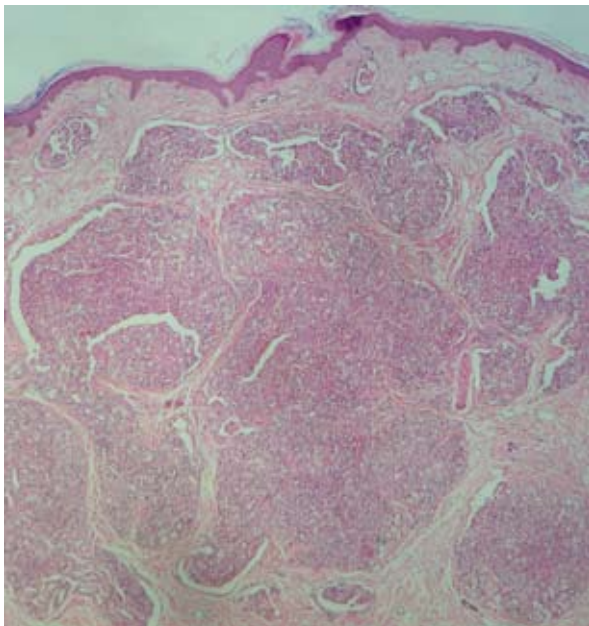
**Figure 1C.** Lesions on the upper anterior right trunk.



**Figure 1B.** Lesions on the infra-mammary region.



**Figure 1D.** Close up of lesions on the upper anterior right trunk.



**Figure 2A.** Histopathology – dermal lesion with newly formed capillaries delimited by clear vascular space, configuring a glomeruloid aspect (hematoxylin and eosin  $\times 40$ ).

man's disease, osteosclerotic lesions, panhypopituitarism, and secondary hyperparathyroidism, without any cutaneous manifestations. She had received a bone marrow transplant six years ago and had been well-controlled.

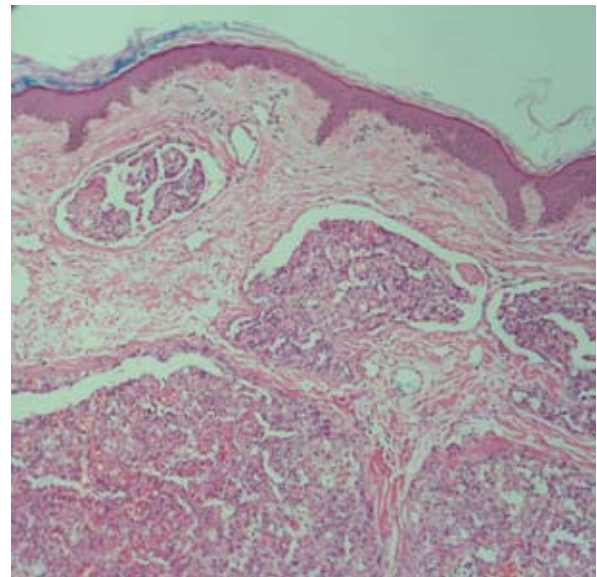
The present dermatological examination revealed erythematous-purplish papule-nodular lesions predominantly on the trunk, the proximal region of the upper limbs, and the cervical region (Figure 1A, Figure 1B, Figure 1C, and Figure 1D).

Other exams confirmed pleural and pericardial effusion in addition to ascites. Histologic examination obtained from an excisional biopsy of one of the lesions revealed a dermal lesion formed by small and congested capillaries surrounded by a clear sinusoidal-like space, configuring a glomeruloid aspect. (Figure 2A and Figure 2B)

GH and the effusion syndrome were interpreted as relapse of the disease, and chemotherapy was proposed as treatment. Twelve months after onset of chemotherapy, the patient achieved partial symptomatic control, without alteration of the cutaneous picture.

## DISCUSSION

POEMS syndrome has an indolent clinical course, with an average survival period of 13.8 years. Due to being such a rare disease, there is a lack of controlled clinical studies that would allow considering any treatment modality the gold standard. Neverthe-



**Figure 2B.** Higher magnification of histopathology (hematoxylin and eosin  $\times 100$ ).

less, at least 75% of patients are benefitted by some therapeutic modality. Management of this syndrome is usually carried out in the ambit of hemato-oncology. Autologous bone marrow transplant as initial treatment of the patient is considered a good option, especially for young patients with disseminated osteosclerotic disease, allowing symptomatic control and an increased survival period (2).

In our case, despite the transplant leading to satisfactory control of the disease over six years, it did not avert its relapse. Furthermore, in a quite peculiar fashion, the first sign of the recurrence appeared on the skin. The literature describes that hemangiomas in general, including glomeruloid hemangiomas, can precede the other signs and symptoms of the syndrome, which makes it reasonable to expect this situation in case of a possible relapse (6).

GH is classified as a benign vascular neoplasia. Since its description as a cutaneous marker of POEMS syndrome, some authors reported patients with diagnosis confirmed by histopathology but without other signs of the syndrome, therefore disproving such an association. However, those reports were dealing with young patients with a short follow-up period, and therefore we believe that further evolution in those patients could present with criteria for the syndrome. There are GH reports providing evidence of other clinical signs up to 6 years in advance (10). As in the case of our patient, GH seems to be more common in situations of concurrence of POEMS and Castleman's disease (8).

The physiopathology of GH is not yet completely understood. Metalloproteinases and VEGF have an es-

sential role in angiogenesis and neovascularization. VEGF is increased in POEMS syndrome. High serum levels of VEGF were detected in patients with GH (11), and were thus proposed as the core of its pathogenesis (8,12).

Interestingly, in view of this etiopathogenic mechanism, we can associate, in theory, the almost eruptive appearance of cutaneous hemangiomas with the systemic decomposition manifested by the effusion syndrome, with respiratory discomfort. Some researches already indicated VEGF as inducer of increased systemic vascular permeability, even correlating high VEGF levels with clinical deterioration (13). Therefore, hypothetically, GHs would be a prelude of VEGF hyperexpression and could, if it has been identified and interpreted accordingly, predict a prognosis. This could influence the therapeutic decision, since antiangiogenic and anticytokine substances have already been used for POEMS syndrome, for instance bevacizumab (monoclonal anti-VEGF antibody).

## CONCLUSION

With this illustrative case, we have tried to raise awareness in all dermatologists regarding this syndrome and its skin manifestations, in addition to reinforcing the importance of dermatologic follow-up in these patients.

## References:

1. Dispenzieri A, Kyle RA, Lacy MQ, Rajkumar SV, Therneau TM, Larson DR, *et al.* POEMS syndrome: definitions and long-term outcome. *Blood*. 2003;101:2496-506.
2. Pinto Neto JV. POEMS syndrome (osteosclerotic myeloma). *Rev Bras Hematol Hemoter*. 2007;29:98-102.
3. Lee JY, Choi JK, Ha JW, Park SE, Kim CW, Kim SS. Glomeruloid Hemangioma as a Marker for the Early Diagnosis of POEMS Syndrome. *Ann Dermatol*. 2017;29:249-51.
4. Dispenzieri A. POEMS syndrome: 2017 Update on diagnosis, risk stratification, and management. *Am J Hematol*. 2017;92:814-29.
5. González-Guerra E, Haro MR, Fariña MC, Martín L, Manzarbeitia L, Requena L. Glomeruloid haemangioma is not always associated with POEMS. *Clin Exp Dermatol*. 2009;34:800-3.
6. Jeunon T, Sampaio AL, Caminha RC, Reis CU, Dib C. Glomeruloid hemangioma in POEMS syndrome: a report on two cases and a review of the literature. *An Bras Dermatol*. 2011;86:1167-73.
7. Chan JK, Fletcher CD, Hicklin GA, Rosai J. Glomeruloid hemangioma. A distinctive cutaneous lesion of multicentric Castleman's disease associated with POEMS syndrome. *Am J Surg Pathol*. 1990;14:1036-46.
8. Yuri T, Yamazaki F, Takasu K, Shikata N, Tsubura A. Glomeruloid hemangioma. *Pathol Int*. 2008;58:390-95.
9. Gupta J, Kandhari R, Ramesh V, Singh A. Glomeruloid hemangioma in normal individuals. *Indian J Dermatol*. 2013;58:160.
10. Chung WK, Lee DW, Yang JH, Lee MW, Choi JH, Moon KC. Glomeruloid hemangioma as a very early sign of POEMS syndrome. *J Cutan Pathol*. 2009;36:1126-8.
11. Jacobson-Dunlop E, Liu H, Simpson EL, White CR, White KP. Glomeruloid hemangiomas in the absence of POEMS syndrome. *J Cutan Pathol*. 2012;39:401-3.
12. Biswas A, Byrne PH. Violaceous papules in a patient with neuropathy. Glomeruloid haemangioma associated with POEMS syndrome. *Clin Exp Dermatol*. 2010;35:e81-82.
13. Lesterhuis WJ, Rennings AJ, Leenders WP, Nooteboom A, Punt CJ, Sweep FC, *et al.* Vascular endothelial growth factor in systemic capillary leak syndrome. *Am J Med*. 2009;122:e5-7.