

Two Cases of Proximal Subungual Onychomycosis Caused by *Trichophyton rubrum* in HIV-negative Patients During Treatment with TNF- α Inhibitors Combined with Methotrexate

Pernille Lindsø Andersen¹, Mattias Arvid Simon Henning¹, Gregor B. E. Jemec¹, Maiken Cavling Arendrup², Ditte Marie L. Saunte¹

¹Department of Dermatology, Zealand University Hospital, Roskilde; Health Sciences Faculty, University of Copenhagen, Copenhagen, Denmark; ²Unit of Mycology, Department of Microbiology and Research, Statens Serum Institut, Copenhagen, Denmark

Corresponding author:

Assist. Prof. Ditte Marie L. Saunte, MD, PhD
Department of Dermatology
Zealand University Hospital; Roskilde
Sygehusvej 5
DK-4000 Roskilde
Denmark
disa@regionsjaelland.dk

ABSTRACT Proximal subungual onychomycosis (PSO) is a rare subtype of onychomycosis with a clinical presentation characterized by proximal leukonychia in the lunular area of the nail. PSO is associated with immunosuppression and regarded a sign of Human Immunodeficiency Virus (HIV) infection when caused by *Trichophyton (T.) rubrum*. We present two cases of PSO caused by *T. rubrum* developed during treatment with TNF- α inhibitors combined with methotrexate (MTX).

KEY WORDS: onychomycosis, nail diseases, psoriasis, immunosuppressive agents, methotrexate, tumor necrosis factor- α

Received: August 28, 2018

Accepted: November 16, 2018

INTRODUCTION

Proximal subungual onychomycosis (PSO) is a rare subtype of onychomycosis found in 0.3% of cases (1). Its clinical presentation is characterized by proximal leukonychia in the lunular area (2). PSO is associated with immunosuppression and regarded as a sign of Human Immunodeficiency Virus (HIV) infection when caused by *Trichophyton (T.) rubrum* (1). PSO caused by *T. rubrum* has previously only been reported in a single patient treated with tumor necrosis factor- α (TNF- α) inhibitors and in no patients treated with methotrexate (3). We present two cases of PSO caused by *T. rubrum* developed during treatment with TNF- α inhibitors combined with methotrexate (MTX).

PATIENTS

Case 1

A 78-year-old man treated for psoriasis and psoriatic arthritis noted a toenail change during combination treatment with etanercept 50 mg/week and MTX 10 mg/week. Figure 1 displays a timeline of his medication. Medical history included mild nephropathy and a negative HIV test.

Physical examination revealed proximal white nail changes on the left hallux, discrete scaling of planta pedis, and maceration of the lateral interdigital toe web. Direct microscopy of nail material displayed septate hyphae and a few arthroconidia. Culture and PCR confirmed *T. rubrum* infection.

The patient was treated for three months with oral terbinafine 250 mg/day in combination with daily application of topical ciclopirox nail lacquer. Clinical improvement was noted at four month follow-up with the nail at the proximal nail fold appearing normal. Direct microscopy displayed a few hyphae combined with a negative culture, indicating non-vital fungi. Mycological cure was observed eight months after treatment initiation and clinical cure after thirteen months. Figure 2 illustrates the patient's clinical course.

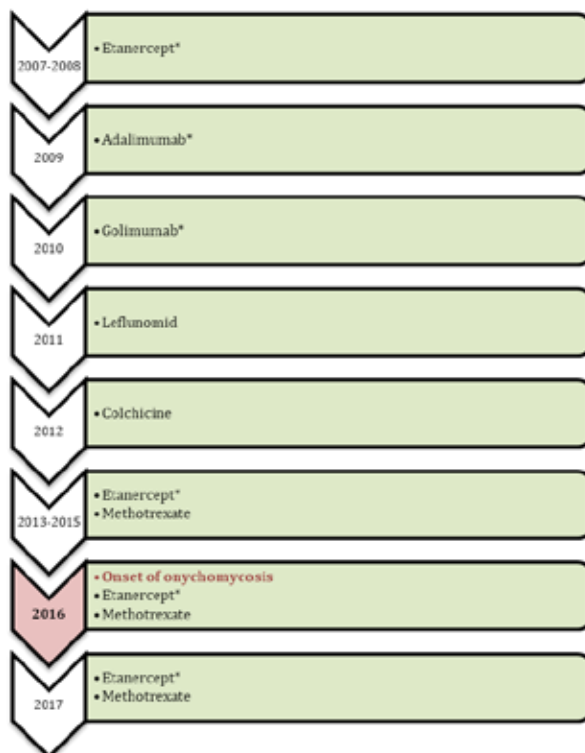


Figure 1. Patient 1: Timeline of psoriasis medication and onset of proximal subungual onychomycosis. *TNF- α inhibitors

Case 2

A 55-year-old man with psoriatic and psoriasis arthritis was referred to the Dermatologic Outpatient Clinic with a facial rash potentially due to infliximab. Medical history included inflammatory bowel disease. The patient had received infliximab for eight months and MTX for fourteen months at the time of referral. Tinea barbae caused by *T. rubrum* was diagnosed and treated with topical terbinafine. During clinical examination a whitening of the nails the on left 1st and 3rd toe and right 2nd toe was noted, but interpreted as psoriasis nails.

At three month follow-up, tinea barbae had clinically cleared, however progression of the proximal white nail changes was noted on the left hallux. A dermatophyte-specific PCR from the toenail confirmed *T. rubrum* infection. HIV test was negative. Treatment with terbinafine 250 mg/day for three months combined with topical amorolfine applied once a week was initiated.

DISCUSSION

These two cases represent the rare manifestation of PSO caused by *T. rubrum* in HIV-negative patients treated with TNF- α inhibitors in combination with MTX. Patients with psoriasis have an increased susceptibility to dermatophyte infections (4). A study on onychomycosis in 315 patients with psoriasis treated with TNF- α inhibitors (infliximab, etanercept, and adalimumab) found a prevalence of 13-33% compared with 14% in patients with psoriasis not treated with biologics. None of these patients presented with PSO (4).

TNF- α inhibitors may reduce the inflammatory response to fungal infection. The cytokine is mainly secreted by macrophages and prevents the actions of IL-12 and interferon- γ and the migration of dendritic cells (5). TNF- α inhibitors mainly suppress monocytes and dendritic cells, while MTX inhibits activation and

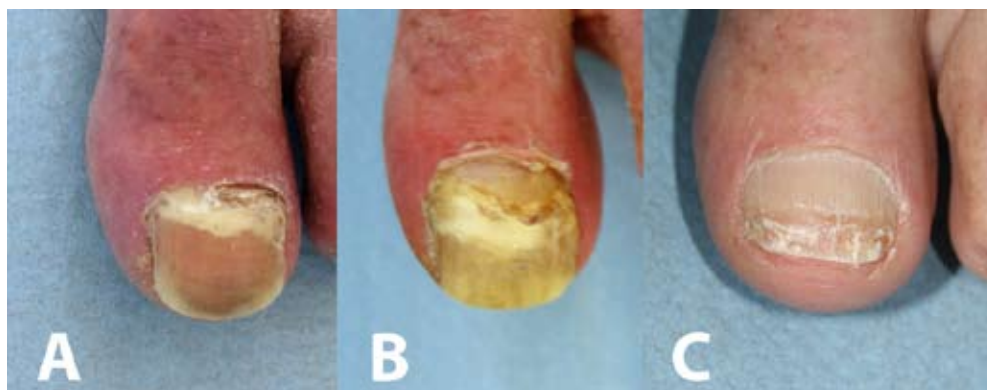

Figure 2. Clinical course of the patient 1: A) Presentation. B) Three months after treatment. C) Nine months after treatment.

proliferation of lymphocytes (6). The combination of TNF- α inhibitors with MTX may further suppress the immune response by targeting different immune cells.

CONCLUSION

This is the first time PSO caused by *T. rubrum* has described in patients receiving TNF- α inhibitors combined with MTX, a frequent treatment strategy. This condition may therefore be under-diagnosed. We suggest screening for onychomycosis before treatment initiation and clinical follow-up during combination treatment with TNF- α inhibitors and MTX.

Acknowledgements

We thank the patients for providing informed consent to share their cases in this paper.

Conflict of interests

M.A.S.H. and P.L.A. have no conflicts of interests to declare.

G.B.E.J. has received honoraria from AbbVie, Coloplast, Pfizer, Pierre Fabre, Inflarx, MSD, Novartis, and UCB for participation on advisory boards, and grants from AbbVie, Leo Pharma, Novartis, Janssen-Cilag, Regeneron, UCB, and Sanofi for participation as an investigator, and received speaker honoraria from AbbVie, Galderma, and Leo Pharma.

D.M.S. has received honoraria from Sanofi and Janssen for participation on advisory boards, speaker honoraria from AbbVie, LeoPharma, and Astella and travel grants from AbbVie, Sanofi, and Pfizer.

M.C.A. has received personal speaker's honoraria in the past five years from Astellas, Basilea, Gilead, MSD, Pfizer, T2Candida, and Novartis. She has received research grants and contract work paid to the Statens Serum Institute from Astellas, Basilea, Gilead, MSD, Pfizer, T2Candida, F2G, Cidara, and Amplyx.

References:

1. Gupta AK, Taborda P, Taborda V, Gilmour J, Rachlis A, Salit I, *et al.* Epidemiology and prevalence of onychomycosis in HIV-positive individuals. *Int J Dermatol.* 2000;39:746-53.
2. Piraccini BM, Alessandrini A. Onychomycosis: A Review. *J Fungi (Basel).* 2015;1:30-43.
3. Gonzalez-Lopez L, Monteagudo-Sanchez B, Mosquera-Fernandez A, Gonzalez-Vilas D, Ordonez P. Proximal subungual onychomycosis in a patient treated with tumor necrosis factor alpha blockers. *Semergen.* 2017;43:245-6.
4. Al-Mutairi N, Nour T, Al-Rqobah D. Onychomycosis in patients of nail psoriasis on biologic therapy: a randomized, prospective open label study comparing Etanercept, Infliximab and Adalimumab. *Expert Opin Biol Ther.* 2013;13:625-9.
5. Lowther AL, Somani AK, Camouse M, Florentino FT, Somach SC. Invasive *Trichophyton rubrum* infection occurring with infliximab and long-term prednisone treatment. *J Cutan Med Surg.* 2007;11:84-8.
6. Witte T. Methotrexate as combination partner of TNF inhibitors and tocilizumab. What is reasonable from an immunological viewpoint? *Clin Rheumatol.* 2015;34:629-34.