

TRANSOBTURATOR ADVANCE® SLING SUSPENSION FOR THE TREATMENT OF POSTPROSTATECTOMY STRESS URINARY INCONTINENCE

Goran Štimac, Borislav Spajić, Alek Popović, Danijel Justinić, Igor Grubišić, Šoip Šoipi, Ivan Svaguša, Matea Pirša and Boris Ružić

Department of Urology, Sestre milosrdnice University Hospital Center, Zagreb, Croatia

SUMMARY – Stress urinary incontinence (SUI) continues to present a major complication after radical prostatectomy. Suburethral slings represent one of the less invasive options for postprostatectomy SUI, and a more recent addition is a transobturator sling, the AdVance®. We report our results with the AdVance® sling for the management of postoperative SUI. The evaluation was conducted on 47 patients with AdVance® implant for SUI in our institution (November 2010 - June 2017). Measurements included age, etiology of SUI, duration of SUI, follow-up and pad use per day (PPD) pre- and postoperatively. Patients were classified as cured if they used no pads or 1 PPD for security reasons, or as improved if 1-2 PPDs were used and if there was a 50% reduction in pad use per day postoperatively. In our series we observed a reduction of mean PPD of 5.1 (2-8) to 1.7 (0-4) postoperatively. After follow-up and according to our criteria, the cure rate was 51.1% (24/47) and the improvement rate 27.5% (13/47). The overall success rate was 78.6% (37/47). No improvement was observed in 21.4% (10/47) of patients. Failure rates after sling placement for patients with additional treatments following prostatectomy were much higher (60% (3/10) for radiation therapy and 66.7% (4/10) for urethral stricture disease). Our results show favourable cure and improvement rates and are comparable to results from larger series. The most appropriate candidates for the AdVance® sling are patients with mild to moderate postprostatectomy SUI. The results may be even better in patients without additional treatment following prostatectomy, such as radiation therapy or surgery for stricture disease.

Key words: *Prostate cancer; Prostatectomy; Urinary incontinence; Postprostatectomy incontinence; Stress urinary incontinence; Suburethral sling; Transobturator sling; Reconstructive surgery*

Introduction

The incidence of organ confined prostate cancer has increased in our country and worldwide over the past few decades as a result of the widespread application of PSA testing and increased life expectancy^{1,2,3}. Due to an increased number of performed radical prostatectomies (RP) for localized disease, an increasing number of men have postoperative stress urinary

incontinence (SUI) that continues to present a major complication, despite improvements in surgical technique³⁻⁵. The reported incidence rate of postoperative SUI varies widely between 5% and 65%⁴⁻⁷.

Treatment options for early postprostatectomy SUI begin with conservative approaches, such as anticholinergics, physiotherapy, electrostimulation and biofeedback for the first year after RP before moving on to surgical therapy^{5,6}. After failed conservative treatment, two major treatment options for male SUI are the artificial urinary sphincter (AUS) and the male sling^{4,5}. The AUS has a high success rate of about 79% and is considered to be the gold standard for the treatment of postprostatectomy incontinence^{4,5}.

Correspondence to: *Goran Štimac, MD, PhD*, Department of Urology, Sestre milosrdnice University Hospital Center, Vinogradska cesta 29, HR-10000 Zagreb, Croatia
E-mail: goran.stimac2@zg.t-com.hr

Received February 1, 2018, accepted May 1, 2018

Suburethral slings represent one of the less invasive options for postprostatectomy SUI, and a more recent addition is the transobturator sling (TOT), the AdVance®^{8,9}. In contrast to AUS and other slings that work through direct compression of the urethra, the TOT AdVance® sling functions by repositioning and lengthening of the functional sphincteric urethra. It offers a new functional non-compressive approach without any moving mechanical parts⁸⁻¹⁰.

The purpose of this report is to evaluate clinical outcomes after the placement of the AdVance® TOT sling in men with postprostatectomy SUI at our institution. The surgical technique of sling placement is also described herein.

Patients and methods

Our study was conducted in a retrospective manner (November 2010 - June 2017) and involved 47 male patients with SUI caused by radical retropubic prostatectomy (38/47), radical laparoscopic prostatectomy (2/47), transvesical adenomectomy (2/47), or transurethral resection of the prostate (TURP) (5/47). All patients were continent prior to prostate surgery. Measurements included age, etiology of SUI, duration of SUI and follow-up. Incontinence was assessed on the basis of pad per day use.

Prior to AdVance® sling implantation, all patients were evaluated with full medical history, physical examination and urinalysis. Dynamic urethrocytostomy was performed on each patient in dorsal lithotomy position under local anesthesia (lidocaine gel) to evaluate the functionality of sphincteric urethra and to exclude urethral stricture disease or bladder neck sclerosis. Gentle pressure was applied to the midperineum dorsal to the level of the membranous urethra during urethroscopy to evaluate the mobility and coaptation of the sphincteric mechanism. Patients with evidence of prostate carcinoma relapse, urethral scarring, bladder neck contracture, urethral strictures and neurogenic causes of incontinence were excluded. Urodynamic studies were not performed. The time interval between prostatectomy and the placement of the sling had to exceed 6 months.

The AdVance® sling (American Medical Systems, Minnetonka, MN, USA) placement was performed under spinal anesthesia in dorsal lithotomy position, as described by Rehder and Gozzi⁸. The operative steps

for the AdVance® sling placement are shown in Figures 1-6. A single dose of perioperative antibiotics was administered, comprising Metronidazole and 3rd generation cephalosporine. Catheters were removed on the 2nd postoperative day with subsequent measuring of residual urine by ultrasound, followed by hospital discharge on the next day.

The degree of pre- and postoperative SUI was evaluated by the number of pads used per day (PPD). Patients were monitored after AdVance® sling implantation and daily pad usage was evaluated by personal interview. According to the classification of incontinence by International Continence Society (ICS), SUI

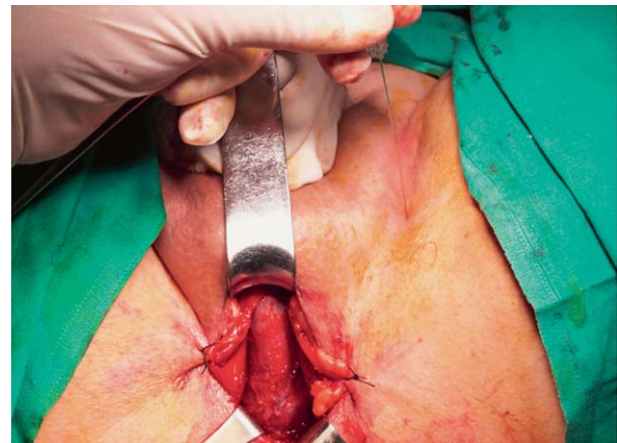


Fig. 1. After the placement of a Foley urethral catheter, the urethral bulb and corpus spongiosum are mobilized and prepared; the trocar passer insertion site is marked with a spinal needle 2 cm below the adductor longus muscle tendon insertion.

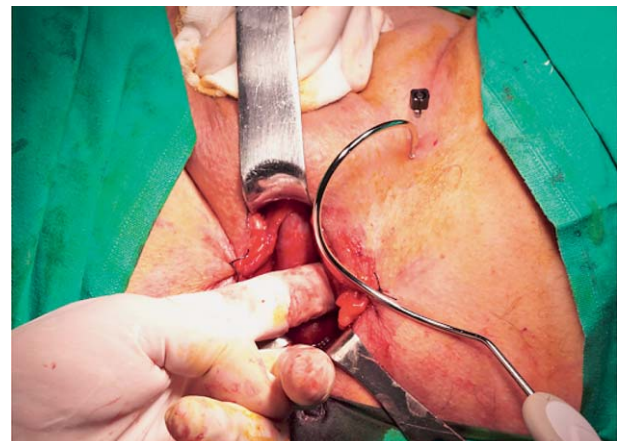


Fig. 2. The helical needle passer is advanced through the medial aspect of the obturator foramen.

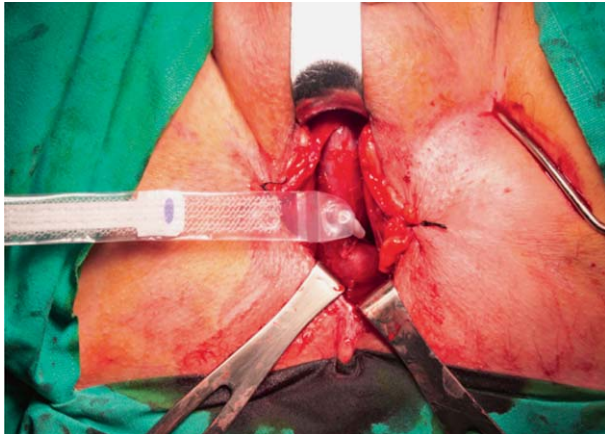


Fig. 3. The needle passer is exiting at the apex of the angle between the corpus spongiosum and inferior pubic ramus. The mesh is secured to the needle tip and brought back through the stab incision.

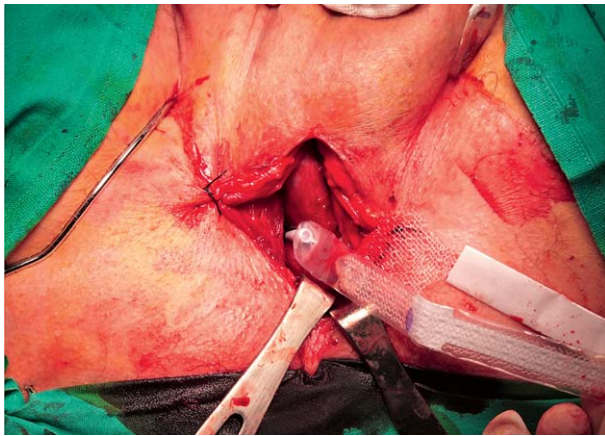


Fig. 4. The mesh is brought back with the needle passers through the stab incisions bilaterally.

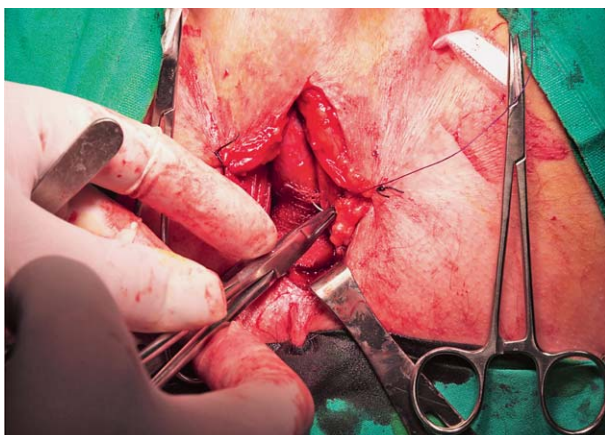


Fig. 5. Sutures are used to fix the central portion of the mesh to the corpus spongiosum.

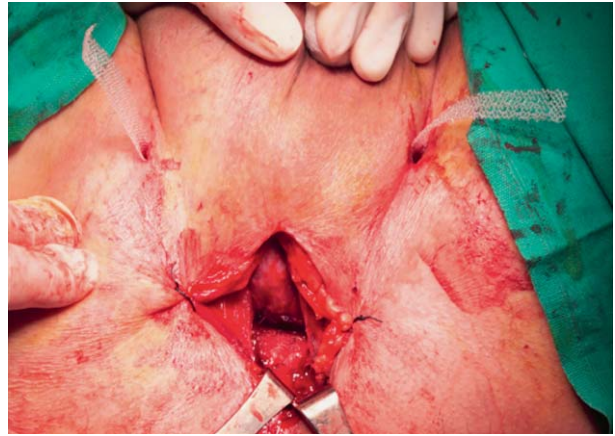


Fig. 6. Pulling firmly on the sling arms tensions the sling. Following the tensioning of the sling, approximately 2–4 cm of proximal urethral movement is observed. The sling provides support to the dorsal distal portion of the membranous urethra, which acts as a backstop during stress.

was defined as either mild (use of 1 or 2 PPD), moderate (use of 3 or 4 PPD) or severe (use of more than 4 PPD)¹¹. As previously reported by Bauer *et al.*¹², patients were classified as cured if they used no pads or 1 PPD for security reasons, or as improved if 1–2 PPD were used and if there was a 50% reduction in daily pad usage. Otherwise, they were classified as not improved or failed. Treatment was considered a success if patients were either cured or improved.

Results

Between November 2010 and June 2017, the AdVance® sling was implanted in 47 patients in our institution. Mean age at the time of the surgery was 68 years (range: 47 – 78) and mean duration of incontinence was 41.6 months (range: 12 – 132).

Etiology of SUI was radical prostatectomy (85.1%), transvesical adenomectomy (4.3%) and TURP (10.6%). Median follow-up was 53 months (range: 2–81). All patients attempted pelvic floor exercises and received anticholinergics to improve continence status prior to the AdVance® sling implantation. Radiation therapy for disease relapse preceded sling placement in 5 patients (10.6%). Six patients (12.8%) were treated endoscopically for postprostatectomy urethral stricture disease or bladder neck sclerosis prior to sling placement.

Table 1. Pre- and postoperative pad usage after AdVance® sling implantation in 47 men with postprostatectomy SUI

ICS definition (N of pads per day)	Preoperatively N (%)	Postoperatively N (%)
Severe SUI (>4 PPD)	30 (63.8%)	7 (15%)
Mild/moderate SUI (1-4 PPD)	17 (36.2%)	20 (42.5%)
Continent SUI (0 PPD)	0 (0%)	20 (42.5%)

The number of pads used per day preoperatively and postoperatively, in accordance with the classification of incontinence by International Continence Society (ICS), is shown in Table 1¹¹. According to ICS criteria, preoperatively 0%, 36.8% and 63.2% of our patients were using no pads, 1-4 PPD, and >4 PPD, respectively. Postoperatively 31.6% of the patients were using no pads, 57.9% were using 1-4 PPD and only 10.5% were using >4 PPD. In our series we observed a significant reduction of mean preoperative PPD usage of 5.1 (range: 2-8) to 1.7 (range: 0-4) postoperatively.

The results following an AdVance® sling implantation in 47 men with SUI comparing groups of patients with or without additional postprostatectomy interventions is shown in Table 2. After follow-up and according to our criteria, the cure rate was 51.1% (24/47) and the improvement rate 27.5% (13/47). The overall success rate was 78.6% (37/47). No improvement was observed in 21.4% (10/47) of patients. Clinical conditions of these patients did not improve after surgery; however, there was no worsening when compared to the pad use before AdVance® sling implantation. Fail-

ure rates for patients with additional treatments after prostatectomy were much higher (60% (3/5) for radiation therapy and 66.7% (4/6) for internal urethrotomy group). Cure and improvement rates following sling implantation for patients without additional treatments after prostate surgery were 61.1% (22/36) and 30.6% (11/36) respectively, resulting in a 91.7% (33/36) success rate.

There were no intraoperative complications. The overall early postoperative complication rate after sling placement was 6.4% (3/47). Two patients had postoperative wound infections and one had passing urinary retention one week after catheter placement. No erosion of the urethra was observed, and no episodes of sling infections, erosions or explantations were noted during the study period.

Discussion

Despite improvements in surgical technique and technological developments in laparoscopy and robotics, SUI continues to present a major complication following RP. Over recent decades, SUI rates have been decreasing due to modified surgical techniques, but remain at 1-2% one year after RP, even in high-volume centers of excellence⁴. Following failed conservative treatment 1 year after RP, surgical therapy for SUI is recommended⁵.

The AUS (AMS 800, American Medical Systems, Minnetonka, MN, USA) was introduced in 1971 with high continence and patient satisfaction rates. It remains the gold standard for the surgical treatment of severe persistent postoperative SUI and total incontinence^{4,5,13}. Success rates after AUS implantation are still the highest when compared to all other treatment options and devices on the market^{13,14}. Unfortunately,

Table 2. Results after AdVance® sling implantation in 47 men with SUI, comparing groups of patients with or without additional postprostatectomy interventions

	N (%)			
	Cure	Improvement	Failure	Success
Prostatectomy only	22 (61.1)	11 (30.6)	3 (8.3)	33 (91.7)
Prostatectomy & radiation therapy	0	2 (40)	3 (60)	2 (40)
Prostatectomy & urethral stricture surgery	2 (33.3)	0	4 (66.7)	2 (33.3)
TOTAL	24 (51.1)	13 (27.5)	10 (21.4)	37 (78.6)

Table 3. Studies evaluating efficacy of the AdVance® sling suspension

Study	N of patients	Follow up (months)	Definition of cured status	Cured (%)	Improved (%)
Gozzi <i>et al.</i> (2008)(8)	67	3	No pad use	52	10
Cornu <i>et al.</i> (2009)(9)	102	13	No pad use or one for security reasons	62.7	17.6
Bauer <i>et al.</i> (2009)(12)	70	12	No pads or one dry security pad	51.4	25.7
Rehder <i>et al.</i> (2010)(16)	118	12	No pad use or one for security reasons	73.7	16.9
Cornel <i>et al.</i> (2010)(17)	35	12	No pad use and 24-h pad test <2 g	9	45.5
Cornu <i>et al.</i> (2011)(18)	136	21	No pad use or use only for security reasons	62	16
Berger <i>et al.</i> (2011)(19)	26	22	No pad use	61.5	26.9

there is a significant reoperation rate (>35%) after 10 years in patients with AUS due to mechanical failure¹⁴. On the other hand, some patients do not have the ability or the motivation to operate the pump used with an AUS. In the late 1990s, male slings were introduced as an alternative to AUS for patients with mild to moderate incontinence. The main advantage of slings compared to the AUS is minimally invasive approach with short learning curve and the lack of mechanical components, with reduced the potential for device failure.

In 2007, Rehder and Gozzi⁸ from Innsbruck (Austria) published the results of the first TOT sling suspension technique in the treatment of male postoperative SUI. The AdVance® sling is self-anchored with bilateral polypropylene mesh arms placed in a TOT fashion. It is implanted using a TOT approach via a median perineal incision using helical trocar needles. Rocco *et al.*¹⁵ published that SUI after RP results from the shortening of anatomical and functional sphincter length due to postoperative prolapse of the urethral sphincter complex. The AdVance® sling supports that dorsal structure of the membranous urethra and achieves passive continence through subsequent elevation, lengthening and repositioning of the descended sphincter segment⁸⁻¹⁰. In contrast to retropubic and bone-anchored compressive devices, the force is applied parallel to the urethral lumen⁸. The sling augments the lax and descended dorsal support structures of the sphincter and offers a non-obstructive and functional therapeutic approach for the treatment of post-prostatectomy SUI¹⁶.

From our experience, good candidates for AdVance® TOT sling implantation are patients with mild to moderate SUI, with preserved residual sphincter function without scar defects and an adequate bladder compliance. Preoperative dynamic urethros-

copy is of the utmost importance to exclude stricture disease and to confirm mobility and coaptive response of the membranous urethra during perineal pressure test. Midperineal elevation in the lithotomy position and the ability to contract external sphincter during urethroscopy is a good sign in predicting positive outcomes after sling placement. If urethral stricture or stenosis is present, we advise treating and stabilizing this for at least 6 months before making the decision regarding sling placement.

In the present study, 47 patients with mild to severe SUI after prostatectomy were treated with the AdVance® sling. Our results of the AdVance® sling suspension with overall success rate of 78.6% (cure rate 51.1%, improvement rate 27.5%) are comparable to previously published follow-up series shown in Table 3^{9,12,16-19}. Moreover, the success rates are comparable to success rates for other sling systems²⁰⁻²³. Rehder *et al.*²⁴ demonstrated that surgeons in high-volume centers may even improve functional results with increasing experience. Comparison of outcome rates between different studies is very difficult, because different classifications or definitions of incontinence, patient selection criteria and cure rate definitions were used. However, the comparison of outcomes between key studies suggests that higher rates of continence can be achieved in patients with mild to moderate, rather than severe incontinence. Nevertheless, the success rate of 91.7% in our study is significant, especially when analysing cure and improvement rates following sling placement for patients without additional treatments after prostate surgery (cure rate 61.1%, improvement rate 30.6%).

As expected, success rates after sling placement for patients with additional treatments after prostatectomy were much lower in our study (40% for radiation

therapy and only 33.3% for internal urethrotomy group). Like our study, several authors found a trend for an association with previous radiation therapy and treatment failure^{4,5,19,24,25}. It seems that cure rates are lower for patients who are unable to contract their external sphincter, have a poor response to midperineal pressure test during dynamic urethroscopy and those with scarred and immobile urethra, i.e. after radiotherapy or repeated surgery for urethral stricture disease^{18,24,25}. Both therapies are known to potentially cause severe scarring and decrease urethral mobility which is of absolute importance, and are, in our opinion, relative contraindications for AdVance® sling placement. In any case, these suboptimal candidates may experience poorer results than the ideal candidate, but they still have a chance to achieve considerable improvement.

Complication rates in our study are minimal and acceptable, and confirm findings from previous reports²⁵⁻²⁷. In contrast to a larger study from Bauer *et al.*²⁵ evaluating complications after AdVance® sling implantation with a retention rate of 21.3%, the postoperative urinary retention rate in our series (2.1%) is substantially lower. Two of our patients had local postoperative wound infection and were treated with oral antibiotics.

Our study is not without limitations. Although the initial results after AdVance® sling placement are encouraging, further long-term follow-up and evaluation for much larger series is needed. Postoperative success rates can be further improved by better patient selection criteria, for example by excluding patients with severe periurethral fibrosis and scarring due to previous radiation therapy and surgery for recurrent stricture disease.

Conclusions

Postprostatectomy SUI remains a significant problem impacting a large number of patients with resultant impairment of quality of life. AdVance® sling is the only product on the market which focuses on restoring normal anatomy and offers non-compressive functional approach for the treatment of postprostatectomy SUI. The results from our study suggest a favourable success rate (78.6%) with acceptable minor complications (6.4%) after AdVance® sling placement and are comparable to results from larger series. Our

experience suggests that cystoscopically confirmed residual sphincter function is the most important requirement for a good outcome. The most appropriate candidates for the placement of the AdVance® sling may be those with mild to moderate postoperative SUI. The results may be even better in patients without additional treatment following radical prostatectomy, such as radiation therapy or surgery for urethral stricture disease. Patients with urethral immobility, scarring and severe incontinence can be treated, but a realistic explanation of the outcomes should be offered to them when making the decision about the treatment.

References

1. EAU-ESTRO-ESUR-SIOG Prostate Cancer Guidelines Panel. Prostate Cancer and the John West Effect. *Eur Urol.* 2017 Jul; 72(1):7-9. doi: 10.1016/j.eururo.2017.02.006.
2. Siegel R, Naishadham D, Jemal A. Cancer statistics, 2012. *CA Cancer J Clin.* 2012;62:1029. doi: 10.3322/caac.20138.
3. Štimac G, Dimanovski J, Trnski D, Katusic J, Ruzic B, Spajic B, Reljic A, Padovan M, Kraus O. Evolution of the clinical presentation and outcomes after radical prostatectomy for patients with clinically localized prostate cancer - changing trends over a ten year period. *Coll Antropol.* 2007 Dec;31(4):1055-60.
4. Bauer RM, Bastian PJ, Gozzi C, Stief CG. Postprostatectomy incontinence: all about diagnosis and management. *Eur Urol.* 2009;55:322-33. doi: 10.1016/j.eururo.2008.10.029.
5. Klingler HC, Marberger M. Incontinence after radical prostatectomy: surgical treatment options. *Curr Opin Urol.* 2006; 16:60-4. DOI: 10.1097/01.mou.0000193381.93608.dc
6. Alivizatos G, Skolarikos A. Incontinence and erectile dysfunction following radical prostatectomy: a review. *Scientific World Journal.* 2005;5:747-58. DOI: 10.1100/tsw.2005.94
7. Ficarra V, Novara G, Rosen RC, Artibani W, Carroll PR, Costello A. Systematic review and metaanalysis of studies reporting urinary continence recovery after robot-assisted radical prostatectomy. *Eur Urol.* 2012;62:405-17. DOI: 10.1016/j.eururo.2012.05.045
8. Rehder P, Gozzi C. Transobturator sling suspension for male urinary incontinence including post-radical prostatectomy. *Eur Urol.* 2007;52:860-6. DOI: 10.1016/j.eururo.2007.01.110
9. Cornu JN, Sèbe P, Ciofu C, Peyrat L, Beley S, Tligui M, Lukacs B, Traxer O, Cussenot O, Haab F. The AdVance transobturator male sling for postprostatectomy incontinence: clinical results of a prospective evaluation after a minimum follow-up of 6 months. *Eur Urol.* 2009;56:923-7. DOI: 10.1016/j.eururo.2009.09.015.
10. Davies TO, Bepple JL, McCammon KA. Urodynamic changes and initial results of the AdVance male sling. *Urology.* 2009; 74:354-7. DOI: 10.1016/j.urology.2008.12.082

11. Kalejaiye O, Vij M, Drake MJ. Classification of stress urinary incontinence. *World J Urol.* 2015 Sep;33(9):1215-20. DOI: 10.1007/s00345-015-1617-1
12. Bauer RM, Mayer ME, Gratzke C, Soljanik I, Buchner A, Bastian PJ, Stief CG, Gozzi C. Prospective evaluation of the functional sling suspension for male postprostatectomy stress urinary incontinence: results after 1 year. *Eur Urol.* 2009 Dec; 56(6):928-33. DOI: 10.1016/j.eururo.2009.07.028
13. Scott FB, Bradley WE, Timm GW. Treatment of urinary incontinence by implantable prosthetic sphincter. *Urology.* 1973 Mar;1(3):252-9.
14. Venn SN, Greenwell TJ, Mundy AR: The long-term outcome of artificial urinary sphincters. *J Urol.* 2000;164:702-6; discussion 706-7.
15. Rocco F, Carmignani L, Acquati P, Gadda F, Dell'Orto P, Rocco B, Casellato S, Gazzano G, Consonni D. Early continence recovery after open radical prostatectomy with restoration of the posterior aspect of the rhabdosphincter. *Eur Urol.* 2007; 52:376-83. DOI: 10.1016/j.eururo.2007.01.109
16. Rehder P, Mitterberger MJ, Pichler R, Kerschbaumer A, Glodny B. The 1 year outcome of the transobturator retroluminal repositioning sling in the treatment of male stress urinary incontinence. *BJU Int.* 2010;106:1668-72. DOI: 10.1111/j.1464-410X.2010.09400.x
17. Cornel EB, Elzevier HW, Putter H. Can advance transobturator sling suspension cure male urinary postoperative stress incontinence? *J Urol.* 2010;183:1459-63. DOI: 10.1016/j.juro.2009.12.013
18. Cornu JN, Sèbe P, Ciofu C, Peyrat L, Cussenot O, Haab F. Mid-term evaluation of the transobturator male sling for postprostatectomy incontinence: focus on prognostic factors. *BJU Int.* 2011 Jul;108(2):236-40. DOI: 10.1111/j.1464-410X.2010.09765.x
19. Berger AP, Strasak A, Seitz C, Rein P, Hobisch A. Single institution experience with the transobturator sling suspension system AdVance® in the treatment of male urinary incontinence: mid-term results. *Int Braz J Urol.* 2011 Jul Aug;37(4):488-94.
20. Fassi-Fehri H, Badet L, Cherass A, *et al.* Efficacy of the InVance TM male sling in men with stress urinary incontinence. *Eur Urol.* 2007;51:498-503. DOI: 10.1016/j.eururo.2006.08.042
21. Hubner WA, Schlarp OM. Treatment of incontinence after prostatectomy using a new minimally invasive device: adjustable continence therapy. *BJU Int.* 2005;96:587-94. DOI: 10.1111/j.1464-410X.2005.05689.x
22. Hubner WA, Schlarp OM. Adjustable continence therapy (ProACTTM): evolution of the surgical technique and comparison of the original 50 patients with the most recent 50 patients at a single centre. *Eur Urol.* 2007;52:680-6. DOI: 10.1016/j.eururo.2006.10.054
23. Sousa-Escandón A, Cabrera J, Mantovani F, Moretti M, Ioanidis E, Kondelidis N, Neymeyer J, Noguera R. Adjustable suburethral sling (Male Remeex System) in the treatment of male stress urinary incontinence: a multicentric European study. *Eur Urol.* 2007;52:1473-80. DOI:10.1016/j.eururo.2007.05.017
24. Rehder P, Haab F, Cornu JN, Gozzi C, Bauer RM. Treatment of postprostatectomy male urinary incontinence with the TOT retroluminal repositioning sling suspension: 3-year follow-up. *Eur Urol.* 2012 Jul;62(1):140-5. DOI: 10.1016/j.eururo.2012.02.038
25. Bauer RM, Mayer ME, May F, Gratzke C, Buchner A, Soljanik I, Bastian PJ, Stief CG, Gozzi C. Complications of the AdVance transobturator male sling in the treatment of male stress urinary incontinence. *Urology.* 2010;75:1494-8. DOI: 10.1016/j.urology.2009.12.012
26. Trost L, Elliott DS. Male stress urinary incontinence: a review of surgical treatment options and outcomes. *Adv Urol.* 2012; 2012: 287489. DOI: 10.1155/2012/287489
27. Leruth J, Waltregny D, de Leval J. The inside-out transobturator male sling for the surgical treatment of stress urinary incontinence after radical prostatectomy: midterm results of a single-center prospective study. *Eur Urol.* 2012 Mar;61(3):608-15. DOI: 10.1016/j.eururo.2011.10.036

Sažetak

TRANSOPTURATORNA ADVANCE® SUSPENZIJA U LIJEČENJU
POSTOPROSTATEKTOMIJSKE STRESNE INKONTINENCIJE MOKRAĆE

*Goran Štimac, Borislav Spajić, Alek Popović, Danijel Justinić, Igor Grubišić Šoip Šoipi,
Ivan Svaguša, Matea Pirša i Boris Ružić*

Unatoč napretku u liječenju lokaliziranog raka prostate radikalnom prostatektomijom, i dalje je prisutan dio bolesnika kod kojih perzistira stresna urinarna inkontinencija (SUI). Suburetralni, a odnedavno i transopturatori „slingovi“ zbog neinvazivnosti postaju metodom izbora u liječenju ovih bolesnika. U članku prikazujemo kiruršku tehniku i naše rezultate liječenja postoperativne SUI metodom AdVance®. Od studenog 2010. do lipnja 2017. metodom AdVance® na Klinici je operirano 47 bolesnika. Zabilježena je dob, etiologija i trajanje SUI te dnevni broj uložaka preoperativno i postoperativno. Izlječenje je definirano kao potpuna kontinencija ili korištenje jednog sigurnosnog uložka / dan. Poboljšanje je definirano kao korištenje 1-2 uložka / dan te smanjenje u dnevnom broju uložaka veće od 50%. U ispitivanom razdoblju kod operiranih bilježimo značajan pad prosječnog broja uložaka / dan s 5.1 (2-8) na postoperativno 1.7 (0-4). Prema našim kriterijima, postoperativno je kontinentno 51.1% (24/47), a poboljšanje kontinencije nalazimo kod 27.5% (13/47) operiranih. Kod 78.6% (37/47) operiranih broj dnevno korištenih uložaka smanjio se za više od 50% i/ili je kontinentno. Stope neuspjeha znatno su veće kod bolesnika koji su nakon prostatektomije tretirani radioterapijom (60% (3/10)) ili uretrotomijom (66.7% (4/10)). Rezultati liječenja postoperativne SUI suspenzijom AdVance® u našoj ustanovi usporedivi su s rezultatima do sada objavljenih studija. Suspenzija AdVance® indicirana je kod bolesnika s blagom do umjerenom postoperativnom SUI te očuvanom ostatnom funkcijom sfinktera potvrđenom uretrocistoskopijom. Očekivano, a zbog periuretralne fibroze, uspješnost metode upitna je kod bolesnika koji su nakon prostatektomije tretirani radioterapijom ili endourološkim zahvatima.

Ključne riječi: Rak prostate; Prostatektomija; Inkontinencija mokrać; Postprostatektomijska inkontinencija; Stresna inkontinencija; Suburetralni slingovi; Transopturatori sling; Rekonstruktivna kirurgija