

AgNOR Counts in Differential Diagnosis of Parathyroid Adenoma and Hyperplasia in Preoperative Cytologic Smears

Ljubica Fustar Preradovic¹, Davorin Danic², Ika Kardum-Skelin³, Bozena Sarcevic⁴, Ana Danic Hadzibegovic⁵

¹ Department of Pathology and Cytology, Dr. Josip Bencevic General Hospital, Slavonski Brod, Croatia

² Department of ENT and Head and Neck Surgery, Dr. Josip Bencevic General Hospital Slavonski Brod, Croatia and Faculty of Medicine Osijek and Faculty of Dental Medicine and Health, Josip Juraj Strossmayer University of Osijek, Croatia

³ Department of Cytology and Cytogenetics, "Merkur" University Hospital, Zagreb, Croatia School of Medicine University of Zagreb, Croatia

⁴ Department of Pathology, University Hospital for Tumors, Clinical Center "Sestre Milosrdnice", Zagreb, Croatia and School of Medicine University of Zagreb, Croatia

⁵ Clinical Department for ENT and Head and Neck Surgery, Clinical Hospital Center Zagreb, Zagreb, Croatia and Faculty of Medicine, Josip Juraj Strossmayer University of Osijek, Croatia

Corresponding author: Ljubica Fustar Preradovic – ljubica.fustar.preradovic@sb.t-com.hr

Abstract

Objective. Minimally invasive surgery is the method of choice in the management of hyperparathyroidism caused by parathyroid adenoma, whereas in case of parathyroid hyperplasia a radical operative procedure is necessary to prevent recurrence of the disease. The aim of the study was to investigate morphological and cytochemical parameters differentiating parathyroid adenoma from parathyroid hyperplasia in cytologic smears in preoperative work-up of patients with hyperparathyroidism.

Methods. Fifty parathyroid cytologic smears, preoperatively obtained by ultrasound-guided aspiration biopsy, were analyzed. Fifty parathyroid cell nuclei per smear were analyzed, and the number of nucleolar organizer region (AgNOR) was determined using SFORM software (Vamstec, Zagreb). The results obtained were compared with histopathology findings.

Results. The values of nuclear size parameters obtained by morphometric measurement revealed cells with larger nuclei and greater nuclear size diversity to be found in parathyroid adenoma, thus enabling differentiation of parathyroid hyperplasia from parathyroid adenoma in many cases. However, due to overlapping of borderline values, an attempt was made to reduce the possibility of error by determining AgNOR count and structure. The results obtained showed that neither AgNOR count, nor AgNOR classification into individual AgNOR, AgNOR clusters and annular AgNOR, had any role in differentiating parathyroid hyperplasia from parathyroid adenoma.

Received: July 14, 2017; revised version accepted: November 24, 2017; published: November 24, 2017

KEYWORDS: AgNORs, parathyroid adenoma, parathyroid hyperplasia

Conclusion. Study results showed that AgNOR count and structure cannot help in determining more clearly the border between parathyroid adenoma and hyperplasia in cytologic smears.

(Fustar Preradovic Lj, Danic D, Kardum-Skelin I, Sarcevic B, Danic Hadzibegovic A. AgNOR Counts in Differential Diagnosis of Parathyroid Adenoma and Hyperplasia in Preoperative Cytologic Smears. SEEMEDJ 2017; 1(2); 19-26)

Introduction

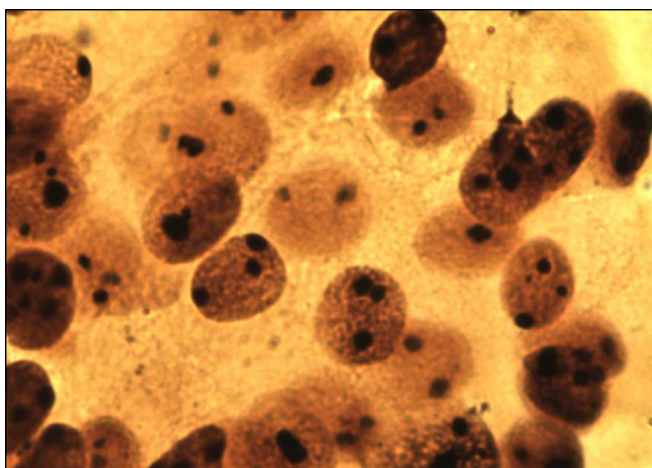
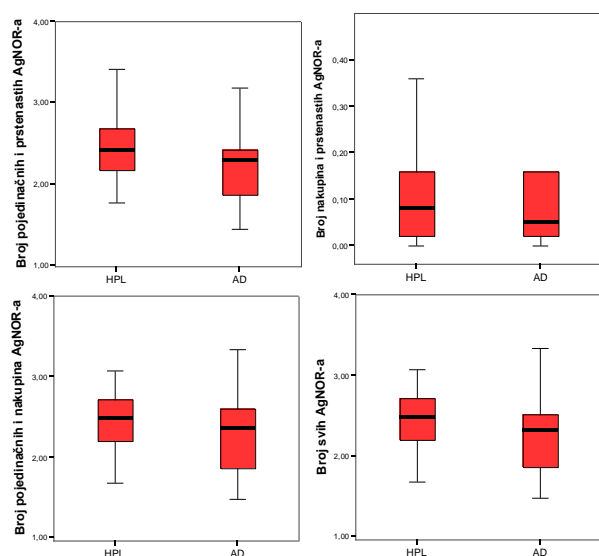
Parathyroid adenoma is mostly found as a solitary tumor, therefore minimally invasive surgery has been accepted as the method of choice in the management of hyperparathyroidism caused by parathyroid adenoma. In contrast, parathyroid hyperplasia usually develops as a secondary lesion characterized by diffuse or nodular hyperplasia of one or more parathyroid glands. Recurrence is known to occur in patients with parathyroid hyperplasia even after radical and properly performed surgery that required bilateral neck exploration, and such cases have been described in the literature, pointing to the importance of preoperative differentiation of parathyroid hyperplasia and parathyroid adenoma (1,2,3). Nucleolar organizer regions (AgNOR) are segments located on the short arm of acrocentric chromosomes in which the rRNA gene is located during the interphase and mitosis. These regions can be shown cytochemically by silver staining using the method of identifying non-histone, argyrophilic proteins connected with the sites of protein rRNA transcription (AgNOR). AgNORs play a significant role in nucleic acid transcription to proteins, thus their number may serve as an indicator of cell proliferation and tumor growth (4-7). The present study was focused on identification of new morphological parameters for differentiation of parathyroid hyperplasia from parathyroid adenoma in preoperative cytologic smears by determining the number and structure of AgNOR per nucleus.

Material and Methods

Fifty parathyroid gland smears obtained by ultrasound-guided fine-needle aspiration

biopsy (US-FNAB) were included in the study. The histopathologic diagnosis was unknown. Study material was obtained by ultrasound-guided fine-needle aspiration biopsy (UG-FNA) performed by a clinical cytologist (interventional cytologist) (8), who also performed the cytomorphological analysis of the material obtained. Each patient signed an informed consent form, while the study protocol was approved by the Hospital Ethics Committee and by the Zagreb School of Medicine Ethics Committee. US examinations were performed on an ACUSON X300 (Siemens, Erlangen, Germany) US device with 8.9 MHz and 11 MHz superficial tissue probes. UG-FNA was carried out by the free-hand technique (9). All smears were air dried and stained by the standard May-Grünwald-Giemsa (MGG) method (10) and cytochemical method of selective silver staining of AgNOR. For the cytochemical method, slides previously stained by the standard MGG method were used for allowing selection of appropriate slides with an adequate number of preserved cells. The selected slides were immersed in a solution containing 1 part of 2% gelatin solution in 1% formic acid and two parts of 50% aqueous silver nitrate solution, and then left to stay in a dark chamber at room temperature for 45 minutes. Then the slides were washed with distilled water and air dried (12). Upon silver impregnation, the AgNOR are seen as dark-brown spots in the nucleus (Figure. 1). Each slide was examined under Olympus BX 50 microscope connected to a computer image analyzer, initially at low magnification to select a representative area; then the selected area was systematically explored under immersion objective (magnification X1000) (11,14). In the present study, AgNOR analysis was performed by dividing them into three types: 1) homogeneous type (where dilutions were not even visible at magnification); 2) inhomogeneous

Southeastern European Medical Journal, 2017; 1(2)

Figure 1. PG Cells – AgNOR (Silver Nitrate, x1000)**Figure 2.** Mean value and confidence interval for AgNOR numbers

type (irregular AgNOR dilutions visible at X1000 and higher computer magnifications); and 3) annular AgNOR (annular configuration visible at standard magnification) (11,12). Intranuclear AgNOR number was determined for each AgNOR type. All patients were eventually treated surgically. Upon completion of testing, patients were divided into two groups based on histopathologic findings: parathyroid hyperplasia and parathyroid adenoma. The group of parathyroid hyperplasia included 36 (72%) patients and the group of parathyroid adenoma included 14 (28%) patients.

The basic descriptive parameters (minimal/maximal value and arithmetic mean)

and variability measures (coefficient of variation and standard deviation) were calculated for each continuous variable. The pattern of distribution was assessed for each continuous variable. Determination was made of the mean value as a measure of central tendency and a central value based on the value size, as well as standard deviation (SD) as a measure of deviation of arithmetic means of samples from one population from arithmetic means of the other population. The correlation of continuous variables in the two groups was analyzed by the Mann-Whitney test as the most sensitive nonparametric test, along with the rank-sum calculation (13).

Results

Individual AgNOR count per nucleus was lower in the group of patients with parathyroid adenoma than in those with parathyroid hyperplasia, but the difference did not reach statistical significance ($P=0.167$) (Table 1). The mean number of AgNOR clusters was comparable in the two groups ($P=0.763$) (Table 2). The mean number of individual AgNOR and AgNOR clusters, the number of AgNOR clusters and annular AgNOR, the number of individual and annular AgNOR, and the number of all AgNOR, were greater in the group of patients with parathyroid hyperplasia than in those with parathyroid adenoma; however, the difference was not statistically significant ($P=0.257$, $P=0.846$, $P=0.151$, $P=0.158$) (Table 3) (Fig. 2).

Discussion

Preoperative morphological finding of parathyroid hyperplasia or parathyroid adenoma is fundamental for further treatment of patients with hyperparathyroidism. Optimal patient management requires the highest possible differentiation between patients with parathyroid hyperplasia and those with parathyroid adenoma because minimally invasive surgery has been accepted as the method of choice in the management of hyperparathyroidism due to parathyroid adenoma, whereas recurrence is quite frequent in patients with parathyroid hyperplasia, thus

Table 1. Mean values of individual AgNOR parameters according to patient groups

Parameter	Hyperplasia				Adenoma				p†
	Mean	SD*	Min	Max	Mean	SD*	Min	Max	
Individual AgNOR count	2.48	0.63	1.12	4.90	2.25	0.51	1.44	3.18	0.167

*standard deviation; †Mann-Whitney test

Table 2. Median of AgNOR cluster number according to patient groups

Parameter	Hyperplasia				Adenoma				p†
	Median	25%-75%*	Min	Max	Median	25%-75%*	Min	Max	
Number of AgNOR clusters	1.00	1 - 1	0.00	1.25	1.00	1 - 1	0.00	1.14	0.763

* interquartile range; †Mann-Whitney test

Table 3. Median of AgNOR count according to patient groups

Parameter	Hyperplasia				Adenoma				p†
	Median	25%-75%*	Min	Max	Median	25%-75%*	Min	Max	
Number of individual AgNOR and AgNOR clusters	2.48	2.16-2.74	1.12	5.20	2.36	1.86-2.62	1.48	3.34	0.257
Number of AgNOR clusters and annular AgNOR	0.08	0.02-0.16	0.00	1.00	0.05	0.02-0.37	0.00	1.00	0.846
Number of individual and annular AgNOR	2.42	2.16-2.69	1.12	4.90	2.29	1.85-2.44	1.44	3.18	0.151
Number of all AgNOR	2.48	2.16-2.74	1.12	5.20	2.31	1.86-2.54	1.48	3.34	0.158

* interquartile range; †Mann-Whitney test

the other hand, subtotal resection of parathyroid gland or complete excision with partial parathyroid autotransplantation is performed on surgical removal of enlarged parathyroid glands in order to prevent consequential hypoparathyroidism; therefore, parathyroid tumor should be differentiated preoperatively from hyperplastic tissue. On morphometric measurements performed by the system of image analysis, the subjective investigator's error is reduced by use of quantitative parameters. In our earlier research, subsequent correlation with histopathologic findings revealed higher values of nuclear area, circumference, minimal radius, convexity and width in the group of patients with parathyroid hyperplasia compared with the group of patients with parathyroid adenoma (14). When extrapolated to cell morphology in cytologic smear, cells with greater nuclei were found in the group with hyperplasia in relation to those found in the group with adenoma. In the group with parathyroid hyperplasia, higher values of standard deviation were recorded for each of these parameters compared to parathyroid adenoma; applied to cell morphology in cytologic smear, it indicates greater heterogeneity and size diversity in hyperplasia as compared with adenoma (14). However, as the borderline values of the parameters analyzed showed an occasional overlap, we tried to more clearly determine the border between adenoma and hyperplasia in cytologic smears using additionally the cytochemical method and determination of nuclear AgNOR count. As the AgNOR count correlates with the level of DNA transcription and degree of cell proliferation, the features of nuclear organization provide a way to simply distinguish resting cells from those involved in the cell cycle (4-7,15,16). Black spots can be visualized in all cells of parathyroid epithelium by staining the nucleoli and other structures of nucleolar organization. AgNOR clusters were only detected in proliferating cells of various tissues, whereas individual spots were found in mature, nonproliferating cells (17-20). These findings point to physiological differences between individual AgNOR and AgNOR clusters, thus justifying their separate evaluation. There are literature reports on the studies where

AgNOR count per nucleus was determined in postoperative parathyroid histopathologic smears and significant difference was found between parathyroid carcinoma and benign parathyroid lesions, while no such difference in AgNOR count per nucleus was recorded between parathyroid adenoma and parathyroid hyperplasia (21,22). Boquist reports on the comparable AgNOR count per nucleus in parathyroid adenoma and liver adenoma (2.6 and 2.3 AgNOR per nucleus, respectively), breast fibroadenoma and thyroid follicular adenoma (23). Mourad et al. have introduced the mean AgNOR (mAgNOR) count per nucleus, which correlates with ploidy (aneuploid cells have ≥ 2.4 mAgNOR per cell and diploid cells < 2.4 mAgNOR per cell (24). In the present study, AgNOR analysis was performed by dividing them into three types: homogeneous, inhomogeneous and annular AgNOR (8). As AgNOR clusters are only found in proliferating cells, the number of AgNOR clusters is understandably low in adenoma and hyperplasia; instead, they are only found in individual cells. In our study, annular AgNOR were only detected in several individual nuclei. Irrespective of their number, all spots were enumerated and their role in differentiating parathyroid hyperplasia from parathyroid adenoma was assessed upon statistical data processing. The mean number of all AgNOR per nucleus was greater in parathyroid hyperplasia compared to parathyroid adenoma (2.48 vs. 2.31); the difference is not statistically significant ($P=0.158$) (Table 3) and is consistent with the values reported by Boquist in histopathologic material (23). Statistical data processing indicated the AgNOR classification according to their proliferation activity into individual AgNOR, AgNOR clusters and annular AgNOR to have no value in differentiating parathyroid hyperplasia and parathyroid adenoma. These cells are low-proliferating cells predominated by homogeneous AgNOR, while AgNOR clusters and annular AgNOR are few and found in comparable number in both parathyroid hyperplasia and parathyroid adenoma. Cytologic smears are considered more appropriate for AgNOR determination than histologic sections because the spots are more

easily enumerated and individual spots are better visualized within the nucleoli in cytologic smears. In the latter, whole cells are seen, thus the number of spots is expectedly higher than in histologic sections. Yet, even materials that are so different can be compared if the ratio of AgNOR count and nucleus area is determined. This is of great value because there are few reports on studies performed on preoperatively obtained cytologic FNAB smears, thus obviating possible errors caused by different sample processing (25-27). Our own observations and subjective assessment that differences in nuclear size are substantial features to differentiate parathyroid adenoma and parathyroid hyperplasia in cytologic smear, and that these features can help differentiate these two entities in preoperative cytologic US-FNAB smears, were quantitatively confirmed by use of objective morphometric measurement and statistical analysis of the data obtained. Our results still point to justifiable utilization of cytodiagnosis, along with morphological and morphometric methods in the preoperative identification of parathyroid tumors. Particular nuclear morphometric parameters may influence the selection of patients as potential candidates for minimally invasive or radical surgical procedure (14). However, the borderline values of the study parameters may occasionally overlap, and quantitative determination of AgNOR per nucleus in preoperative cytologic smears cannot help in differentiating parathyroid adenoma from parathyroid hyperplasia, thus it cannot be used as a diagnostic criterion, which is consistent with literature data obtained on postoperative histopathology material (23,28,29).

Acknowledgement

We would like to thank Drazen Svagelj, MD, PhD for assistance and for comments that greatly improved the manuscript.

Funding: No specific funding was received for this study.

Competing interests: None to declare.

References

1. Laird AM, Libutti SK. Minimally Invasive Parathyroidectomy Versus Bilateral Neck Exploration for Primary Hyperparathyroidism. *Surg Oncol Clin N Am* 2016;25(1):103-18.
2. Rosato L, Raffaelli M, Bellantone R, Pontecorvi A, Avenia N, Boniardi M, Brandi ML, Cetani F, Chiofalo MG, Conzo G, De Palma M, Gasparri G, Giordano A, Innaro N, Leopaldi E, Mariani G, Marcocci C, Marini P, Miccoli P, Nasi P, Pacini F, Paragliola R, Pelizzo MR, Testini M, De Toma G. Diagnostic, therapeutic and healthcare management protocols in parathyroid surgery: II Consensus Conference of the Italian Association of Endocrine Surgery Units. *J Endocrinol Invest* 2014;37(2):149-65.
3. Miccoli P, Materazzi G, Baggiani A, Miccoli M. Mini-invasive video-assisted surgery of the thyroid and parathyroid glands: a 2011 update. *J Endocrinol Invest*. 2011;34(6):473-80.
4. Olson M.O. and Dunder, M. Nucleolus: Structure and Function. 2015. eLS. 1-9.
5. Storck S, Shukla M, Dimitrov S, Bouvet P. Functions of the histone chaperone nucleolin in diseases. *Subcell Biochem* 2007;41:125-44.
6. Box JK, Paquet N, Adams MN, Boucher D, Bolderson E, O'Byrne KJ, Richard DJ. Nucleophosmin: from structure and function to disease development. *BMC Mol Biol* 2016;17(1):19.
7. Ginisty H, Sicard H, Roger B, Bouvet P. Structure and functions of nucleolin. *J Cell Sci* 1999;112:761-7.
8. Lieu D. Cytopathologist-performed ultrasound guided fine-needle aspiration of parathyroid lesions. *Diagn Cytopathol* 2010;38:327-32.
9. Tomić Brzac H, Bence-Žigman Z, Dodig D. Ultrazvuk vratnih organa. IV. poslijediplomski tečaj trajnog usavršavanja liječnika I kategorije. Zagreb: Medicinski fakultet Sveučilišta u Zagrebu, Klinički zavod

- za nuklearnu medicinu i zaštitu od zračenja KBC Rebro, 2002. (in Croatian)
10. Keebler CM, Facik M. Cytopreparatory techniques. In: Bibbo M, Wilbur DC, ed. *Comprehensive Cytopathology* (3rd). Philadelphia: WB Saunders, 2008; 977-1003.
 11. Fustar Preradovic Lj. Cytologic preoperative differentiation of parathyroid lesions. School of Medicine University of Zagreb, Zagreb 2016; Ph.D. thesis (in Croatian)
 12. Kardum-Skelin I. Morfometrijski i kinetički parametri kao dijagnostički i prognostički čimbenici leukemijskih oblika kroničnih limfoproliferativnih bolesti. School of Medicine University of Zagreb, Zagreb 2008; Ph. D. thesis (in Croatian)
 13. Ivanković D, Božikov J, Kern J, Kopjar B, Luković G, Vuletić S, Suntešić L, Tišljarić N, Čar M. Osnove statističke analize za medicinare. Zagreb, Biblioteka udžbenici i priručnici Medicinskog fakulteta u Zagrebu, 1988. (in Croatian)
 14. Fustar-Preradovic L, Sarcevic B, Danic D. Morphometry in differential diagnosis of pathologically altered parathyroid glands: adenoma and hyperplasia. *Coll Antropol* 2012;36(suppl 2):47-51.
 15. Tajrishi MM, Tuteja R, Tuteja N. Nucleolin. The most abundant multifunctional phosphoprotein of nucleolus. *Commun Integr Biol* 2011;4(3):267-75.
 16. Gaume X, Place C, Delage H, Mongelard F, Monier K, Bouvet P. Expression of Nucleolin Affects Microtubule Dynamics. *PLoS One* 2016;16:11(6):e0157534.
 17. Ploton D. Structure and molecular organization of the nucleolus. *Zentralbl Pathol* 1994;140: 3-6.
 18. Egan MJ, Crocker J. Nucleolar organizer regions in pathology. *Br J Cancer* 1992;65:1-7.
 19. Aubele M, Biesterfeld S, Derenzini M, Hufnagl P, Martin H, Ofner D, Ploton D, Rüschoff J. Guidelines of AgNOR quantitation. Committee on AgNOR Quantitation within European Society of Pathology. *Zentralbl Pathol* 1994;140:107-8.
 20. Hufnagl P, Guski H, Schulz HJ. Measuring of AgNORs using image analysis. *Zentralbl Pathol* 1994;140:31-5.
 21. Löwhagen T, Sprenger E. Cytologic presentation of thyroid tumors in aspiration biopsy smear. A review of 60 cases. *Acta Cytol* 1974;18:192-7.
 22. Van Diest PJ, Baak JPA. Morphometry. In: Bibbo M, ed. *Comprehensive cytopathology*. Philadelphia: WB Saunders, 1991:946-64.
 23. Boquist LL. Nucleolar organizer regions in normal, hyperplastic and neoplastic parathyroid glands. *Virchows Arch A Pathol Anat Histopathol* 1990;417:237-41.
 24. Mourad WA, Pugh WC, Huh YO, Keating MJ. Cell kinetic analysis of interleukin-2 receptor-tested chronic lymphocytic leukemia using the AgNOR silver stain. *Am J Clin Pathol* 1994;101:300-4.
 25. Rüschoff J, Plate KH, Contractor H, Kern S, Zimmermann R, Thomas C. Evaluation of nucleolar organizer regions (NORs) by automatic image analysis: a contribution to standardization. *J Pathol* 1990;161:113-8.
 26. Weeks SC, Beroukas D, Jarvis LR, Whitehead R. Video image analysis of AgNOR distribution in the normal and adenomatous colorectum. *J Pathol* 1992;166:139-45.
 27. Tsai TH, Chang TC, Chiang CP. Nuclear area measurements of parathyroid adenoma, parathyroid hyperplasia and thyroid follicular adenoma. A comparison. *Anal Quant Cytol Histol* 1997;19:45-8.
 28. Tuccari G, Abbona GC, Giuffrè G, Papotti M, Gasparri G, Barresi G, Bussolati G. AgNOR quantity as a prognostic tool in hyperplastic and neoplastic parathyroid glands. *Virchows Arch* 2000;437:298-303.

29. Kanematsu E, Matsui H, Deguchi T, Yamamoto O, Korematsu M, Kobayashi A, Nezasa SI, Yamamoto N, Takeuchi T, Tanaka T, Kawada Y. Significance of AgNOR counts for distinguishing carcinoma from adenoma and hyperplasia in parathyroid gland. *Hum Pathol* 1997;28:421-7.