

Civilian Casualty of Landmine – The Pattern of Injury and Course of Treatment

Naranda Aljinović Ratković¹, Vatroslav Bubalo², Ana Havelka Meštrović³, Vlatko Mičković⁴, Zoran Lončar⁵, Tihomir Bradić⁶

¹Department of Maxillofacial Surgery, School of Medicine, University of Zagreb, University Hospital Dubrava, Zagreb, Croatia

²Department of Prosthetic Dentistry, University Hospital Dubrava, Zagreb, Croatia

³Department of Psychiatry, University Hospital Dubrava, Zagreb, Croatia

⁴Department of Anthropology, University of Zagreb, Zagreb, Croatia

⁵Department of Traumatology, University Hospital »Sestre Milosrdnice«, Zagreb, Croatia

⁶Department of Internal Medicine, University Hospital Dubrava, Av. Gojka Šuška 6, Zagreb

ABSTRACT

In Croatia civilian casualties of landmine explosions 20 years after the war are still present. The presented case is a 42 years old housewife who sustained multiple body and face injuries while cleaning her courtyard. The treatment was performed in several steps. Initial treatment included thoracic drainage, abdominal surgery and the rigid fixation of the mandibular defect. Four months later mandibular reconstruction with free flap was performed. After plate removal the restoration of dental status was performed by partial denture although the application of dental implants would be superior. The optimal rehabilitation was omitted because health insurance policy does not provide the reimbursement of dental implants costs for outpatients even in cases of landmine victims traumatic teeth loss.

Key words: landmine, civilian casualty, mandibular injury, reconstruction, prosthetic rehabilitation

Introduction

During the Homeland war in Croatia (1991–1995) 8 000 civilian casualties were injured, killed or sexually abused. After the war 495 square kilometres of Croatia territory are still covered with mines (data of year 2015 – www.hcr.hr). It is estimated that more than 50.000 landmines are still present. In the year 2009 Croatian Parliament presented National program for mines, and it is expected that mines sweeping will end in 2019. The peacetime deaths caused by triggering of antipersonnel landmines are also a problem in other European countries¹ and the expenses of medical care and rehabilitation of landmine victims have to be considered².

Maxillofacial explosive wounds are extremely rare in the time of peace. The patterns of facial fracturing in explosive or missile related injury are completely different from the patterns of blunt trauma (RTA, fistfight, falls etc.)³. Particles from explosive devices have tremendous kinetic energy and always cause multiple organ injuries⁴. At the site of impact the energy transfer disrupts the bone into numerous small fragments. Fragments are displaced

and larger ones act as secondary projectiles⁵. Radial fracturing develops from indirect energy transfer through the bone. Common fracture lines are seldom observed, instead of a fracture line there is a fractured area. Central part of the fractured area is usually the area of bone loss, as the bone pieces are propelled aside or blown out through the exit wound. Around the defect area there is a large comminution area.

The bone particles are also usually lost or removed later during wound exploration and definitive bone loss is even greater. In transverse penetration fracture is often bilateral. The large bone defect is the common finding and mandibular reconstruction is often required in definitive treatment. In spite of the consecutive reconstructive procedures, the sequelae of these injuries in the function and aesthetic appearance in these patients are frequently permanent.

We present a long term survey of a case of 42 years old house wife wounded by military explosive device eight years after the war.

Case Report

In May 2003, a 42 year old female sustained multiple body and head injuries by the explosion of the PMA-2 blast antipersonnel mine during the cleaning of the courtyard in Zagreb surrounding. The usual wounding by PMA-2 is foot injury as it occurs by footstep overpressure, but this mine was activated during work with a hay rake. Due to a bending from the waist body position the mine particles wounded her arm, thorax and abdomen. Although body wounds were small, pneumothorax and the perforation of the colon occurred. The greatest defect was on the right side of the face: 30x40 mm irregular defect of the soft tissue in the masticatory and cheek region and the comminution of the complete angle and body of the mandible with teeth loss (all right lower molars and premolars) and bone loss (angle and most of the body) (Figure 1).

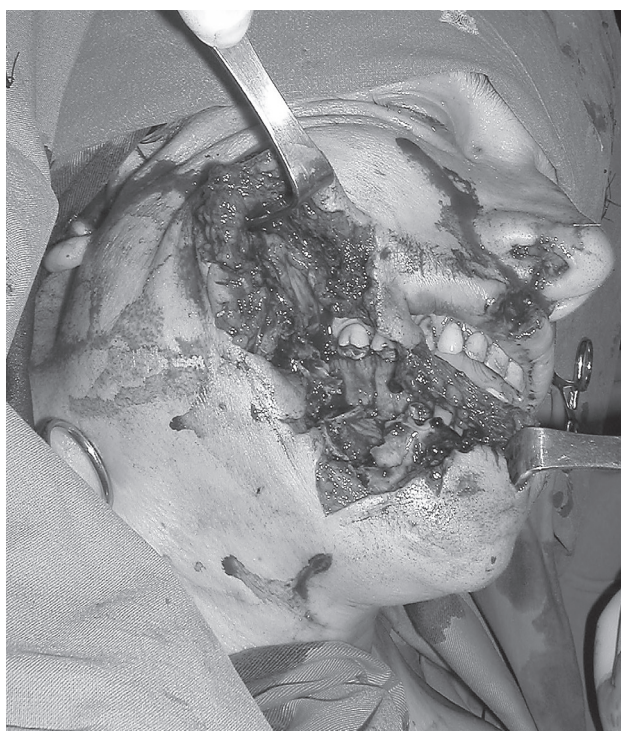

Fig. 1. The extent of the soft tissue damage and mandible defect in a 24 year old female injured by the landmine explosion.

The initial surgery included the thoracic drainage, abdominal exploration with the colon suturing, debridement of multiple body wounds, tracheotomy and first step surgery of facial injury. Orofacial wound was cleaned from the device particles and free bony and teeth particles. The remaining mandible parts were reduced into occlusal position (Figure 2a) and fixed by the reconstructive plate bridging the defect (Figure 2b). The wound was closed by a local rotational flap, a partial skin necrosis healed spontaneously (Figure 3).

Four months later the mandibular reconstruction was performed by the «L» shaped 14 x 5 cm bone transplant harvested from the iliac crest vascularized by deep cir-

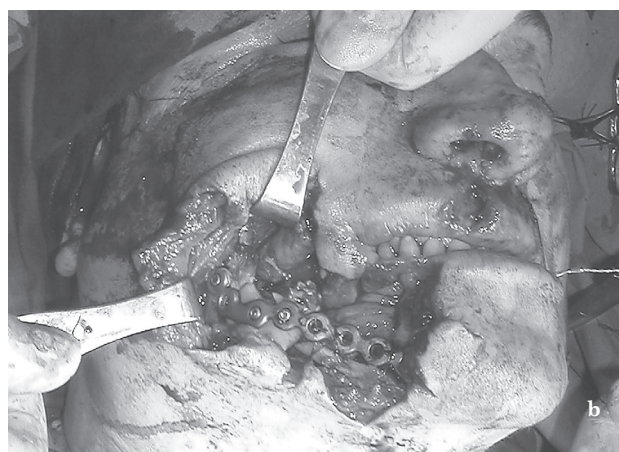
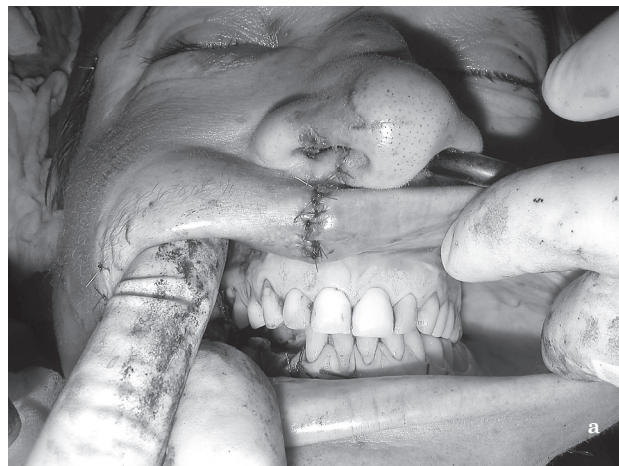

Fig. 2. The occlusal relationship was achieved (a) by the rigid fixation of the jaw using a titanium reconstructive plate (b).

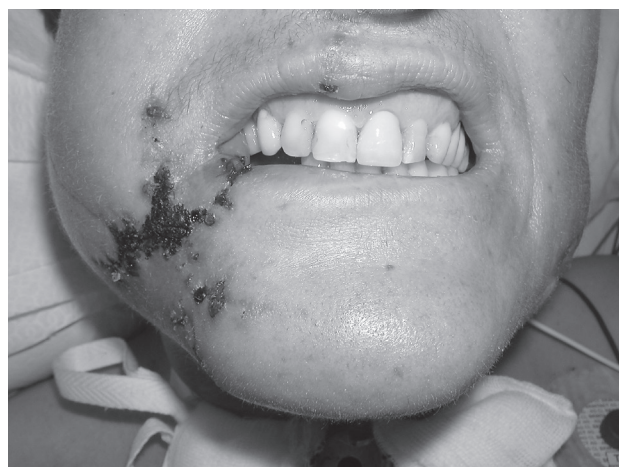

Fig. 3. Early result after first surgery – a small wound break has healed spontaneously.

cumflex iliac artery and vein. The graft was adapted to the mandible defect and fixed to the refreshed stumps by reconstructive plate (Figure 4). The occlusion of remaining teeth was completely preserved. No major complica-

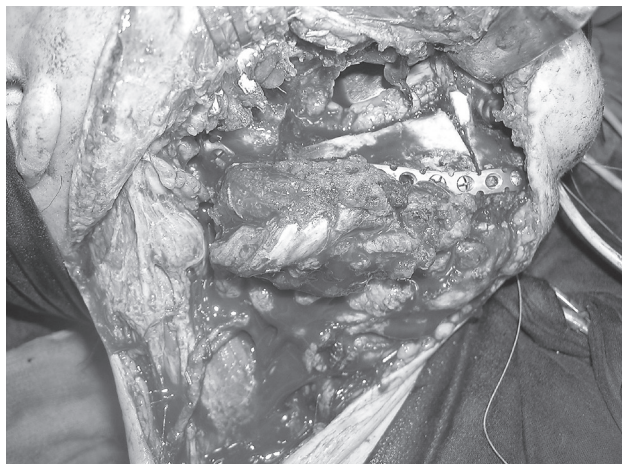

Fig. 4. Four months later the defect of the mandible was reconstructed by the iliac crest microvascular flap.

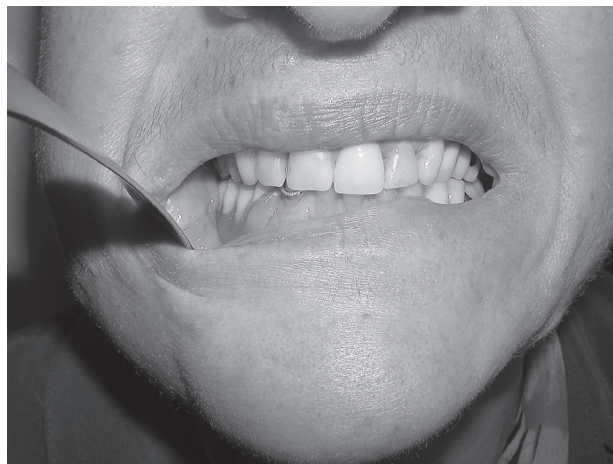


Fig. 5. The result after plate removal and prosthetic rehabilitation by partial denture.

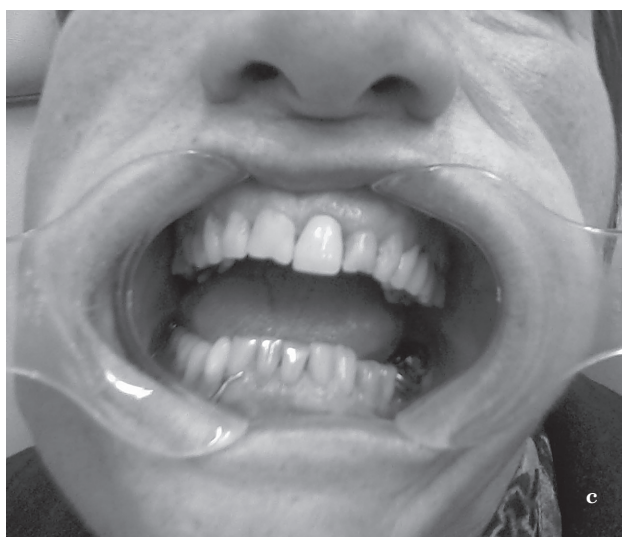
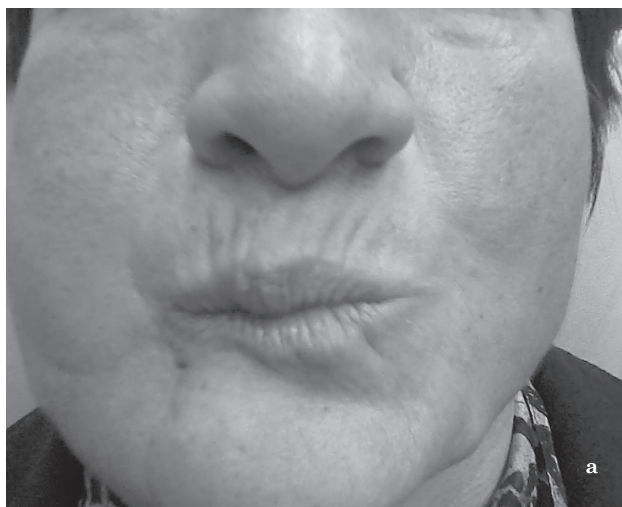
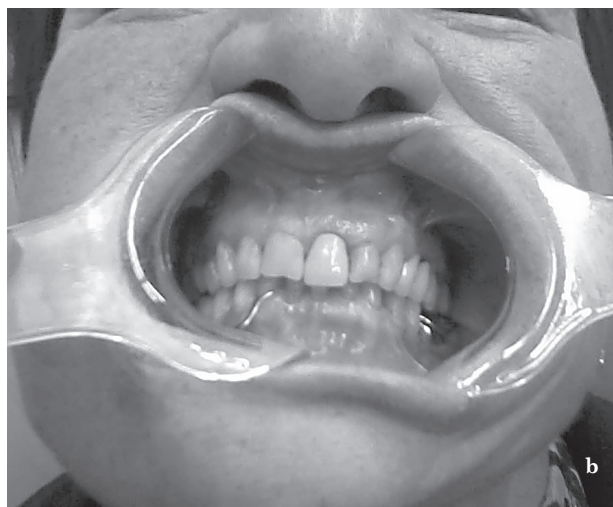Fig. 6. The appearance of the patient ten years later: lower lip dysfunction due to marginal branch injury (a), and limitation of mouth opening (b) are permanent sequelae of the injury.



tions or donor site morbidity occurred. A year later the reconstructive plate was removed and minor outer scar correction was performed in 2005. At the follow up scans no bony resorption was observed and the fusion with the mandible was uneventful.

The restoration of teeth loss was performed by partial denture (Figure 5) although dental implants would be more appropriate but patient could not afford the expenses. In a follow up after ten years a facial asymmetry is still present due to the injury of marginal branch of the facial nerve, the mouth opening is limited (Figures 6 a and b). The dental occlusion is good but the function may improve with application of dental implants (Figure 6c).

Discussion

Reconstruction of the bone defect is often the main challenge in definitive surgical treatment of war-related injuries. According to the general rules for treatment of war injuries the high risk of infection and wound breakdown is expected in cases with extensive soft tissue loss

and bone grafting should be delayed⁶. Although there are experiences with early bone grafting of major gunshot injuries, delayed bone grafting is still advocated for lower jaw reconstruction⁷. The risk of contamination and infection in explosive wounds we considered too high for primary grafting. The other reason for delay was a risk of oral wound breakdown and graft exposure to saliva. If grafting is performed through extraoral incision, after the intraoral wound healed, the contamination with saliva can be avoided. At initial surgery the most important is to maintain the undamaged portions of the mandible in correct anatomical relationship⁷. In our patients the bridging was performed by reconstructive plate to maintain the occlusal relationship. The initial treatment has a great influence on final reconstruction⁵; after preventing the displacement of mandibular stumps by scarring, the subsequent bone grafting is more easy and safe.

Most of the mandibular reconstructions in the time of peace are required for cancer surgery but the goal of orofacial reconstruction in trauma patients is quite different. In cancer patients complete functional restoration is seldom expected, the main goal is absence of the disease, and neither patient nor surgeon consider the operation unsuccessful if the dentures cannot be applied, or if residual flap bulk deforms the chin. In trauma case, both patient and surgeon desire complete masticatory function restoration, as well as normal aesthetic appearance.

Nowadays standard for the mandibular reconstruction is a free microvascular flap. Various microvascular

flaps have been applied, free vascularized fibular graft, osteocutaneous radial forearm flap or composite groin flap are recommended⁸.

The flap used in our casualty is well known and proven as excellent technique in mandibular reconstruction⁹. Therefore we have little to add to the reports of others except that we share their good experiences. Concerning the reconstructive plate at the initial fixation and the method of graft fixation we did not observe any complications.

Although the use of dental implants is more challenging in war-related facial bone injuries the overall success in large series is over 95%¹⁰. In our case the main goal in occlusal performance was not completed because the dental implants cost is not covered by health insurance even in a victim of the teeth loss related to landmine injury. The authors hope that this report may initiate the re-evaluation on this matter.

The importance of recognizing the need of proper care for the landmine victims is emphasized as a significant problem in other countries¹¹.

Conclusion

The landmine injuries are still to be expected in certain areas of Croatia. These devastating injuries require prolonged treatment and the optimal and complete treatment should be facilitated.

REFERENCES

1. PAVLIDIS P, KARAKASI V, *Am J Disaster Med*, 10 (2015) 167. DOI: 10.5055/ajdm.2015.0199. – 2. ANDERSSON N, DA SOUSA CP, PAREDES S, *BMJ*, 311 (1995) 718-21. DOI: 10.1136/bmj.311.7007.718. – 3. VIANO DC, BIR C, WALILKO T, SHERMAN D, *J Trauma Injury Infect Crit Care*, 56 (2004) 1305. DOI: 10.1097/01.TA.0000064209.21216.4E. – 4. GOKEL T, *Oral Maxillofacial Surg Clin N Am*, 17 (2005) 281. DOI: 10.1016/j.coms.2005.05.002. – 5. GIBBONS AJ, BREEZE A, *J Mil Veterans Health*, 19 (2011) 15. – 6. POWERS DB, WILL MJ, BOURGEOIS SL, HATT HD, *Oral Maxillofacial Surg Clin N Am*, 17 (2005) 341. DOI:10.1016/j.coms.2005.05.003. – 7. MOTAMEDI

- MHK, *J Oral Maxillofac Surg*, 61 (2003) 1390. DOI: 10.1016/j.joms.2003.07.001. – 8. MARKIEWICZ MR, BELL RB, BUITG, DIERKS EJ, RUIZ R, GELESKO S, PIRGOUSIS P, FERNANDES R, *Microsurgery*, 35 (2015). DOI: 10.1002/micr.22471. – 9. RODRIGUEZ ED, BLUEBOND-LANGNER R, MARTIN M, MANSON PN, *Atlas Oral Maxillofac Surg Clin North Am*, 14 (2006) 151. – 10. MOTAMEDI MHK, HASHEMI HM, SHAMS MG, NEJAD AN, *J Oral Maxillofac Surg*, 57 (1999) 907. DOI: 10.1016/S0278-2391(99)90005-8. – 11. SHIDARA EK, HOSODAM, VUTY S, TORIUMI T, SETO K, *Southeast Asian J Trop Med Public Health*, 38 (2007) 913.

N. Aljinović Ratković

*Department of Maxillofacial Surgery, School of Medicine, University of Zagreb, University Hospital Dubrava, Zagreb, Av. Gojka Šuška 6, Croatia
e-mail: naljinov@kbd.hr*

CIVILNE ŽRTVE MINA – UZORCI OZLJEDA I TERAPIJE

SAŽETAK

U Hrvatskoj i 20 godina nakon rata dolazi do stradavanja civila zbog eksplozija mina. Prikazani slučaj odnosi se na 42-godišnju kućanicu koja je tijekom čišćenja dvorišta pretrpjela više ozljeda tijela i lica. Liječenje je provedeno u nekoliko koraka. Početni tretman je uključivao torakalnu drenažu, abdominalni kirurški zahvat i fiksaciju donje čeljusti. Četiri mjeseca kasnije izvedena je rekonstrukcija donje čeljusti. Nakon uklanjanja pločice, protetska rehabilitacija učinjena je s parcijalnom protezom iako bi upotreba zubnih implantata bila bolje rješenje. U ovom slučaju nije bilo moguće učiniti optimalnu rehabilitaciju jer policia zdravstvenog osiguranja ne pokriva naknadu troškova zubnih implantata za ambulantne pacijente, čak i u slučajevima traumatičnog gubitka zuba kod žrtava mina.