

## Laparoscopic management of interstitial pregnancy: case report

*Laparoskopsko liječenje ektopične trudnoće: prikaz slučaja*

**Branko Dukić, Luka Matak, Tina Žic, Ivan Kolega, Magdalena Matak\***

---

### Summary

The traditional treatment of interstitial pregnancy has been horn resection or hysterectomy in cases with severely damaged uteri. Recently, more conservative operations have been developed, and operative laparoscopy has provided yet another management option. This report describes the unusual presentation of symptoms, laparoscopic management of large interstitial pregnancy and reviews the techniques and outcomes of conservative repair that have been reported in literature.

**Key words:** interstitial pregnancy, laparoscopic management, ectopic pregnancy

---

### Sažetak

Resekcije roga uterusa ili histerektomije, tradicionalno su se izvodile kod liječenja intersticijske trudnoće u slučajevima teško oštećene maternice. Suvremena medicina u ovakvim slučajevima razvila je poštenije operativne zahvate uključujući laparoskopsku metodu liječenja koja je unijela dodatne opcije zbrinjavanja bolesnica s intersticijskom trudnoćom. Ovaj prikaz slučaja opisuje neuobičajenu kliničku prezentaciju, te zbrinjavanje intersticijske trudnoće laparoskopskim putem i osvrt na tehnike i ishode konzervativnog popravka uterusa koji su prijavljeni u literaturi.

**Ključne riječi:** intersticijska trudnoća, laparoskopsko liječenje, ektopična trudnoća

*Med Jad 2018;48(3):157-160*

### Introduction

Ectopic pregnancy is a high-risk condition that occurs in 1 to 2 percent of reported pregnancies. This small proportion disparately accounts for 6% of all pregnancy-related deaths.<sup>1</sup> Tubal anomalies, which can be induced by endometriosis or uterine leiomyomata, anatomical damage due to pelvic inflammatory disease, prior ectopic pregnancies, salpingectomy, history of genital infections or infertility and current smoking are most strongly associated with ectopic pregnancy.<sup>2,3</sup> Interstitial pregnancy is a rare form of ectopic pregnancy with a significant risk for morbidity accounting for 2-4% of all ectopic pregnancies. It is defined by its location lateral to the round ligament with highly suggestive,

but nonspecific, sonographic features of interstitial line sign, empty cavity and eccentric gestational sac with a layer of myometrium around it.<sup>4</sup> It is interesting that the surrounding myometrial tissue may allow the progression of pregnancy into the second trimester which could cause catastrophic hemorrhage with a mortality rate of up to 2%. This high mortality rate is partially due to the difficult challenging diagnosis as well as the amount of bleeding.

### Case report

The patient was a 31-year-old (gravida 1, para 1) female with an estimated gestational age of 5 5/7 weeks by a confirmed last menstrual period, who came to her physician because of a positive urine pregnancy

---

\* **General hospital Zadar, Department of Obstetrics and Gynecology** (Branko Dukić, MD, Luka Matak, MD, Tina Žic, MD, Ivan Kolega, MD); **Department of Dermatovenerology** (Magdalena Matak, MD)

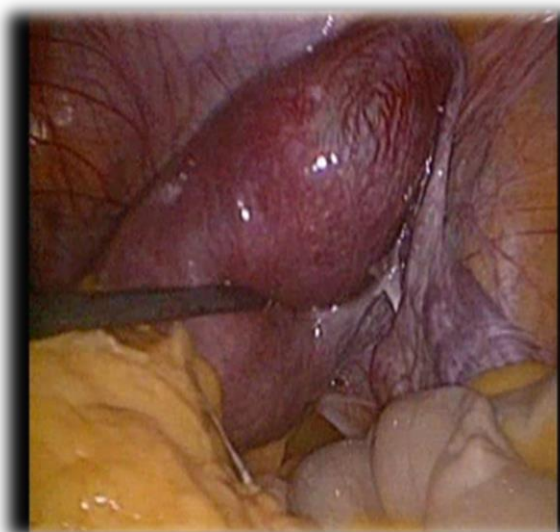Correspondence address / *Adresa za dopisivanje:* Luka Matak, Department of Gynecology and Obstetrics, General Hospital Zadar – Croatia, Resident. E-mail address: [lmatak1011@gmail.com](mailto:lmatak1011@gmail.com) Work address: Bože Peričića 5, 23000 Zadar, Croatia, GSM: +385917624185

Primljeno/Received 2017-11-07; Ispravljeno/Revised 2017-12-14; Prihvaćeno/Accepted 2018-01-18

test. She was not complaining of spotting vaginal, abdominal pain and passage of tissue. Her menstrual periods had been regular, lasting 5 days with a 28-day cycle. Her medical history revealed that she had positive anti-HBc 15 years ago and she was without any therapy. She had transplantation of the bone marrow because of aplastic anemia 10 years ago and her past obstetric history was notable only for one uncomplicated spontaneous vaginal delivery 5 years ago. It is worth mentioning that the patient had biopsy, conisation and a large loop excision transformation zone because of CIN III 7 years ago.

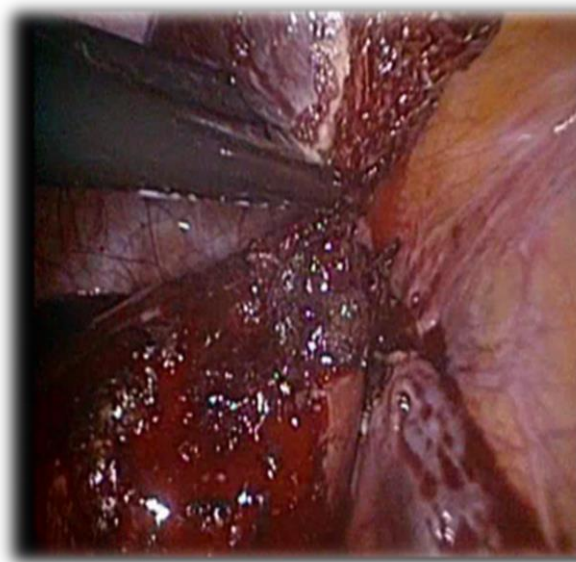
Neither abdominal nor pelvic examination revealed any tenderness; her uterus was painless, asymmetrically enlarged to 8-week size, there was no palpable adnexal mass. An ultrasound examination revealed a gestation sac in the proximal portion of the fallopian tube surrounded by the 5 mm thin layer of the myometrium. There was a fetal pole detected with positive heartbeat. The crown rump length was measured 21 mm corresponding with 8 6/7 weeks of gestation meaning this pregnancy has been achieved in the previous menstrual cycle. There was no free fluid in the cul-de-sac. Serum  $\beta$ -human chorionic gonadotrophin ( $\beta$ HCG) concentration was more than 10 000 IU/L. The patient was counselled regarding the findings and elected to proceed with laparoscopic management.

The patient was taken to the theatre and placed in dorsal lithotomy position in endotracheal anesthesia. After insufflation and placing laparoscope, we saw a 5 cm bulge in the right horn with normal ovaries (left corpus luteum) and contralateral tube (Picture 1).



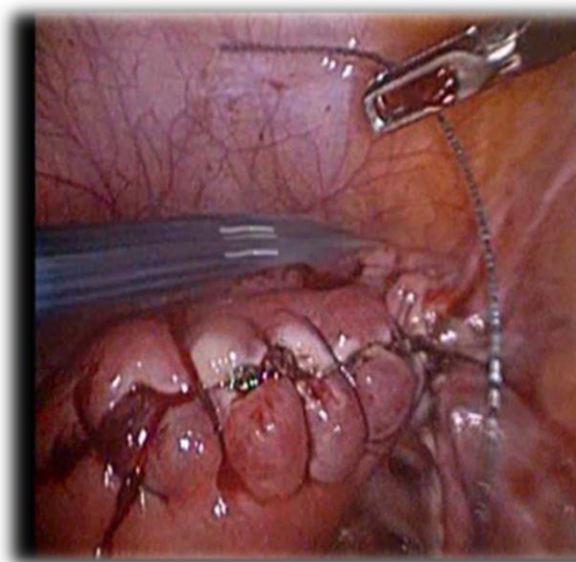
Picture 1 Laparoscopic view of interstitial pregnancy in right horn  
*Slika 1. Laparoskopski pregled interstijske trudnoće u desnom rogu*

The right fallopian tube was swollen, and the left one was intact, without adhesions. Without using vasopressin solution or methotrexat, we performed circular excision of the right uterine horn with ipsilateral salpingectomy (Picture 2).



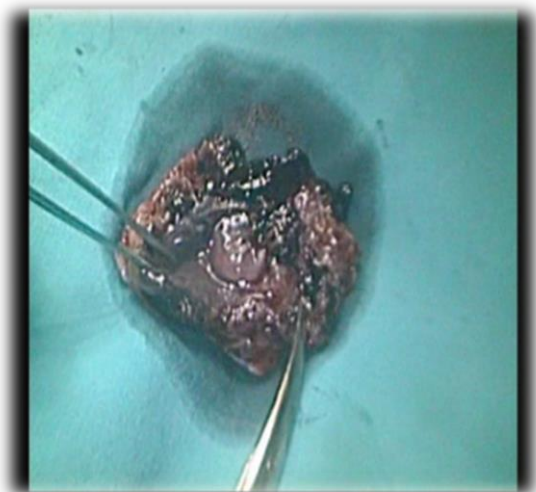
Picture 2 After horn excision and right salpingectomy  
*Slika 2. Nakon rezanja roga i desne salpingektomije*

The remaining myometrial layer was cauterized to obtain exact hemostasis and continuous single layer running suture, V-Lock was placed (Picture 3).



Picture 3 Appearance of uterus after placing V-lock suture  
*Slika 3. Izgled uterusa nakon postavljanja V-loc suture*

The specimen was retrieved from the pelvis with the endoscopic bag and sent to pathohistology (Picture 4) where the diagnosis of an ectopic interstitial pregnancy was confirmed. Blood loss during surgery was minimal (less than 70 mL).



Picture 4 Right interstitial pregnancy after removing from the abdominal cavity. Diameter of removed tissue is around 5 cm

*Slika 4. Desna intersticijska trudnoća nakon odstranjivanja iz abdominalne šupljine. Promjer odstranjenog tkiva je cca 5 cm*

The patient recovered without any complications. After the surgical procedure, we continued to follow up the concentration of serum  $\beta$ HCG (first post-operative day 8048 IU/L, five week after operation  $< 2$ ).

### Discussion

There are several ways of treating ectopic pregnancy such as expectant management, methotrexate and surgical treatment. Candidates for successful expectant management should be asymptomatic and have no evidence of rupture or hemodynamic instability. In this report, the patient, who had a large ectopic gestation with positive heartbeat, was not a candidate for methotrexate management but was haemodynamically stable and a candidate for laparoscopic surgery.<sup>5</sup> Approximately one fourth of women presenting with ectopic pregnancies have declining  $\beta$ HCG levels, and 70% of this group experience successful outcomes with close observation, as long as gestation is 4 cm or less in its greatest dimension but we do not believe that this approach should be used for interstitial pregnancies, which are prone to catastrophic rupture and massive intraperitoneal bleeding.<sup>6</sup> Positive cardiac activity, the size of gestation exceeding 3.5 cm,  $\beta$ HCG

levels higher than 5000 mIU/ml excluded the use of methotrexate in the treatment of the patient. We decided for the laparoscopic approach because we had a well skilled surgeon in laparoscopic technique who was capable to convert the operation quickly to laparotomy. He decided to do circular excision of the right horn of the uterus despite the possibility of greater blood loss. We thus additionally reduced the possibility to falling behind with gestational tissue inside the uterus and other organs after the procedure minimizing the risk of chronic interstitial pregnancy<sup>6</sup>. We did not previously apply vasopressin neither methotrexate because of their potentially harmful systematic effects. For example, women with certain medical conditions (e.g., liver disease with a transaminase level two times greater than normal, renal disease with a creatinine level greater than 1.5 mg per dL [133  $\mu$ mol per L], immune compromise with a white blood cell count less than 1,500 per  $\text{mm}^3$  [1.5  $3 \cdot 10^9$  per L] and platelets less than 100,000  $3 \cdot 10^3$  per  $\text{mm}^3$  [100  $3 \cdot 10^9$  per L], significant pulmonary disease) are not candidates for methotrexate.<sup>7</sup>

We thus wanted to show that the procedure can be done radically without the use of these drugs but with minimal blood loss and excellent prognosis after the procedure. The availability of blood products, immediate anesthesia, and critical care staff, surgical equipment and facilities are also essential for the safe practice of this minimally-invasive procedure. With these conditions and appropriate patient selection, laparoscopic treatment of interstitial pregnancy offers significant advantages over laparotomy, such as short hospital stay, faster return to normal activities, and decreased health care costs, without compromising treatment or patient safety.

### Conclusion

According to investigations, there is an increase in the frequency of interstitial pregnancy from 1.9 to 7.3% by the use of assisted reproductive techniques, so this potentially life-threatening condition should be managed safely in a timely fashion.<sup>8</sup> Minimally invasive laparoscopic excision should be the standard of care. The stepwise approach presented here; circular horn excision, achieves a rapid, systematic, safe and radical but definitive treatment of interstitial pregnancy that is minimally-invasive without the use of drugs (vasopressin and methotrexate), with minimal blood loss and a rapid return to normal activities. Careful patient selection and counseling regarding treatment options is essential, particularly for patients desiring future pregnancy. There has presently not been any report of pregnancy from the women from our case.

### References

1. Cunningham et al. *Williams Obstetrics* 24th edition; 2014. p. 377
2. Tay JJ, Moore J, Walker JJ. Ectopic pregnancy. *BMJ* 2000;320:916-9.
3. Tulandi T, Al-Jaroudi D. Interstitial pregnancy: results generated from the Society of Reproductive Surgeons Registry. *Obstet Gynecol.* 2004;103:47-50.
4. Rastogi R, GL Meena, Rastogi N, Rastogi V. Interstitial ectopic pregnancy: A rare and difficult clinicasonographic diagnosis. *J Hum Reprod Sci.* 2008;1:81-82.
5. Agryopolus Bachman E, Barnhart K. Medical management of ectopic pregnancy: a comparison of regiments. *Clin Obstet Gynecol.* 2012;55:440-447.
6. Jurkovic D, Wilkinson H. Diagnosis and management of ectopic pregnancy. *BMJ.* 2011;342:d3397
7. Barnhart K, Esposito M, Coutifaris C. An update on the medical treatment of ectopic pregnancy. *Obstet Gynecol Clin North Am.* 2000;27:653-67.
8. Manea C, Pavlidon E, Urias AA, Bouquet de la Joliniere J, Dubuisson JB, Feki A. Laparoscopic management of interstitial pregnancy and fertility outcomes after ipsilateral salpingectomy – three case reports, *Front Surg.* 2014;1:34.