

Fulminant necrotizing fasciitis with toxic shock syndrome and multiorgan failure caused by group A streptococcus (GAS): a case report

Arijana HORMAN-LEVENTA¹, MD, anesthesiologist
Ines ABDAGIĆ¹, MD, anesthesiologist
Lejla TAFRO¹, MD, MSc, anesthesiologist
Meliha HADŽOVIĆ-ČENGIĆ², MD, MSc, infectious disease specialist
Amela KATICA-MULALIĆ¹, MD, MSc, anesthesiologist

¹Clinic of Anaesthesiology and Intensive Care Medicine, Clinical University Centre, Sarajevo, BIH

²Clinic for Infective Diseases, Clinical University Centre, Sarajevo, BIH

Key words

necrotizing fasciitis
Streptococcus toxic shock syndrome
multiorgan failure
group A streptococcus (GAS)

Ključne riječi

nekrotizirajući fasciitis
streptokokni sindrom toksičnog šoka
višestruko zatajenje organa
streptokok grupe A (GAS)

Primljeno: 2018–02–07

Received: 2018–02–07

Prihvaćeno: 2018–05–10

Accepted: 2018–05–10

Case report

Necrotizing fasciitis (NF) commonly known as the "flesh eating disease" is a rare and threatening life disease which is often misdiagnosed on admission. Caused by group A streptococcus (GAS), NF can lead to streptococcal toxic shock syndrome with multiple organ failure and high mortality rate (30 % – 70 %) in spite of aggressive treatment. We present a case of a young woman who was admitted to hospital and primarily diagnosed as acute appendicitis on admission. After explorative laparotomy which showed no sign of acute abdominal illness, pale skin lesion proposing as cellulitis, on her right leg was noticed. In the next 6 hours she developed toxic shock with rapid progression of the soft tissue necrosis.

Fulminantni nekrotizirajući fasciitis sa sindromom toksičnog šoka i višestrukim zatajenjem organa uzrokovan streptokokom grupe A (GAS): prikaz slučaja

Prikaz slučaja

Nekrotizirajući fasciitis (NF) poznat kao "bolest koja jede meso" rijetka je i životno ugrožavajuća bolest koja se, pri prijemu u bolnicu, često pogrešno dijagnosticira. Nekrotizirajući fasciitis uzrokovan streptokokom grupe A (GAS) može, unatoč agresivnom liječenju, dovesti do streptokoknog sindroma toksičnog šoka s višestrukim zatajenjem organa visoke stope smrtnosti (30 % – 70 %). Opisujemo slučaj mlade žene koja je primljena u bolnicu i primarno dijagnosticirana kao akutna upala slijepog crijeva. Nakon laparotomije koja nije pokazala znakove akutne bolesti abdomena, primijećena je blijeda lezija kože desne noge te se posumnjalo na celulitis. U idućih 6 sati u bolesnice se razvio toksični šok s brzim napredovanjem nekroze mekog tkiva.

Background

Necrotizing fasciitis (NF) is a rare and life threatening infection of the skin and underlying structures. It is a progressive infection leading to soft tissue and muscular necrosis of the extremities, abdomen or perineum. NF is often very difficult to diagnose in the early stage of the disease. One of the most important clues is the pain that is often out of proportion to the injury itself [1]. It can often lead to shock with multiple organ failure with high mortality rate (30 %– 70 %) in spite of aggressive treatment [2].

Case report

A 47-year-old female patient with no co-morbidities was admitted to the Clinic for abdominal surgery for suspected appendicitis. Patient complained of severe right inguinal pain that spread to the right leg. Abdomen was tense, palpated in the area of the ileocecal region. There was a small pale skin lesion on the inside of the right thigh proposing as cellulitis. The initial laboratory findings revealed total white cell $13.5 \times 10^9/L$ with preserved hemoglobin and platelet and C-reactive protein (CRP) 192

mg/L. Her renal and hepatal functions were within reference range.

An indication for an exploratory laparotomy was made by the abdominal surgeon. The patient was preoperatively conscious, hemodynamically and respiratory stable. Intraoperatively no sign of acute appendicitis was found. Redness of the skin on the right thigh looking like cellulitis became more pronounced. The patient was postoperatively admitted to the Intensive Care Unit.

Postoperatively the patient continued to complain of severe pain in the right inguinal region spreading in the right leg up to the thumb of the right foot. She confirmed then that she did a pedicure a few days before. Over the course of a few hours the skin of the right leg was turning violet with the development of large fluid filled blisters (bullae) which is in favour of necrotizing fasciitis. The patient was empirically started with clindamycin (900 mg every 8 hours), metronidazole (500 mg every 8 hours) and ciprofloxacin (400 mg every 12 hours).

General condition of the patient was also deteriorating in terms of developing toxic shock syndrome. She was conscious complaining of severe pain in her right leg and after she became tachypneic, and hemodynamically unstable we decided to secure the airway before urgent CT scan was made (Figure 1.). Surgical debridement with incisions was carried out urgently after CT diagnostic procedure.

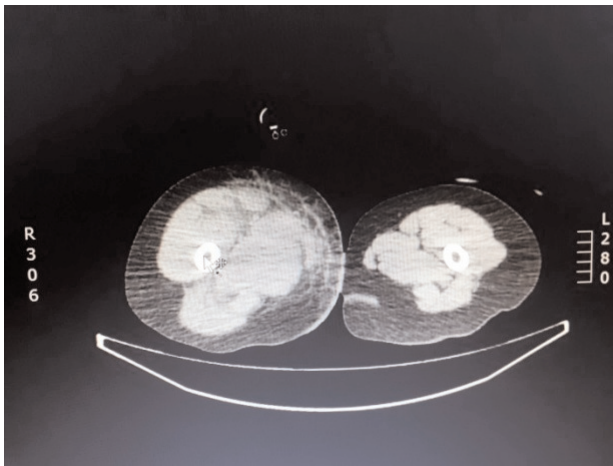


Figure 1. CT showing right leg subcutaneous emphysema, fat infiltration with intramuscular fluid collection

Slika 1. CT prikaz supkutanog emfizema desne noge, masne infiltracije s intramuskularnom kolekcijom tekućine

Control blood investigation revealed total white cell $4,8 \times 10^9/L$, Neu 69,6 %, Lym 0,521 %, Mono 21,5 %, Eos 0,539 %, Baso 0,049 %, red blood cell $2,85 \times 10^{12}/L$, hemoglobin 67 g/L, platelet $75,5 \times 10^9/L$, CRP 182 mg/L, INR 1,64, aPTT 60 s, Na 139 mmol/l, K 4,0 mmol/l, Cl 112 mmol/l, serum calcium 1,25 mmol/l, pH 7,11, pCO₂

7,25 KPa, p₂ 7,63 KPa, HCO₃ 17,1 mmol/L, EB -12,7 mmol/L, sO₂ 79,3 %, ALT 40 U/L, AST 158 U/L.

In the next 12 hours, the patient was sedated, on mechanical ventilation, hemodynamically unstable with SBP 70 – 80 mmHg requiring high doses of norepinephrine, epinephrine and dopamine support. SOFA score in the first 24 hours was 9 points. The protocol for septic shock treatment was applied, but despite the treatment, shock progressed. She became bradycardic and developed a cardiac arrest. Cardiopulmonary resuscitation (CPR) was immediately instituted according to advanced life support guidelines. Spontaneous circulation returned after 10 minutes. Local status was worsening. Group A Streptococcus was isolated from the right leg tissue culture. Both, *group A streptococcus* (GAS) and *Staphylococcus aureus* were isolated in the culture of the right thumb fingernail tissue. Blood cultures were negative. After receiving culture results we switched ciprofloxacin with vancomycin (1 g every 12 hours).

Two days after the admission, necrotizing fasciitis was spreading to perineum and abdominal wall (Figure 2). The patient was still on mechanical ventilation with analgo-sedation, FiO₂ 60 %, hemodynamically unstable requiring high doses of vasopressor and inotropic support. Urinary output per hour was 40 ml.

Controlled post-transfusion laboratory blood testing revealed total white cell $3,92 \times 10^9/L$, Neu 87,8 %, Lym 2,56 %, Mono 6,79 %, Eos 1,21 %, Baso 1,68 %, RBC $4,36 \times 10^{12}/L$, hemoglobin 115 g/L, platelet $109 \times 10^9/L$, CRP 218 mg/L, serum calcium 1,23 mmol/L, CK 11 756 U/L, CKMB 461 U/L, aPTT 60s, INR 1.64, lactates 6.9. Right leg incisions were widened by orthopedic surgeon.

Two days after the admission the decision to perform right hip exarticulation was made. Despite all measures taken the patient's condition continued to deteriorate and she developed multiple organ dysfunction syndrome

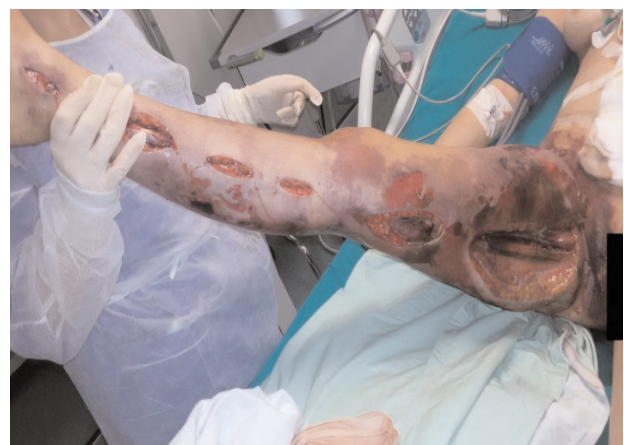

Figure 2. Right leg surgical incisions

Slika 2. Kirurške incizije desne noge

(MODS) with SOFA score 16 points. Three days after the admission to the ICU, the patient died.

Discussion

Necrotizing fasciitis (NF) is a rare infection of the soft tissue that has high mortality rate and is often unrecognised in its early stage. [3, 4]. Its clinical presentation includes progressive infection of the skin and soft tissues presenting with soft tissue oedema, erythema, skin necrosis and bullae. Making adequate diagnosis can be often very challenging due to paucity of skin findings early in the disease. Because NF first starts in the deep tissue planes epidermal involvement may be minimal at the beginning. This can make it difficult to differentiate from non-necrotizing skin infections and cellulitis. The diagnosis is often extremely difficult and relies on a high index of suspicion. A striking sign which is characteristic for NF is severe pain disproportionate to physical findings. [5] At the site of minor trauma (such as a bruise, strained muscle, or sprained ankle), patients may develop deep infection such as necrotizing fasciitis or myonecrosis within 24 to 72 hours, often with no visible break in the skin.

Necrotizing fasciitis type I is usually a polymicrobial infection involving mixed aerobic and anaerobic organisms. It is usually less severe, easier to diagnose and also it affects people with underlying disease. Type II infection is monomicrobial, usually caused by group A *Streptococcus* (GAS), and followed by *Staphylococcus aureus*. Unlike type I infections, type II is more aggressive, easily missed and may occur in previously healthy patients. Type III and Type IV infections are caused by marine-related organisms like *Vibrio* spp. and *Candida* spp. respectively [6]. Primary or idiopathic NF is principally a monomicrobial infection usually caused by group A streptococcus that most commonly occurs in the extremities [7].

Necrotizing fasciitis caused by GAS can lead to early onset of shock and organ failure defined as streptococcal toxic-shock syndrome (STSS) [8].

In our case the patient, with no underlying disease, was affected by GAS infection presenting at first as severe pain in the right inguinal region mimicking appendicitis. In the next 6 hours after explorative laparotomy she developed toxic shock with fulminant progression of skin and soft tissue necrosis spreading on her whole right leg. Reported pedicure days before could possibly be the cause of site infection. Mortality rate for patients who develop STSS can be higher than 50 % [9].

The treatment includes surgical debridement and early broad spectrum empiric antimicrobial therapy. The use of i.v. immunoglobulin is controversial [10, 11, 12] but recent studies show that they can be beneficial in case conventional therapy has failed. [13, 14]

Conclusion

Group A streptococcus infection can lead to necrotizing fasciitis and streptococcus toxic shock syndrome in previously healthy patients with poor outcome. The presence of severe pain, erythema and fever require high index of suspicion for this rare but potentially fatal infection.

References

- [1] Stevens DL, Bryant AE. Severe Group A Streptococcal Infections. In: Ferretti JJ, Stevens DL, Fischetti VA, eds. *Streptococcus pyogenes: Basic Biology to Clinical Manifestations*. Oklahoma City (OK); University of Oklahoma Health Sciences Center: 2016.
- [2] Stevens DL. Streptococcal toxic-shock syndrome: spectrum of disease, pathogenesis, and new concepts in treatment. *Emerg Infect Dis* 1995;1(3):69–78.
- [3] Wong CH, Chang HC, Pasupathy S, Khin LW, Tan JL, Low CO. Necrotizing fasciitis: clinical presentation, microbiology, and determinants of mortality. *J Bone Joint Surg Am* 2003;85-A(8):1454–60.
- [4] Schröpfer E, Rauthe S, Meyer T. Diagnosis and misdiagnosis of necrotizing soft tissue infections: three case reports. *Cases J* 2008; 1:252.
- [5] Headley AJ. Necrotizing soft tissue infections: a primary care review. *Am Fam Physician* 2003; 68(2):323–8.
- [6] Davoudian P, Flint NJ. Necrotizing fasciitis. *Contin Educ Anaesth Crit Care Pain* 2012;12(5):245–50
- [7] McHenry CR, Brandt CP, Piotrowski JJ, Jacobs DG, Malangoni MA. Idiopathic necrotizing fasciitis: recognition, incidence, and outcome of therapy. *Am Surg* 1994; 60(7): 490–94
- [8] Centers for Disease Control and Prevention. National Notifiable Diseases Surveillance System (NNDSS). Streptococcal toxic shock syndrome (STSS) (*Streptococcus pyogenes*): 2010 case definition. Dostupno na: <https://wwwn.cdc.gov/nndss/conditions/streptococcal-toxic-shock-syndrome/case-definition/2010/>
- [9] Lamagni TL, Darenberg J, Luca-Harari B, Siljander T, Efstratiou A, Henriques-Normark B, et al. Epidemiology of severe *Streptococcus pyogenes* disease in Europe. *J Clin Microbiol* 2008;46(7): 2359–67
- [10] Shah SS, Hall M, Srivastava R, Subramony A, Levin JE. Intravenous Immune Globulin in Children with Streptococcal Toxic Shock Syndrome. *Clin Infect Dis* 2009;49(9):1369–76.
- [11] Soares MO, Welton NJ, Harrison DA, Peura P, Shankar-Hari M, Harvey SE, et al. Intravenous immunoglobulin for severe sepsis and septic shock: clinical effectiveness, cost-effectiveness and value of a further randomised controlled trial. *Critical Care* 2014; 18(6):649.
- [12] Alejandria MM, Lansang MA, Dans LF, Mantaring JB 3rd. Intravenous immunoglobulin for treating sepsis, severe sepsis and septic shock. *Cochrane Database Syst Rev* 2013 Sep 16;(9):CD001090
- [13] Norrby-Teglund A, Muller MP, McGeer A, Gan BS, Guru V, Bohnen J, et al. Successful management of severe group A streptococcal soft tissue infections using an aggressive medical regimen including intravenous polyspecific immunoglobulin together with a conservative surgical approach. *Scand J Infect Dis* 2005;37(3):166–72.
- [14] Raithatha AH, Bryden DC. Use of intravenous immunoglobulin therapy in the treatment of septic shock, in particular severe invasive group A streptococcal disease. *Indian J Crit Care Med* 2012; 16(1):37–40.