

Unusual Manifestations of Secondary Syphilis: Case Presentations

Dear Editor,

Syphilis is an infection caused by *Treponema pallidum*. Without treatment, it goes through the following stages: primary, secondary, latent, and tertiary (1). The clinical picture of secondary syphilis is very variable (2,3). We present two rare cases of secondary syphilis, one with nodular lesions initially considered to be lymphoma and second with periostitis, which was initially interpreted as an osteoma. To date, only 15 cases with nodular lesions and 10 cases with periostitis in secondary syphilis have been reported in the literature.

The first patient was a 59 year old man who presented in a private practice with nodular lesions on the face and axillary and inguinal folds (Figure 1, a, b). The initial diagnostic consideration was lymphoma. A biopsy specimen was taken, and the histopathological features revealed epidermal hyperplasia with papillomatosis, minimal spongiosis with many neutrophils and with a marked inflammatory infiltrate

in dermis, consisting of lymphocytes, plasma cells, and neutrophils; the diagnosis of interfaced dermatitis was established (Figure 1, d, e). After one month, the patient presented to our clinic with numerous nodular lesions, some of them painful, located on the trunk and intertriginous folds, including the intergluteal cleft – the lesions in this area being suggestive of condylomata lata (Figure 1, c). The diagnosis of secondary syphilis was taken into consideration, and screening serum tests were performed and found reactive: a Venereal Diseases Research Laboratory (VDRL) titer of 1:64 and *Treponema pallidum* Hemagglutination Assay (TPHA) titer of 1:80. Hepatitis and anti-human immunodeficiency virus (HIV) antibodies serology was negative. The biopsy was repeated and showed the same histopathological changes. In addition, Warthin-Starry staining was performed, revealing the presence of some spiral micro-organisms in the dermis corresponding to *Treponema pallidum* (Figure 1, f).

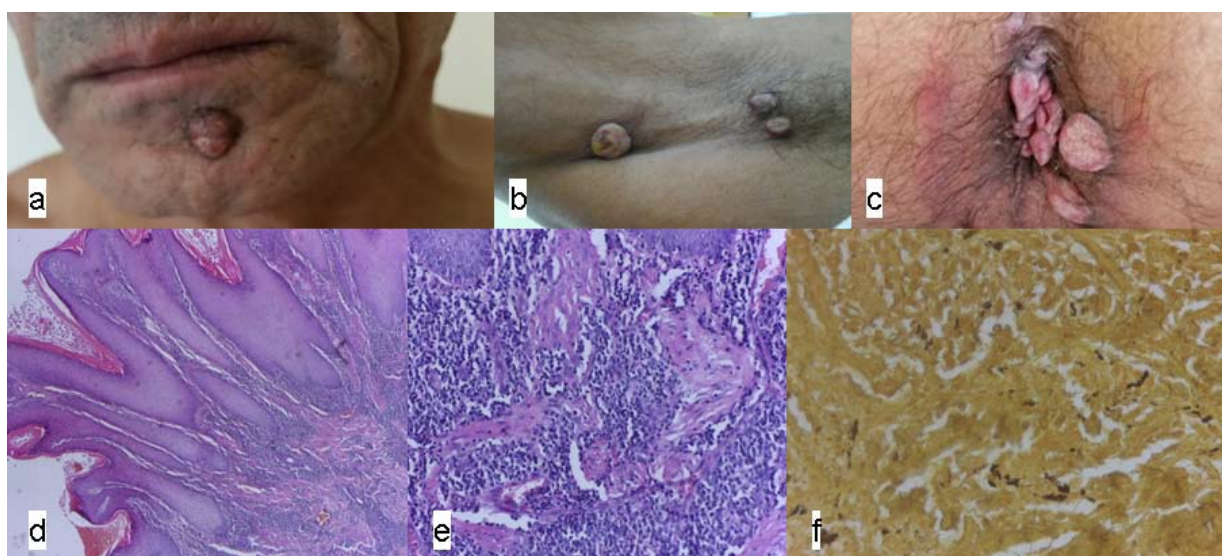


Figure 1. Case 1; clinical manifestations: nodular lesion on the face (a); nodular lesions in the axillary fold (b); condylomata lata (c); histopathology (hematoxylin and eosin (HE) ×20): epidermal hyperplasia with papillomatosis; (d) HE ×40: inflammatory infiltrate in the dermis consisting of lymphocytes, plasma cells, and neutrophils; (e) HE ×40: Warthin-Starry staining: the presence of *Treponema pallidum*; (f)

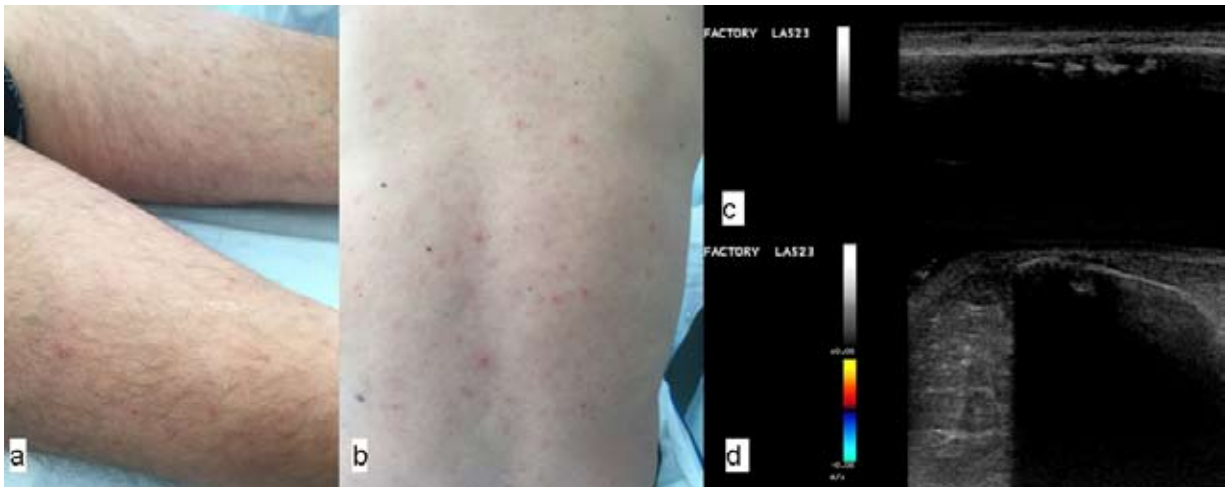

Figure 2. Case 2; clinical manifestations: erythematous maculo-papular rash on the limbs (a) and trunk (b); the ultrasound examination: thickening of the compact tibial bone associated with subperiosteal destructive and proliferative changes (c); (d)

A diagnosis of secondary syphilis was established, and the patient was treated with benzathine penicillin G 2.4 million units by intramuscular injection once a week for 2 consecutive weeks. The skin lesions regressed within 1 month, and serological tests showed a VDRL titer of 1:8 3 months after treatment.

The second patient was a homosexual male, 35 years old, diagnosed with HIV infection, stage B2. He presented with bone pain in the calves and forearms, with insidious onset. He also presented with an associated erythematous maculo-papular rash on the trunk and limbs and generalized lymphadenopathy (Figure 2, a, b). The tibial crest and radius were sensitive to palpation. A right leg radiography was performed, raising suspicion of osteoid osteoma. The CT scan excluded the diagnosis of osteoma; taking into account the epidemiological context, the diagnosis of syphilis was suspected. The diagnosis was confirmed by leg ultrasound examination (2D US) which showed thickening of the compact tibial bone associated with subperiosteal destructive and proliferative changes (Figure 2, c, d) and by serology for syphilis: the VDRL titer was 1:32 and the TPHA titer was 1:80. The patient was treated with benzathine penicillin 2.4 million units, once a week, for 2 consecutive weeks, with clinical improvement.

Syphilis continues to be a serious public health problem worldwide, even if it is a controllable disease due to diagnostic tests and effective and accessible treatment.

According to the World Health Organization in 2008, the estimated number of new cases of sexually transmitted diseases in adults with syphilis is 10.6 million cases (4).

The cases presented in this paper were characterized by unusual manifestations, requiring good collaboration between the dermatologist and other specialties.

In the first case, the diagnosis of secondary syphilis was confirmed by positive serological, clinical, and histopathological findings. The main differential diagnosis of nodular syphilis includes lymphoma, sarcoidosis, Kaposi's sarcoma, atypical mycobacteriosis, deep fungal infections, leprosy, tuberculosis, leishmaniasis, and lymphomatoid papulosis (5). Another important differential diagnosis is between secondary and tertiary syphilis, especially when ulcerating nodules are present. Tertiary syphilis is characterized by unilateral, deep ulcerating nodules with necrotizing granulomas (6).

Bone involvement during syphilis is mainly represented by polyarthritides, synovitis, osteitis, and periostitis (7,8). Syphilitic periostitis is characterized by localized or diffuse pain, particularly during the night, which is relieved by movement. The skull, the shoulder girdle, and the long bones are the most common sites of involvement (9).

In conclusion, we presented two different cases of secondary syphilis that contribute to the clinical experience of rare cases presented in the literature, raising the awareness of dermatologists and other specialists about less specific clinical aspects of syphilis.

References:

1. Zeltser R, Kurban AK. Syphilis. *Clin Dermatol.* 2004;22:461-8.
2. Baughn RE, Musher DM. Secondary Syphilitic Lesions. *Clin Microbiol Rev.* 2005;18:205-16.

3. Sakthivel P, Kakkar A, Sharma SC, Panda S. Mucocutaneous Secondary Syphilis: "The Great Imitator". *Am J Med.* 2018;131(2):e57-e58.
4. European Centre for Disease Prevention and Control (ECDC). Sexually transmitted infections in Europe. 1990-2010. Stockholm: ECDC, 2012.
5. Breznik V, Potocnik M, Miljkovic J. Papulonodular secondary syphilis in a 52-year-old non HIV heterosexual patient. *Acta Dermatoven APA.* 2010;19: 27-30.
6. Little JW. Syphilis: An update. *Oral Surg, Oral Med, Oral Pathol.* 2005;100:3-9.
7. Samarkos M, Giannopoulou C, Karantoni E, Papastamopoulos V, Baraboutis I, Skoutelis A. Syphilitic periostitis of the skull and ribs in a HIV positive patient. *Sex Transm Infect.* 2011;87:44-5.
8. Park KH, Lee MS, Hong IK, Sung JY, Choi SH, Park SO, *et al.* Bone involvement in secondary syphilis: a case report and systematic review of the literature. *Sex Transm Dis.* 2014;41:532-7.
9. McPhee SJ. Secondary syphilis: uncommon manifestations of a common disease. *West J Med.* 1984;140:35-42.

Sorina Ana Dănescu¹, Blanca Szolga², Carmen Georgiu¹, Alina Surcel³, Simona Corina Șenilă¹

¹University of Medicine and Pharmacy "Iuliu Hatieganu", Cluj-Napoca, Romania; ²The Clinical Hospital of Infectious Diseases Cluj-Napoca, Ambulatory Department, Romania; ³"Regina Maria" Hospital, Cluj-Napoca, Romania

Ethics approval and consent to participate

The study was approved by the local Ethic Committee of the University of Medicine and Pharmacy "Iuliu Hatieganu", Cluj-Napoca, Romania and performed in accordance with the Declaration of Helsinki.

Funding

This work was supported by internal grant 4945/6/08.03.2016 (SD) from "Iuliu Hatieganu" University of Medicine and Pharmacy.

Corresponding author:

Sorina Ana Dănescu, MD
University of Medicine and Pharmacy
"Iuliu Hatieganu"
Victor Babes 8 street, Cluj-Napoca
Cluj
Romania
sorinadanescu@yahoo.com

Received: July 26, 2017

Accepted: May 15, 2018